

CHAPTER IV

RESULTS



The knee joint structures

Part I

Distal femoral condyle

The mean resected AP length and ML width of all subjects were 45.43 mm and 64.06 mm, respectively. The mean resected AP length and ML width of males were 48.53 mm and 70.15 mm, respectively. The mean resected AP length and ML width of females were 43.32 mm and 59.91 mm, respectively (Table.2). The distal femoral condyle size of the female was smaller than that of the male. The differences in the resected AP length and ML width between the male and female were significant ($p < 0.0001$) (Fig.16). The average resected AP length/ML width ratio was 0.61 for all subjects, 0.69 for the male and 0.72 for the female ($p < 0.001$) (Table.2) (Fig.17).

Table2.

The distal femoral condyle dimensions

Sex	Resected AP length (mm.)	ML width (mm)	Ratio <u>Resected AP length</u> / ML width
Total	45.43 ± 4.5 (35-56.9)	64.06 ± 6.31 (52-78.9)	0.61±0.05 (0.49-0.74)
Male	48.53 ± 3.77 (40-56.9)	70.15 ± 3.55 (61.40-78.9)	0.69±0.05 (0.56-0.81)
Female	43.32 ± 3.69 (35-55)	59.91 ± 3.75 (52-76.30)	0.72±0.06 (0.57-0.9)

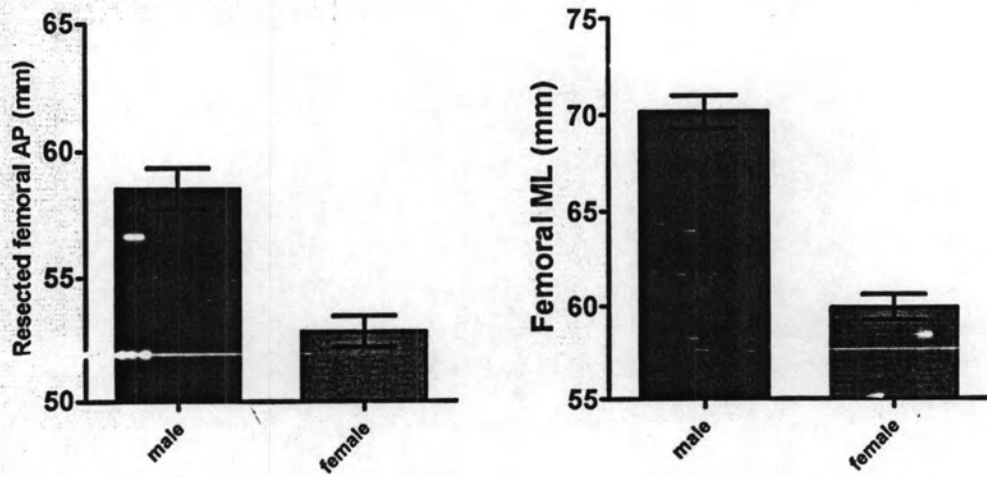


Fig.16 Graphs demonstrating comparison of resected femoral AP and ML between males and females

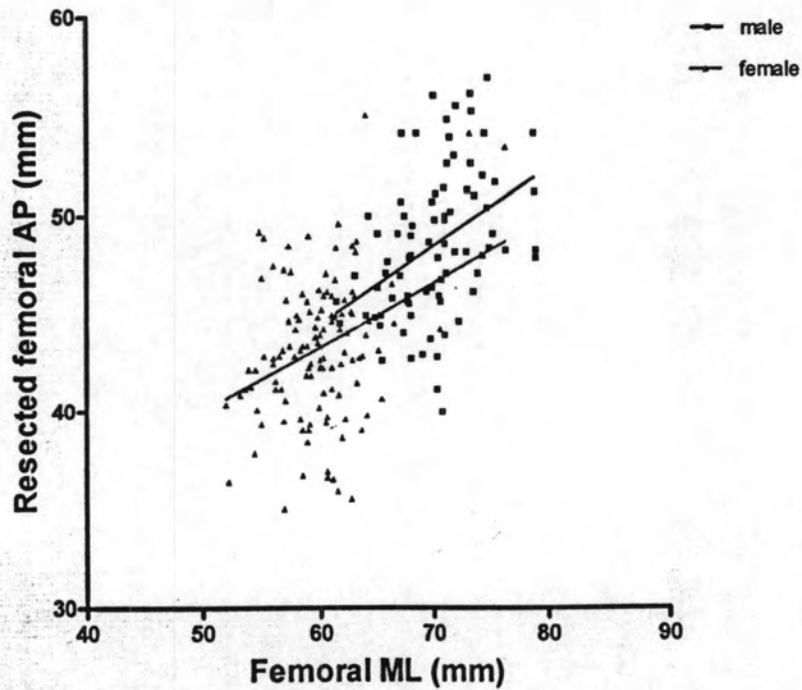


Fig.17 Graph demonstrating comparison of resected femoral dimensions between males and females

Part II

Proximal tibia

The mean AP length and ML width of all subjects were 46.04 mm and 68.7 mm, respectively. The mean AP length and ML width of the male were 49.49 mm and 73.6 mm, respectively. The mean AP length and ML width of the female were 43.23 mm and 64.95 mm, respectively (Table.3). The proximal tibia size of the female was smaller than that of the male. The differences in the AP length and ML width between the male and the female were significant ($p < 0.0001$) (Fig.18& 19).

Table3.
The proximal tibia dimensions

Sex	AP length (mm)	ML width (mm)	Ratio <u>AP length</u> ML width
Total	46.04 ± 4.4 (37.6-56.6)	68.7 ± 5.79 (57.8-86)	0.67 ± 0.03 (0.59-0.77)
Male	49.49 ± 2.38 (44-56.6)	73.6 ± 3.19 (65.6-86)	0.67 + 0.03 (0.61-0.75)
Female	43.23 ± 2.57 (37.6-52)	64.95 + 3.45 (57.8-78.6)	0.67 + 0.03 (0.59-0.77)

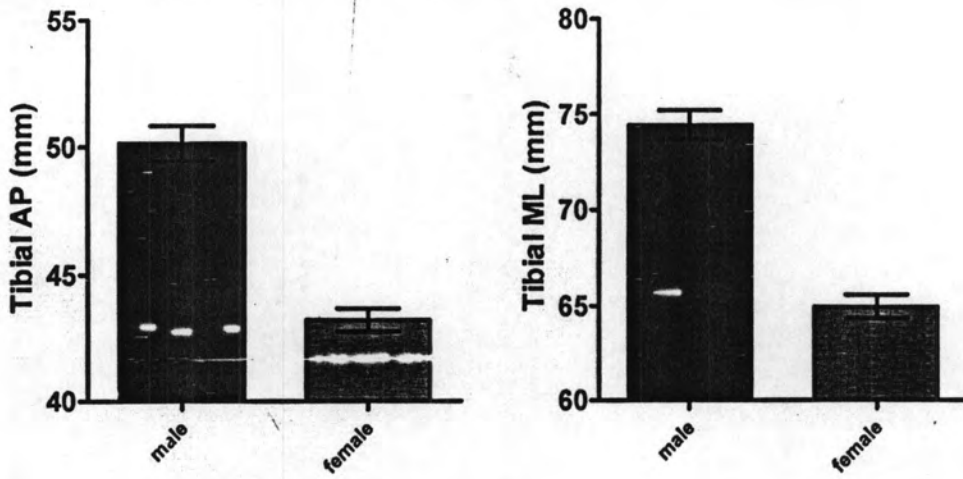


Fig.18 Graphs demonstrating comparison of tibial AP and ML between males and females

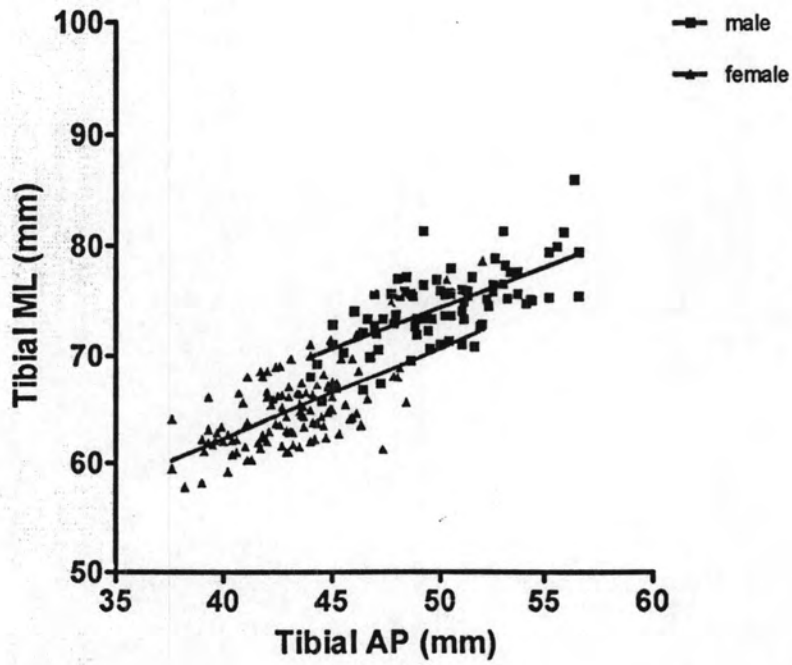


Fig.19 Graph demonstrating comparison of resected tibial dimensions between males and females

Part III

Patellar

The mean patellar thickness, SI length and ML width of all subjects were 18.95 mm, 35 mm and 40.63 mm, respectively. The mean patellar thickness, SI length and ML width of the male were 20.42 mm, 36.43 mm and 43.02 mm, respectively. The mean patellar thickness, SI length and ML width of the female were 17.7 mm, 32.97 mm and 38.64 mm, respectively (Table.4). The patellar size of the female was smaller than that of the male. The differences in the thickness, SI length and ML width between the male and the female were significant ($p < 0.0001$) (Fig.20& 21).

Table4.

The patellar dimensions

Sex	Thickness (mm.)	SI length (mm.)	ML width (mm.)
Total	18.95 ± 2.84 (14.4-40.3)	35 ± 4.42 (26-51.6)	40.63 ± 4.39 (18.3-49.8)
Male	20.42 ± 3.18 (16.2-40.3)	36.43 ± 3.53 (30.5-51.6)	43.02 ± 4.67 (18.3-49.8)
Female	17.7 ± 1.67 (14.4-21.2)	32.97 ± 2.91 (26-42)	38.64 ± 2.99 (30.6-47.8)

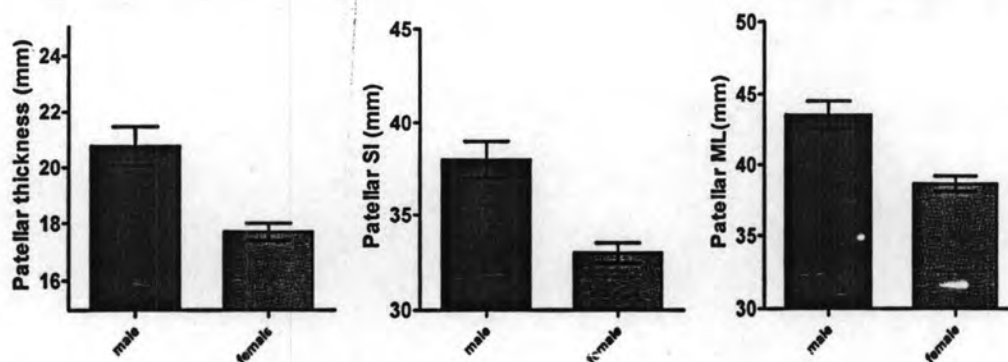


Fig.20 Graph demonstrating comparison of patellar SI, ML and thickness between males and females

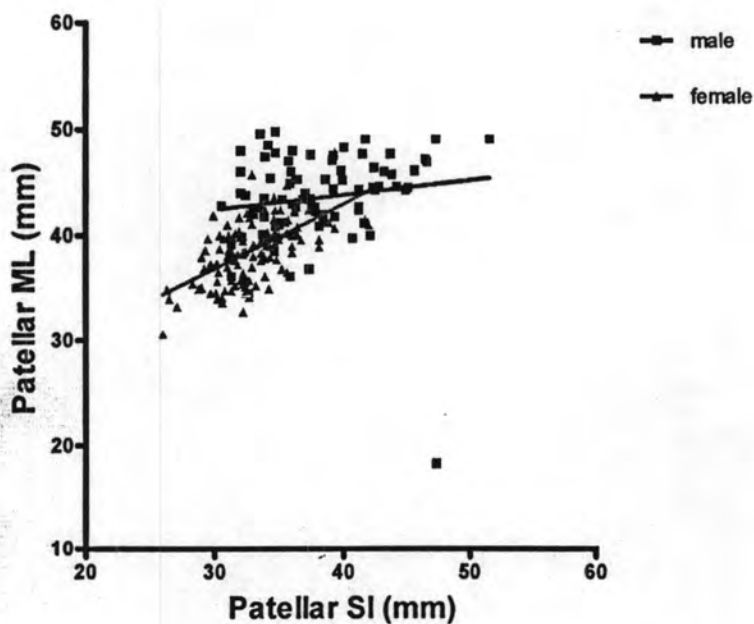


Fig.21 Graph demonstrating comparison of patellar dimensions between males and females

There were no differences between each group, in terms of age and side of bone in this study. These aspects ratios were compared with four knee prosthetic systems: NexGen Legacy Posterior Stabilized (LPS) (Zimmer, Warsaw, Indiana); P.F.C. Sigma (Depuy-Johnson and Johnson, Warsaw, Indiana); Genesis II (Smith&nephew); and Scopio[™] (Stryker).

The knee prostheses

I. NexGen Legacy Posterior Stabilized (LPS)

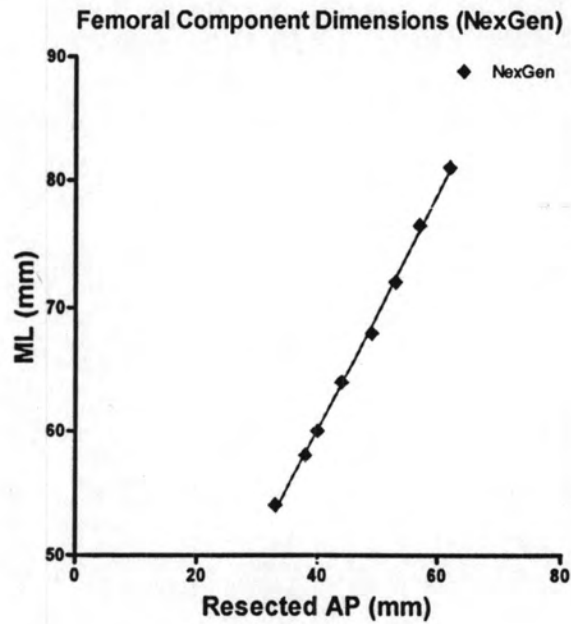


Fig.22 Graph demonstrating ratio ML width versus resected AP length of femoral component (NexGen)

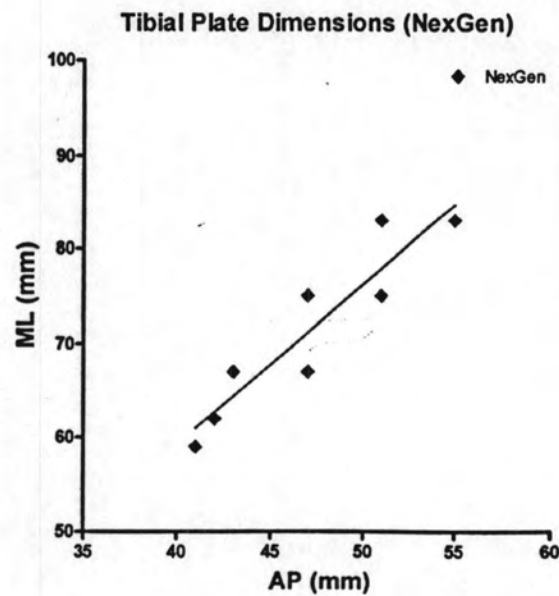


Fig.23 Graph demonstrating ratio ML width versus AP length of tibial component (NexGen)

II. P.F.C. Sigma (Depuy-Johnson and Johnson, Warsaw, Indiana)

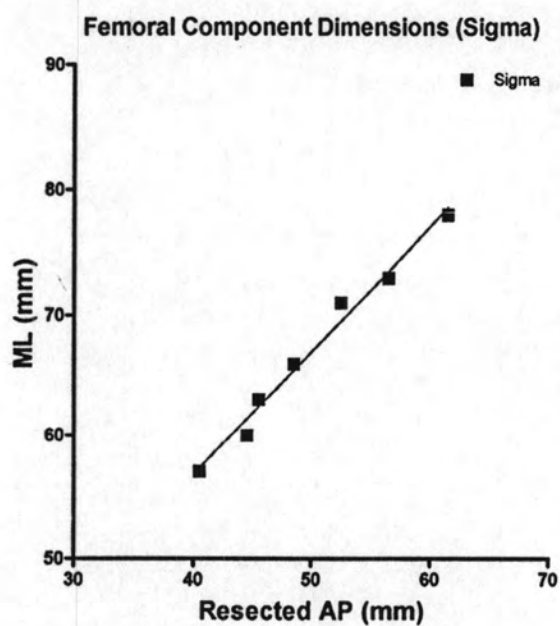


Fig.24 Graph demonstrating ratio ML width versus resected AP length of femoral component (Sigma)

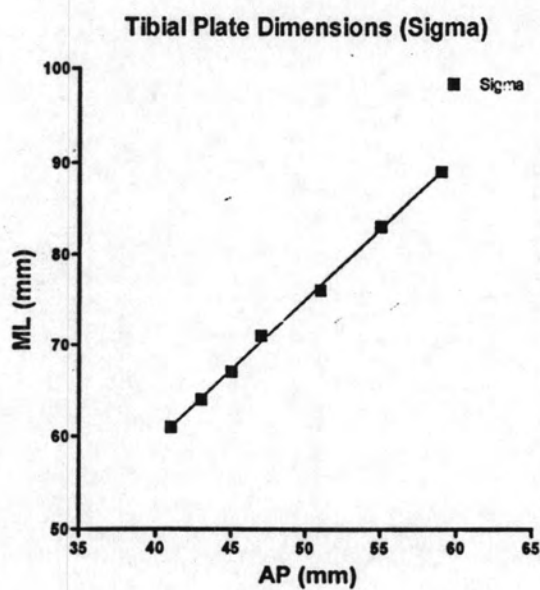


Fig.25 Graph demonstrating ratio ML width versus AP length of tibial component (Sigma)

III. Genesis II (Smith&nephew)

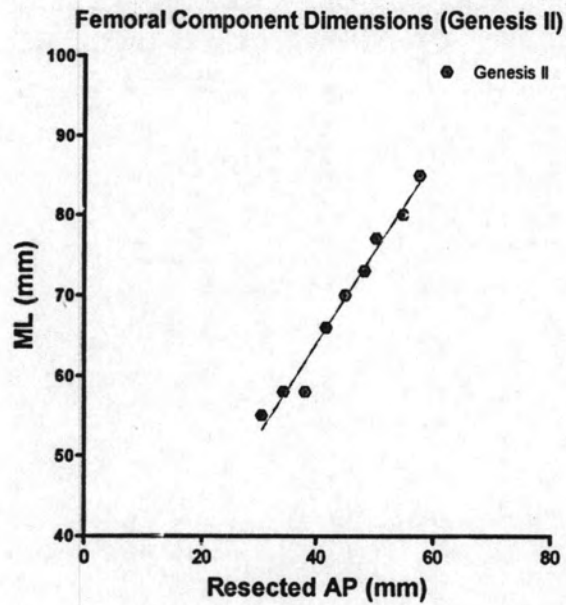


Fig.26 Graph demonstrating ratio ML width versus resected AP length of femoral component (Genesis II)

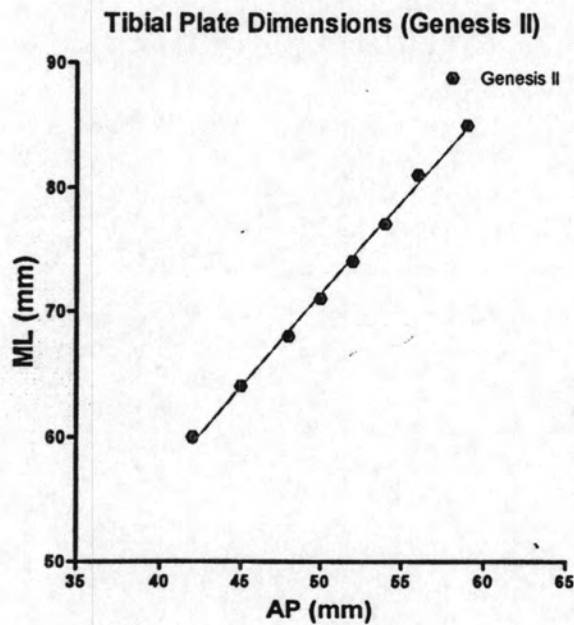


Fig.27 Graph demonstrating ratio ML width versus AP length of tibial component (Genesis II)

IV. Scorpio™ (Stryker)

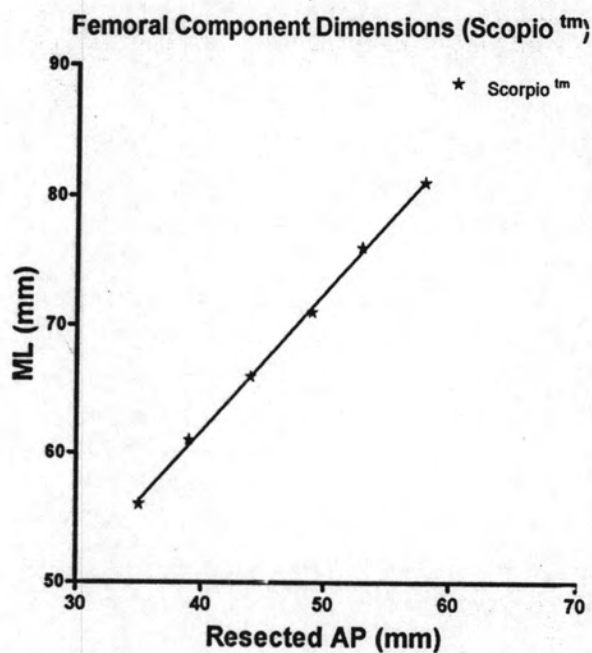


Fig.28 Graph demonstrating ratio ML width versus resected AP length of femoral component (Scorpio™)

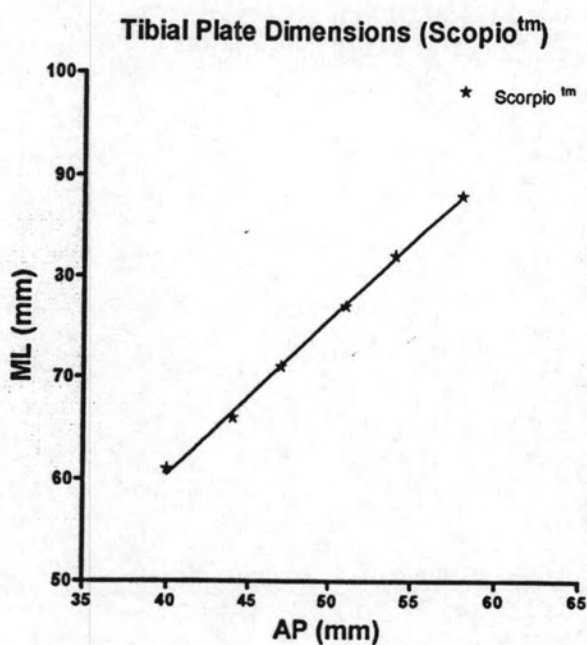


Fig.29 Graph demonstrating ratio ML width versus AP length of tibial component (Scorpio™)

The aspect ratios comparison among prostheses

We found that all prosthetic components had only one AP length for one ML width both femoral and tibial components

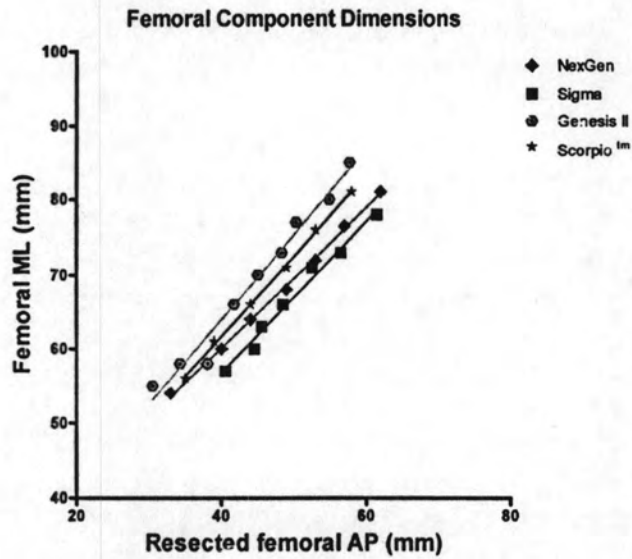


Fig.30 Graph demonstrating comparison femoral component among four prostheses.

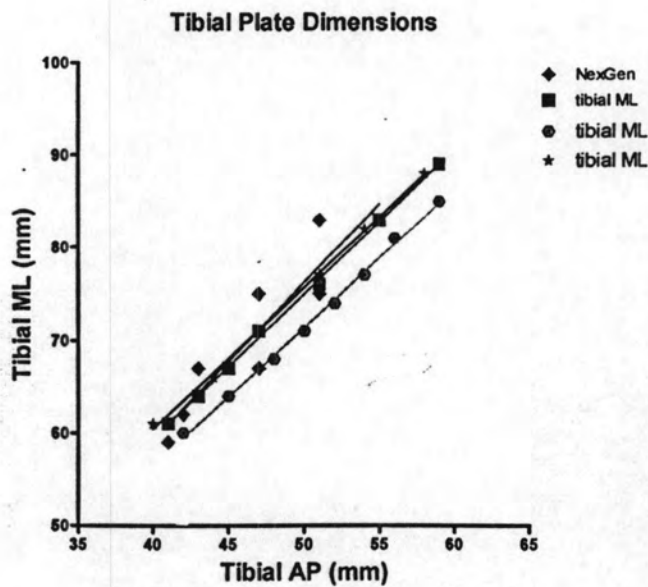


Fig.31 Graph demonstrating comparison tibial component among four prostheses.

Comparison of the ratio femoral ML versus resected femoral AP between the resected femoral condyle in males and prostheses

This study shows that the range of the resected femoral AP length was 40 – 56.9 mm and that of the femoral ML width was 61.4 – 78.9 mm in Thai males. This finding is the size distribution of the Scorpio[™] systems which is closer to that of the femoral dimensions of the Thai males. The NexGen and Sigma systems tend to undersize the femoral ML width at a given implant resected femoral AP length. On the contrary, the Genesis system tends to overhang the femoral ML width at a given implant resected femoral AP length (Fig.32).

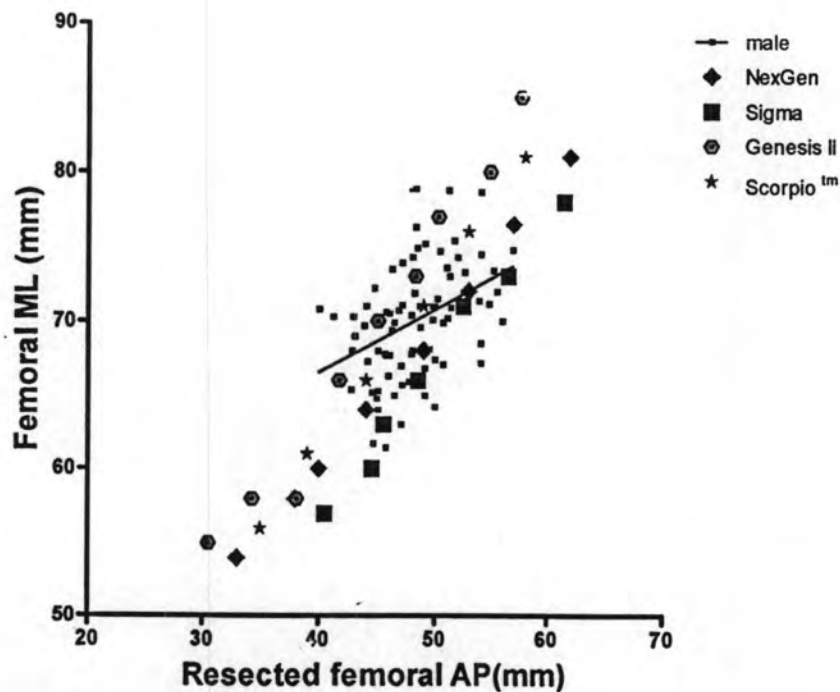


Fig.32 Graph demonstrating comparison of resected femoral AP and ML for knees in males and prostheses

Comparison of the ratio femoral ML versus resected femoral AP between the resected femoral condyle in females and prostheses

This study shows that the range of the resected femoral AP length was 35 - 55 mm and that of the femoral ML width was 52 - 76.3 mm in the Thai females. This finding is the size distributions of the NexGen and Sigma systems which are closer to that of femoral dimensions than the Genesis II and Scorpio™ systems but they show slightly overhanging of the femoral ML width at a given implant resected femoral AP length. The more overhung the femoral ML width, the larger the size of the resected femoral AP appeared (Fig.33).

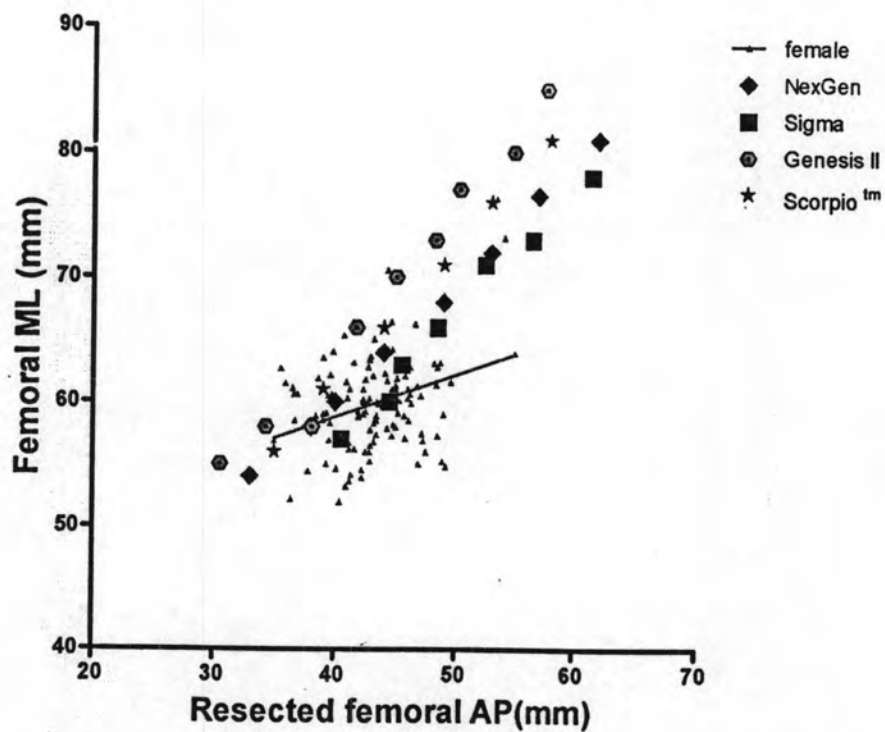


Fig.33 Graph demonstrating comparison of resected femoral AP and ML for knees in females and prostheses

Comparison of the ratio tibial ML versus tibial AP between the proximal tibia in males and prostheses

This study shows that the range of the tibial AP length was 44 – 56.6 mm and that of the tibial ML width was 65.6 - 86 mm in the Thai males. The size distributions of the Sigma and the Scorpio[™] systems are closer to that of the tibial dimensions than the NexGen and the Genesis II systems. The NexGen system seems to be overhanging the tibial ML width at a given implant tibial AP length. Also it was found that the Genesis II seems to be undersized the tibial ML width at a given implant tibial AP length (Fig.34).

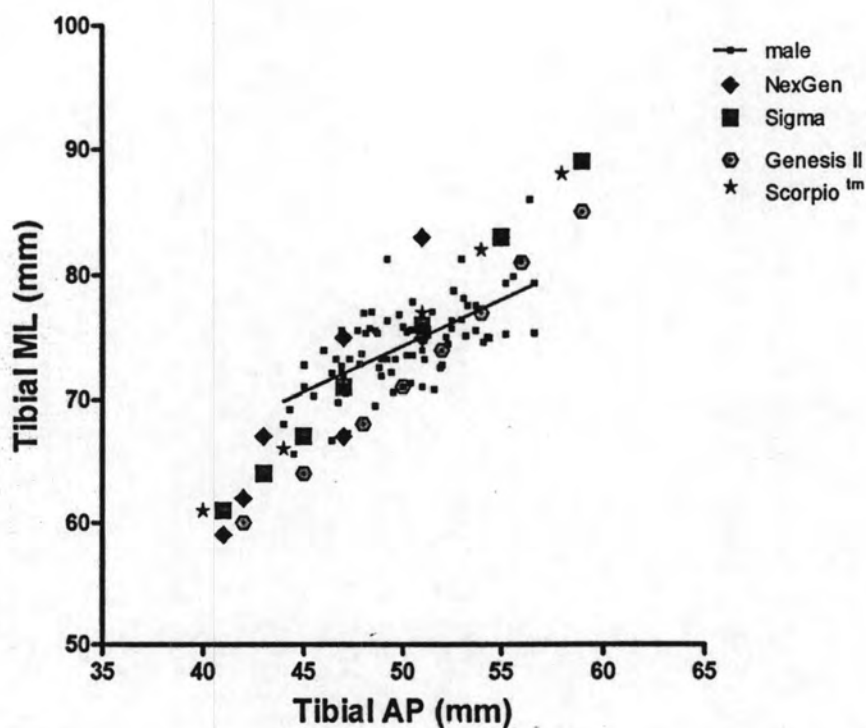


Fig.34 Graph demonstrating comparison of resected tibial AP and ML for knees in males and prostheses

Comparison of the ratio tibial ML versus tibial AP between the proximal tibia in females and prostheses

This study shows that the range of the tibial AP length was 37.6 - 52 mm and that of the tibial ML width was 57.8 - 78.6 mm in Thai males. The size distributions of the Sigma and the Scorpio[™] systems are closer to that of tibial dimensions than the NexGen and the Genesis II systems. The NexGen system seems to overhang the tibial ML width at a given implant tibial AP length. Also, we found that the Genesis II seems to be undersized the tibial ML width at a given implant tibial AP length (Fig.35).

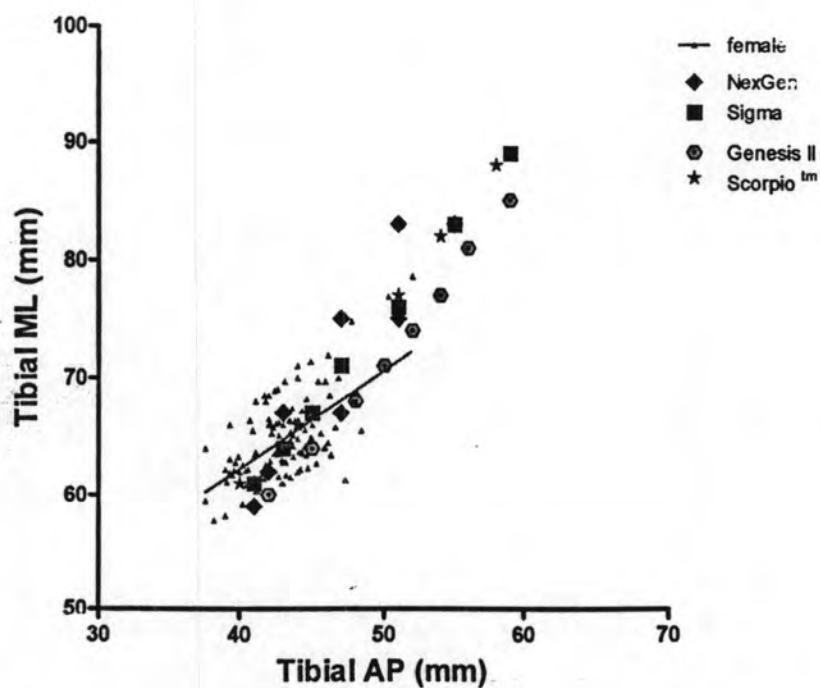


Fig.35 Graph demonstrating comparison of resected tibial AP and ML for knees in females and prostheses