

## **Bridging Bronchus : Observation of abnormal course of right lower lobe bronchus from chest radiograph and 3D reformation helical CT image**

Panruethai Trinavarat\*

Atchara Mahayosnond\*

**Trinavarat P, Mahayosnond A. Bridging Bronchus : Observation of abnormal course of right lower lobe bronchus from chest radiograph and 3D reformation helical CT image. Chula Med J 2002 Jul; 46(7): 563 - 70**

*"Bridging bronchus" is a rare bronchial anomaly which is difficult to diagnose from plain chest radiographs. We report bridging bronchus in two infants whose chest radiographs gave substantial clues to establish the diagnosis. The radiographic findings were repetitive atelectasis of the left lung and right lower lobe, and less vertical course of the right lower lobe bronchus more parallel rather than converging to the right main bronchus. The atelectatic right lower lobe facilitated a visualization of the abnormal course of the right lower lobe bronchus. The diagnosis was confirmed by 3-D reformation from helical CT in one patient, and by tracheobronchogram in the other.*

**Key word :** *Bridging bronchus.*

Reprint request : Trinavarat P, Department of Radiology, Faculty of Medicine, Chulalongkorn University, Bangkok 10330, Thailand.

Received for publication. March 12, 2002.

ปานฤทัย ตรีนวรัตน์, อัจฉรา มหายศนันท์. Bridging Bronchus: ความผิดปกติของแนวทางเดินหลอดลมที่ตรวจพบจากภาพรังสีปอดและการสร้างภาพสามมิติด้วยเอกซเรย์คอมพิวเตอร์ชนิด spiral. จุฬาลงกรณ์เวชสาร 2545 ก.ค; 46(7): 563 – 70

“Bridging bronchus” เป็นความผิดปกติของ bronchus ที่พบได้น้อยและวินิจฉัยได้ยากจาก plain chest radiographs คณะผู้รายงานได้รายงานผู้ป่วยทารก 2 ราย ที่มี bridging bronchus และความผิดปกติที่พบจาก plain chest radiographs ช่วยในการวินิจฉัยโรค คือ พบปอดซ้ายและปอดกลีบขวาล่างแฟบ และการที่ปอดกลีบขวาล่างแฟบทำให้สามารถเห็นความผิดปกติของแนวท่อหลอดลมของปอดกลีบขวาล่างได้ชัดเจนขึ้นว่ามีความชันน้อยกว่าปกติ ทำให้สงสัยภาวะดังกล่าวแม้ว่าจะไม่เห็นตำแหน่งที่ท่อหลอดลมของปอดกลีบขวาล่างออกมาจากหลอดลมใหญ่ด้านซ้าย ความผิดปกติดังกล่าวได้รับการยืนยันด้วยภาพสามมิติจากการตรวจด้วยเอกซเรย์คอมพิวเตอร์ชนิด spiral ในผู้ป่วยรายหนึ่ง และจาก tracheobronchography ในผู้ป่วยอีกรายหนึ่ง

สถาบันวิทยบริการ  
จุฬาลงกรณ์มหาวิทยาลัย

Bridging bronchus is a rare displaced bronchus,<sup>(1)</sup> arising from the left main bronchus and coursing through the mediastinum to supply right lower lobe<sup>(2)</sup> or the entire right lung.<sup>(3)</sup> It is associated with a long segment of tracheobronchial stenosis due to the absence of pars membranaceum,<sup>(4)</sup> causing upper airway obstruction. Most of the reported cases had sling left pulmonary artery. Other associated anomalies were imperforate anus, congenital heart disease and abnormal segmentation of the vertebrae.

Because of very narrowing lumen, bridging bronchus causes respiratory distress in almost all cases. Information of bronchial anomaly, degree and length of the narrowing segment from imaging studies are needed for surgical planning whether tracheobronchial resection and re-anastomosis could be performed. Detection of bridging bronchus in patients with sling left pulmonary artery is very important. Surgery of the pulmonary artery usually yields satisfactory outcomes in patients with sling left pulmonary artery alone but not in the cases associated with bridging bronchus.

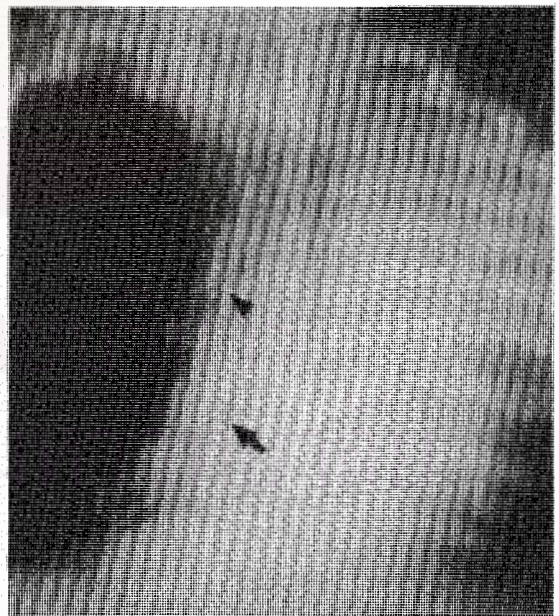
Bridging bronchus was difficult to be diagnosed from plain chest radiographs without high kV filtered and magnified technique.<sup>(5,6)</sup> In earlier literatures, the diagnosis was usually made at autopsy. Bronchography had been the gold standard. We reported two infants who had bridging bronchus and their chest radiographs revealed some diagnostic clues.

### Case report


#### Case 1

A 1900 grams male neonate, born from normal delivery of 34-week gestation at another hospital.

He had transient tachypnea in the newborn without need of intubation. Persistent opening of foramen ovale and noisy breathing were detected when he was 3 months old. On the 4<sup>th</sup> month he was referred to King Chulalongkorn Memorial Hospital because of pneumonia with respiratory failure. He had problem of secretion obstruction, atelectasis and could not be extubated. Rhonchi at both lungs and wheezing in left lower lobe were heard. His chest radiographic series showed poorly outlined lower trachea and left main bronchus, repetitive atelectasis of the right lower lobe, left upper lobe and left lower lobe, and occasional hyperinflation of right upper lobe (Figure 1). The course of right lower lobe bronchus was rather parallel than converging to the right main bronchus. Bronchoscopy revealed narrowing of the left main

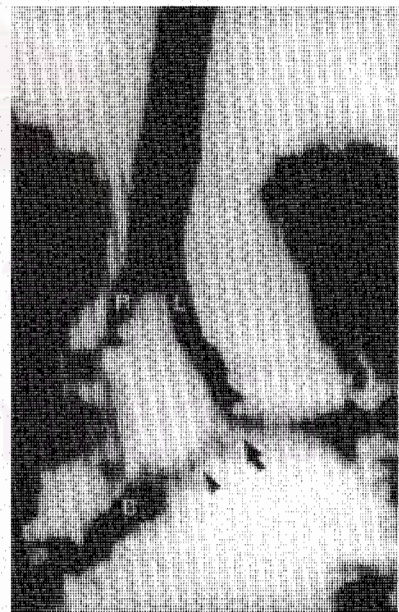
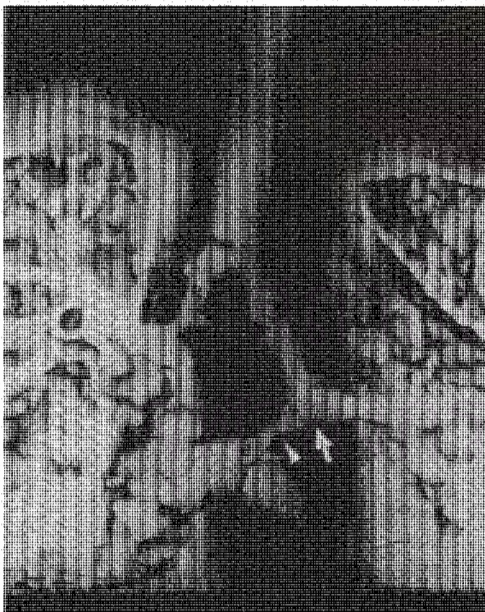
**Figure 1.** Case 1: Atelectasis of the right lower lobe and the left lung was noted. The course of right lower lobe bronchus (arrow) was more parallel to that of right main bronchus (arrowhead) rather than converging to it.



**Figure 2.** Case 1: Lateral view of barium swallowing showed indentation on anterior wall of the esophagus (arrow) by sling left pulmonary artery.

bronchus, bronchomalacia of the right main bronchus and mentioned abnormally small sizes of the right upper lobe and intermediate bronchi. Barium swallowing suggested sling left pulmonary artery (Figure 2). Spiral CT under chloral hydrate sedation and spontaneous respiration was performed with 3D reformation (Figure 3a,b). It showed a long narrowing segment of the left main bronchus and anomalous origin of the right lower lobe bronchus arising from the left main bronchus at T6 level with inverted-T appearance of the pseudocarina. The right bronchial angle was 69 degrees and the left bronchial angle was 61 degrees. The diagnoses were bridging bronchus and sling left pulmonary artery. He was treated conservatively. His second admission was at 6 months old from recurrent pneumonia. He was intubated and, he was discharged a week later without



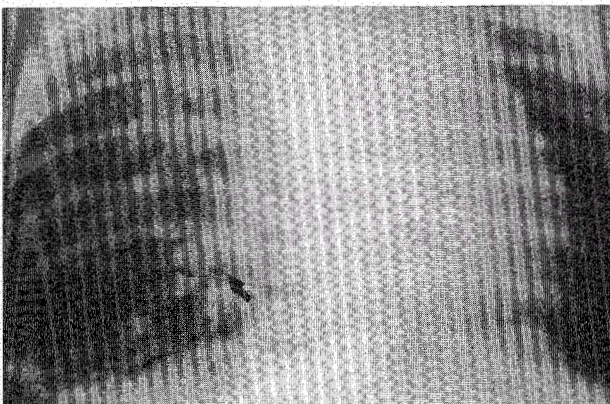
**Figure 3a,b.** Case 1: Coronal view, 3D reformation of tracheobronchial tree in shaded surface display (3a) and minimal intensity projection (3b) revealed narrowing right (R) and left (L) main bronchi and low position of the inverted-T appearance of the pseudocarina (arrow) giving off bridging bronchus (B) traversing the mediastinum to right lower lobe. Note also narrowing proximal segment of the bridging bronchus (arrowhead).

any consequence. Currently, he is 13 months and doing well, maintained with bronchodilator.

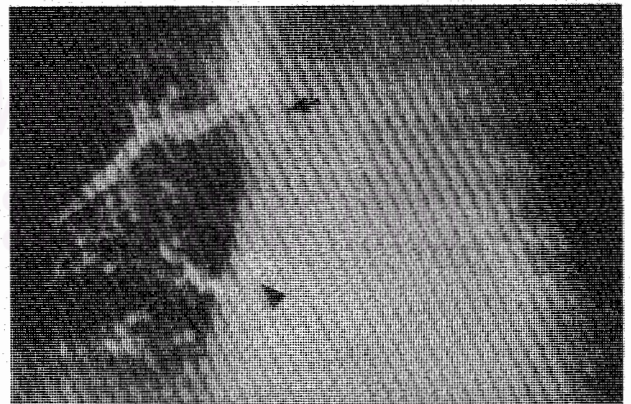## Case 2

A female neonate, born from normal delivery at 38-week gestation, weighed 2250 grams at birth, had imperforate anus with rectovestibular fistula, which was corrected at age of 8 weeks. Her right forearm was shorter than the left and the right thumb was rudimentary. Ten days after surgery, she developed dyspnea and tachypnea without fever. Chest radiograph showed perihilar and right lower lobe opacities. She was treated with erythromycin for 10 days and was having clinical improvement. She developed the second episode of respiratory distress with fever when she was 11 weeks old, on continuous medication. Suprasternal and substernal retraction were observed and medium crepitation from both lungs were heard. Her chest radiographic series showed poorly outlined tracheobronchial tree,

repetitive atelectasies of right lower lobe and left lung with mediastinal shift to the left. The atelectatic right lower lobe facilitated a visualization of an abnormal course of right lower bronchus that was less vertical than normal, reaching right side of the thoracic spine at T7-T8 level (Figure 4). The right main bronchus was not well visualized. An abnormal segmentation of the lower thoracic and the lumbar vertebral bodies were noted. Spiral CT scan was performed under sedation with chloral hydrate. She was intubated and had Ambu-bag assisted ventilation during the scanning. Reformation image from CT scan was unsuccessful due to misregistration from respiratory motion. However, raw data images revealed right lower lobe bronchus, originating from very narrow left main bronchus and horizontal course of the bronchus to the left lung. Persistent left SVC was identified. No pulmonary sling was presented. Two weeks later bronchography was performed to demonstrate the airway in coronal plane for treatment planning. Her



**Figure 4.** Case 2: The course of right lower lobe bronchus (arrow) was less vertical than usual. It reached right side of the mediastinum at T7-8 level. The right main bronchus was poorly seen.



**Figure 5.** Case 2: Bronchography revealed narrowing left main bronchus with additional proximal constriction (arrow), low position and inverted-T appearance of pseudocarina and the bridging bronchus (arrowhead).

bronchogram, using 2 ml of Iopromide 300, verified bridging bronchus with carina at T4-5 level and pseudocarina at T6 level, inverted-T appearance of pseudocarina, narrowing the whole length of the left main bronchus with additional focal constriction at proximal site (Figure 5). The right bronchial angle was 71 degrees; the left bronchial angle, 62 degrees. Her respiratory symptoms were treated conservatively. The patient is now 9 months old.

### Discussion

The two patients in our report had bridging bronchus with other associated anomalies. Their presenting symptoms were respiratory distress due to congenital narrowing of the tracheobronchial tree, exacerbated by lower respiratory tract infection.

"Bridging bronchus" is a bronchial branch to right middle and lower lobes<sup>(2)</sup> or to the entire right lung,<sup>(3)</sup> originated from the left main bronchus, typically at lower thoracic level than the carina. It has wider bronchial angles producing inverted-T appearance of the pseudocarina.<sup>(3,4,7)</sup> The normal level of the carina is T3-T4 at birth; and T4-T5, at about 2 years of age.<sup>(8)</sup> Normal bronchial angles for infants and young children were  $31 \pm 5$  degrees for the right, and  $49 \pm 7$  degrees for the left.<sup>(9)</sup> The pseudocarina of bridging bronchi were noted at T5-6 or T6-7 and reported bronchial angles were 76 degrees and 51 degrees for the right and left, respectively.<sup>(3)</sup> In our cases the pseudocarina were both at T6 level; right bronchial angles, 60 degrees and 71 degrees; and the left bronchial angles, 61 degrees and 62 degrees.

Bridging bronchus is significant because it usually causes severe respiratory distress. Long narrowing segment of the tracheobronchial tree was

originated from the absence of pars membranacium producing complete cartilaginous ring.<sup>(4,8,10-13)</sup>

Findings of bridging bronchus from chest radiographs were unrewarding and variable<sup>(2,4,8,10,13,14)</sup> that included normal finding, patchy infiltrates, repetitive atelectasis, cyst-like lucent region, generalized hyperinflation, unilateral aeration disturbance, dextrocardia, poorly-defined column of trachea. They might not show narrow tracheobronchial tree and inverted-T appearance of the pseudocarina. In both cases, repetitive atelectasis of the right lower lobe and left lung were observed from series of the chest radiographs. The atelectasis was caused by narrowing lumen of the left main bronchus, more compromised during respiratory tract infection with edematous epithelial cells and secretion. The atelectatic right lower lobe facilitated a visualization of an abnormal course of right lower lobe bronchus that was more parallel to that of the right main bronchus than converging to it. Even the right main bronchus was not clearly shown, the less vertical course of the right lower bronchus could be observed. The abnormal bronchial course was not appreciated during inflated right lower lobe.

Most of the reported cases were associated with sling left pulmonary artery.<sup>(3,4,8,10,12)</sup> It was recommended to evaluate the tracheobronchial tree in all of the patients, who have sling left pulmonary before operation, to rule out bridging bronchus or other airway anomaly. High kV and filtered technique with magnification<sup>(5,6)</sup> were recommended. However, in our case we first found anomaly of the airway and later discovered the vascular anomaly. We found sling left pulmonary artery in one case and persistent left superior vena cava in the other.

Bronchoscopy and bronchography were the modalities of choice for diagnosis of congenital bronchial anomalies but bronchography is being replaced by spiral CT.<sup>(1,13)</sup> Controlled ventilation of the patient during the scanning process is more promising to yield the informative reformation.

Spiral CT scans were performed with spontaneous breathing in case 1 and with assisted Ambu bag ventilation in case 2. Using shaded surface display (SSD) and minimum intensity projection (MIP) reformation technique, the abnormal airway in case 1 was clearly demonstrable. In case 2, because of moderate dyspnea, the reformation was unsuccessful, but from raw data the abnormal airway anatomy could be diagnosed.

Magnetic resonance imaging has no role in evaluation of the airway because respiratory motion causes lower spatial resolution and the 3D image of the tracheobronchial tree from magnetic resonance imaging is unsatisfactory.

Associated anomalies should be searched for in all cases of bridging bronchus, particular sling left pulmonary artery.<sup>(3,4,8,11,12)</sup> Other associated anomalies are imperforated anus,<sup>(2,3,4,8,10)</sup> abnormal segmentation of the spine,<sup>(8,10,14)</sup> congenital heart disease (ASD, VSD, PDA),<sup>(2,10,11)</sup> absence of the gallbladder,<sup>(3)</sup> horseshoe kidney,<sup>(10)</sup> bilobed right lung with the upper and middle lobes being fused,<sup>(2,4,8,10)</sup> and monolobed one or both lungs.<sup>(11)</sup> In our cases, the first patient had sling left pulmonary artery and persistent opening of foramen ovale, and the second had anorectal malformation, abnormal segmentation of the spine, anomaly of the limb and persistent left SVC.

## Conclusion

Bridging bronchus is a rare airway anomaly which is difficult to diagnose from plain chest

radiograph. However, there are some subtle findings that give substantial clues. Repetitive atelectasis of right lower lobe and the left lung, and visualization of abnormal course of right lower bronchus more parallel to the right main bronchus in the newborns or infants with recurrent dyspnea and/or pneumonia should suggest a diagnosis of bridging bronchus.

## References

1. Ghaye B, Szapiro D, Fanchamps JM, Dondelinger RF. Congenital bronchial abnormalities revisited. *Radiographics* 2001 Jan-Feb; 21 (1): 105 - 19
2. Gonzalez-Crussi F, Padilla LM, Miller JK, Grosfeld JL. "Bridging bronchus". A previously undescribed airway anomaly. *Am J Dis Child* 1976 Sep; 130(9): 1015 - 8
3. Wells TR, Gwinn JL, Landing BH, Stanley P. Reconsideration of the anatomy of sling left pulmonary artery: the association of one form with bridging bronchus and imperforate anus. Anatomic and diagnostic aspects. *J Pediatr Surg* 1988 Oct; 23(10): 892 - 8
4. Berdon WE, Baker DH, Wung JT, Chrispin A, Kozlowski K, de Silva M, Bales P, Alford B. Complete cartilage-ring tracheal stenosis associated with anomalous left pulmonary artery: the ring-sling complex. *Radiology* 1984 Jul; 152(1): 57 - 64
5. Joseph PM, Berdon WE, Baker DH, Slovis TL, Haller JO. Upper airway obstruction in infants and small children. Improved radiographic diagnosis by combining filtration, high kilovoltage, and magnification. *Radiology* 1976 Oct; 121(1):143 - 8
6. Deanfield JE, Leanage R, Stroobant J, Chrispin AR, Taylor JF, Macartney FJ. Use of high kilovoltage

- filtered beam radiographs for detection of bronchial situs in infants and young children. *Br Heart J* 1980 Nov; 44(5): 577 - 83
7. Medina-Escobedo G, Lopez-Corella E. Sling left pulmonary artery, bridging bronchus and associated anomalies. *Am J Med Gene* 1992 Oct; 44(3): 303 - 6
8. Noback GJ. The developmental topography of the larynx, trachea and lungs in the fetus, newborn, infant and child. *Am J Dis Child* 1923; 26: 515 - 33
9. Kubota Y, Toyoda Y, Nagata N, Kubota H, Sawada S, Murakawa M, Fujimori M. Tracho-bronchial angles in infants and children. *Anesthesiology* 1986 Mar; 64(3): 374 - 6
10. Starshak RJ, Sty JR, Woods G, Kreitzer FV. Bridging bronchus: A rare airway anomaly. *Radiology* 1981 Jul; 140(1): 95 - 6
11. Bamman JL, Ward BH, Woodrum DE. Aberrant left pulmonary artery. Clinical and embryologic factors. *Chest* 1977 Jul; 72(1): 67 - 71
12. Pawade A, de Leval MR, Elliott MJ, Stark J. Pulmonary artery sling. *Ann Thorac Surg* 1992 Nov; 54(5): 967 - 70
13. Stokes JR, Heatley DG, Lusk RP, Huddleston CT, Green CG. The bridging bronchus: Successful diagnosis and repair. *Arch otolaryngol head neck surg* 1997 Dec; 123(12): 1344 - 7
14. Hollinger PH, Johnston KC, Basinger CE. Benign stenosis of the trachea. *Ann Otol Rhinol Laryngol* 1950; 59: 837 - 59

สถาบันวิทยบริการ  
จุฬาลงกรณ์มหาวิทยาลัย