

Lung cancer in AIDS/HIV-infected patients: A report of two cases with the literature review

Yavarace Vongsivavilas*

Saowanee Yenrudi**

Vongsivavilas Y, Yenrudi S. Lung cancer in AIDS/HIV-infected patients: A report of two cases with the literature review. Chula Med J 2004 Sep; 48(9): 613 - 24

Several studies have suggested that AIDS/HIV-infected patients have an increased risk of developing primary lung cancer. We reported 2 cases of squamous cell lung cancer from 147 AIDS/HIV cohorts in our study. Both of them were much younger than the average age of Thai patients with lung cancer. Case 1 had history of heavy smoking, promiscuous heterosexual activities, and intravenous drug use with heroine. He presented with a left upper lobe mass. Case 2 presented with the right upper lobe mass and Tuberculosis with massive left pleural effusion. Fiberoptic bronchoscopy is an essential tool to obtain tissue for pathologic examination and establish the definite diagnosis of lung cancer. We critically reviewed numerous medical literatures and summarized the results as shown in Table 1 to 4.

Keywords : *AIDS, HIV, Lung cancer, Malignancy, Infection.*

Reprint request : Vongsivavilas Y, Department of Pathology, Chest Disease Institute,
Department of Medical Services, Ministry of Public Health, Nonthaburi,
Thailand.

Received for publication: May 10, 2004.

* Department of Pathology, Chest Disease Institute, Department of Medical Services, Ministry of Public Health, Nonthaburi

** Department of Pathology, Faculty of Medicine, Chulalongkorn University

เยาวเรศ วงศ์ศิวิลาส, เสาวณีย์ เย็นฤดี. โรคมะเร็งปอดในคนไข้ติดเชื้อ เอชดี/เอชไอวี : รายงานผู้ป่วย 2 รายพร้อมทั้งทบทวนบทความทางการแพทย์. จุฬาลงกรณ์เวชสาร 2547 ก.ย; 48(9): 613 – 24

หลายการศึกษาได้ชี้ให้เห็นถึงว่าผู้ป่วยติดเชื้อเอชดี / เอชไอวี มีความเสี่ยงสูงขึ้นในการที่จะเกิดโรคมะเร็งปอด ผู้เขียนได้รายงานผู้ป่วย 2 รายที่เป็นโรคมะเร็งปอดชนิดสแควมัสเซลล์ จากผู้ป่วยที่ติดเชื้อเอชดี / เอชไอวีจำนวน 147 รายจากงานวิจัยของผู้เขียน ผู้ป่วยทั้ง 2 รายนี้มีอายุน้อยกว่าอายุเฉลี่ยของคนไทยทั่วไปที่ป่วยเป็นโรคมะเร็งปอดเป็นอย่างมาก ผู้ป่วยรายแรกมีประวัติสูบบุหรี่จัดมาก เที้ยวสำส่อน และติดยาเสพติดเฮโรอีนชนิดฉีดเข้าเส้นเลือด ผู้ป่วยรายนี้มาด้วยก้อนที่กลีบปอดซ้ายด้านบน ส่วนผู้ป่วยรายที่สองมาด้วยก้อนที่กลีบปอดขวาด้านบน และวัณโรค รวมทั้งน้ำท่วมปอดข้างซ้ายอย่างรุนแรง การส่องกล้องตรวจหลอดลมเป็นวิธีการที่จะได้มาซึ่งชิ้นเนื้อเพื่อนำมาตรวจทางพยาธิวิทยาและให้การวินิจฉัยโรคมะเร็งปอดได้อย่างแม่นยำ ผู้เขียนได้ทบทวนหลายบทความทางการแพทย์อย่างละเอียดถี่ถ้วน และรวบรวมสรุปผลดังที่ปรากฏให้เห็นในตารางที่ 1 ถึง 4

คำสำคัญ: เอชดี, เอชไอวี, โรคมะเร็งปอด, โรคมะเร็ง, โรคติดเชื้อ

Several western reports have suggested the association between lung cancer and acquired immunodeficiency syndrome (AIDS)/ human immunodeficiency virus (HIV) infection. We reported histopathology of lung complications in 147 AIDS/HIV-infected Thai patients.⁽¹⁾ To our surprise, instead of finding Kaposi's sarcoma or non-Hodgkin's lymphoma, the two most common neoplastic complications of AIDS in industrialized countries, we found 2 cases of squamous cell lung cancer in our study. This finding is unusual because squamous cell lung cancer is not the most common cell type in Thai population and not the predominant cell type of lung cancer in AIDS/HIV in the Western reports either. In Thailand, the information on the relationship between AIDS/HIV infection and lung cancer is sparse despite the high prevalence of AIDS/HIV infection. We would like to present these cases from our study and review the literatures.

Case 1

A 43 year-old married man with a 28 pack-year history of cigarette smoking came to the hospital with the complaint of cough, chest pain, dyspnea, malaise and headache for 2 weeks. He had never sought medical attention. He used to be a laborer but currently unemployed. Due to his being a thin, cachectic-looking man in respiratory distress, HIV antibody was tested and the results were positive. During the post-counseling session, he disclosed the history of promiscuous heterosexual activities and intravenous drug use (IVDU) with heroine but denied drinking alcohol. A complete blood count revealed a chronic simple anemia, adequate platelet count, and slight elevation of white blood cell count. His urinalysis




Figure 1. Biopsy at distal left main bronchus reveals moderately differentiated squamous cell carcinoma, (H&E stain X100).

and chemistry profiles were within normal limit. Sputum exam and culture for acid fast bacilli were negative on three occasions. Carcinoembryonic antigen (CEA) was 5.9 ng/ml (normal 0-5 ng/ml). Chest X-rays (CXR) showed a haziness of the left lung field for which it was interpreted as being a left upper lobe mass with a collapsed left lung. Fiberoptic bronchoscopy (FOB) revealed an irregular narrowing of distal left main bronchus with a mass obliterating the left upper lobe orifice and narrowing of the left lower lobe orifice. Microscopic examination of the three bronchial biopsies disclosed a moderately differentiated squamous cell carcinoma, (Figure 1). Disease was staged clinically according to standard criteria as stage III-IV and was considered inoperable. He denied further treatment and requested to return home.

Case 2

A 49 year-old married man with a 16 pack-year history of tobacco use was admitted to the hospital with the history of cough with white sputum, dyspnea, malaise, weakness, and loss of appetite for 2 months. On the day of admission, he also had a

low-grade fever and hemoptysis. He admitted of having HIV test positive. He also gave a history of occasional alcohol ingestion but denied promiscuous heterosexual activities or IVU. CXR revealed an ill-defined mass at the right upper lobe and a massive left pleural effusion. Sputum smear for acid-fast bacilli was positive for 3 times. A left thoracentesis was done and 900 ml of serosanguinous fluid was obtained. After 3 days of hospitalization, he was discharged to home with anti-tuberculous drugs, vitamin and bactrim. He returned for a follow up 6 weeks later with improvement of his symptoms. A repeat CXR revealed an improved left pleural effusion but slight enlargement of the right upper lobe mass. Two and a half months after anti-tuberculous therapy, another followed up CXR showed further enlargement of the right upper lobe mass and minimal left pleural effusion. He was told to continue taking his home medication and was scheduled for FOB. Unfortunately, he did not show up for 6 months. When he returned, a repeat CXR revealed a markedly enlarged right upper lobe mass and the disappearance of left pleural effusion. FOB was done a month later and revealed the necrotic tissue completely occluded the right upper lobe orifice. Pathologic diagnosis of the bronchial biopsy was non-small cell carcinoma, suggestive of poorly differentiated squamous cell carcinoma, (Figure 2). At this time, he also complaint of headache, nausea, vomiting and malaise. CEA was 2.4 ng/ml (normal 0-5 ng/ml) and cryptococcal antigen was negative. He was then referred to Thai National Institute of Cancer in Bangkok for irradiation. A month later, his headache got worse. Computed tomographic scan of the brain revealed a large mass of 4.6 X 2.8 cm. with ring enhancement at the right parieto-occipital area and

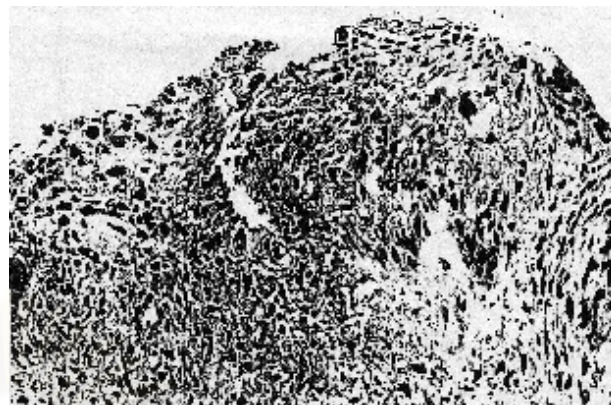


Figure 2. Bronchial biopsy at right upper lobe bronchus shows poorly differentiated squamous cell carcinoma, (H&E stain X 200).

brain swelling. Metastasis of lung cancer to the brain was diagnosed. He denied further treatment and went back home.

Unfortunately, CD4 count or features indicated low CD4 count were not available in the medical records of these patients.

Discussion

Prior to 1998, more than 100 cases of lung cancer have been reported in AIDS/HIV-infected patients.⁽²⁻¹³⁾ Despite such reports, the increased risk of lung cancer in AIDS/HIV-infected patients was originally regarded as a coincidental. Some authors believed there was insufficient data to support the linkage between the two diseases.^(4, 7) The literature review is shown in Table 1 to 4. The epidemiologic data became available in 1998 when Parker et al reported 36 HIV-infected patients with lung cancer.⁽¹⁴⁾ Their data also indicated a 6.5-fold increased incidence of primary lung cancer in HIV-infected patients. Since then, many authors have shown convincing epidemiologic data to confirm lung cancer risk in AIDS/HIV-infected patients.⁽¹⁵⁻²³⁾

Table 2. Histopathologic types of lung cancer in 104 AIDS/HIV infected patients (from reports before 1998).

Cell types	Author		Braun		Sridhar		Vaccher		Gruden		Karp		Chan		Tenholder		Aaron		Fishman		Gonzalez		Total	
	USA	Italy	USA	USA	USA	USA	USA	USA	USA	USA	USA	USA	USA	USA	USA	USA	USA	USA	USA	USA	Spain	(Percent)		
AdenoCA	4	8	11	2	7	3	1	1	1	1	1	1	1	13	2	52 (50.00 %)								
Squamous cell CA	1	6	2	2										9	4	24 (23.08 %)								
Adenosquamous CA	1	1	1	1										2	1	4 (3.85 %)								
Large cell undifferentiated CA	2	1	1	1										2	1	9 (8.65 %)								
Small cell CA	1	1	3	1										2	2	10 (9.62 %)								
Mixed Small/ Large cell CA	1	1												1	1	2 (1.92 %)								
Other CA			1											1	1	2 (1.92 %)								
Mesothelioma			1													1 (0.96 %)								
Unspecified																0								
Number of patients	6	19	19	7	7	4	2	3	30	7	104 (100 %)													

CA: Carcinoma. The number in column: number of cases.

Table 3. Clinical features of AIDS/HIV infected patients with lung cancer (from reports since 1998).

Clinical Data	Parker USA		Spina Italy		Bazot France		Frisch USA		Caihol France		Demopoulos USA		Bower England		Pre-HAART 1986-1996		Post-HAART 1997-2002	
	1998	1999	2000	2001	2003	2003	2003	2003	2003	2003	2003	2003	2003	2003	2003	2003	2003	
Year of report	1998	1999	2000	2001	2003	2003	2003	2003	2003	2003	2003	2003	2003	2003	2003	2003	2003	
Number of patients	36	39	15	808	5	5	19	2	2	2	19	2	2	2	2	2	9	
Median Age (Years)	49	38	48	-	50	50	-	51	51	51	-	51	51	51	51	51	44	
Age Range (Years)	-	28-58	-	-	43-74	43-74	-	-	-	-	-	-	-	-	-	-	-	-
Gender Male	35	35	-	698	5	5	-	10	10	10	-	10	10	10	10	10	10	
Female	1	2	-	110	0	0	-	1	1	1	-	1	1	1	1	1	1	
CD4 cell count (Range)	-	-	189	-	245-573	245-573	-	100	100	100	-	100	100	100	100	100	180	
Risk factors	-	-	-	-	-	-	-	-	-	-	-	-	-	-	-	-	-	
Smoking	-	-	15	-	5	5	17	2	2	2	17	2	2	2	2	2	9	
Homosexual	-	-	-	-	4	4	-	10	10	10	-	10	10	10	10	10	10	
Bisexual	17	-	-	-	-	-	-	-	-	-	-	-	-	-	-	-	-	
IVDU	9	27	-	310	-	-	14	1	1	1	14	1	1	1	1	1	1	
Homosexual-IVDU	3	-	-	336	-	-	65	-	-	-	65	-	-	-	-	-	-	
Heterosexual/Promiscuity	2	-	-	65	-	-	-	-	-	-	-	-	-	-	-	-	-	
Transfusion/transplant	1	-	-	-	-	-	-	-	-	-	-	-	-	-	-	-	-	
Hemophilia	1	-	-	12	-	-	-	-	-	-	-	-	-	-	-	-	-	
Unspecified risk	3	12	-	85	1	1	5	5	5	5	5	5	5	5	5	5	5	
Stage III-IV	-	-	11	-	5	5	-	2	2	2	-	2	2	2	2	2	9	

The last 3 columns are the studies of Bower from England during Pre-HAART and Post-HAART periods.

Table 4. Histopathologic types of lung cancer in AIDS/HIV infected patients (from reports since 1998).

Cell types	Author		Parker		Spina		Bazot		Frisch		Caihol		Demopoulos		Bower		Total	
	USA	Italy	France	USA	France	USA	France	USA	France	USA	France	USA	England	England	(Percent)			
AdenoCA	7	15	7	243*	7	3	6#								281 (30.12 %)			
Squamous cell CA	7			191		1	4								203 (21.76 %)			
Adenosquamous CA	2														2 (0.21 %)			
Large cell undifferentiated CA	3														3 (0.32 %)			
Small cell CA	3	5		68		1	1								78 (8.36 %)			
Mixed Small/ Large cell CA	4	16	8												0			
Other CA	1	3													28 (3.00 %)			
Mesothelioma	9			306						19					4 (0.43 %)			
Unspecified	36	39	15	808	15	5	11			19					334 (35.80 %)			
Number of patients															933 (100 %)			

CA: Carcinoma. The number in column: number of cases.

*Includes 15 of Bronchioloalveolar carcinoma. # Includes 1 of Bronchioloalveolar carcinoma.

Reports of cigarette smoking have been high and up to 100 % in some series.^(5, 8-10, 16, 19, 21, 23) Some of these authors have speculated tobacco usage playing a role in the pathogenesis of lung cancer in HIV-infected patients. However, other reports have shown that the incidence of primary lung cancer in HIV-infected patients is greater than one would expect on the basis of smoking alone.⁽¹⁴⁻²³⁾ Moreover, many reports indicate the predominant cell type in HIV-infected patients is adenocarcinoma, the cell type that is less affected by tobacco usage.

According to the literature review⁽²⁻²³⁾, the characteristics of AIDS/HIV-related lung cancer include younger age, IVDU, predominance of adenocarcinoma cell type, advanced stage at presentation, and aggressive behavior. Some reports have shown that the development of lung cancer is not associated with a low CD4 cell count, suggesting that immune function has less role in these tumors than in Kaposi's sarcoma and primary cerebral lymphoma.^(16, 22)

Lung cancer is the most common cause of cancer deaths in the United States and worldwide.⁽²⁴⁾ Thai statistics indicated lung cancer was the most common cancer in men and the third most common in women and male to female ratio was 2.66:1. The age-standardized rates (ASR) of lung cancer in Bangkok during 1993–1997 were 31.4 per 100,000 males and 9.6 per 100,000 females.⁽²⁵⁾ Adenocarcinoma was the most common histologic type of lung cancer in Thai population particularly in women and constituted 50.9 % whereas squamous cell carcinoma was 33.7 %.⁽²⁶⁾ The ratio of adenocarcinoma and squamous cell carcinoma was 606:482 (1.3:1) for men and 340:89 (3.8:1) for

women.⁽²⁵⁾

The true frequency of lung cancer in AIDS/HIV infection is not known. In our research study, two cases of squamous cell lung cancer were found in 147 AIDS/HIV cohorts. This indicates the frequency of lung cancer among Thai patients with HIV-infection to be 1,360 per 100,000 HIV population. This figure is strikingly high and it also indicates a 43-fold increased incidence of lung cancer among HIV-infected Thai men. The early report of Braun et al documented six cases of lung cancer occurring in a population of 500 HIV-infected patients, equivalent to 1,200 cases per 100,000 HIV population.⁽²⁾ They stated a 14-fold increased risk when compared to the overall risk of lung cancer for the white man which was 85 cases per 100,000 population. Although, these series involve a small number of patients, they serve as a basis for further investigations and finally the controversy has come to rest. The recent report of Frisch et al is quite convincing. It indicates relative risk (RR) of lung cancer to be 4.5.⁽²²⁾ RR is calculated by dividing the number of observed cancer cases by the number of expected cases based on contemporaneous population-based incidence rates.

We found no other malignancies in our study. It is possible that most Thai AIDS patients in this study do not live long enough to develop malignant tumors except lung cancer that may develop at the early stage of HIV infection. The majority of them have died of opportunistic infections. The patients in this report did not received antiretroviral drugs. They were much younger than the average age of Thai patients with lung cancer. They also had history of smoking but only one was considered to be a heavy smoker. However, tobacco usage alone cannot be regarded

as the sole cause of lung cancer in these cases.

The association between human papilloma-virus (HPV) and squamous cell lung cancer has been reported but with controversy. Isolation of HPV in squamous cell lung cancer by *in situ* hybridization (ISH) or polymerase chain reaction (PCR) varies from 4/28 (15 %) to 34/43 (79 %).⁽²⁷⁾ However, the results are difficult to interpret. Some investigators believe HPV may be just an 'innocent bystander' and has no role in the pathogenesis of lung cancer at all. Moreover, the copy numbers of HPV in these cancers are low. Its presence may not be significant or it may indicate a nonclonal association of the tumor with HPV. If this is proved to be correct, then HPV is not required for the maintenance of the malignant state. A 'hit and run' theory has frequently been proposed too. If this mechanism can be confirmed *in vivo*, HPV negative carcinomas might have developed from HPV containing precursors. We believe pathogenesis of lung cancer in AIDS/HIV is a multi-factorial. Local immunity and cytopathic effect of HIV may play a major role in the development of lung cancer.

With an introduction of the highly active antiretroviral therapy (HAART) in Thailand in the past couple years, Thai patients with AIDS/HIV-infection may live longer, as such they will be at increased risk of developing a variety of malignancies. This can pose diagnostic challenges for the physicians. Lung cancer in AIDS/HIV-infected patients is difficult to diagnose due to unusual presentation, atypical lung lesions that may mimic or be obscured by a variety of opportunistic infections, and poor patient compliance or unsuitable general condition to tolerate the diagnostic procedure. The delayed diagnosis of lung cancer in case 2 is due to the coexistent of

Tuberculosis with pleural effusion.

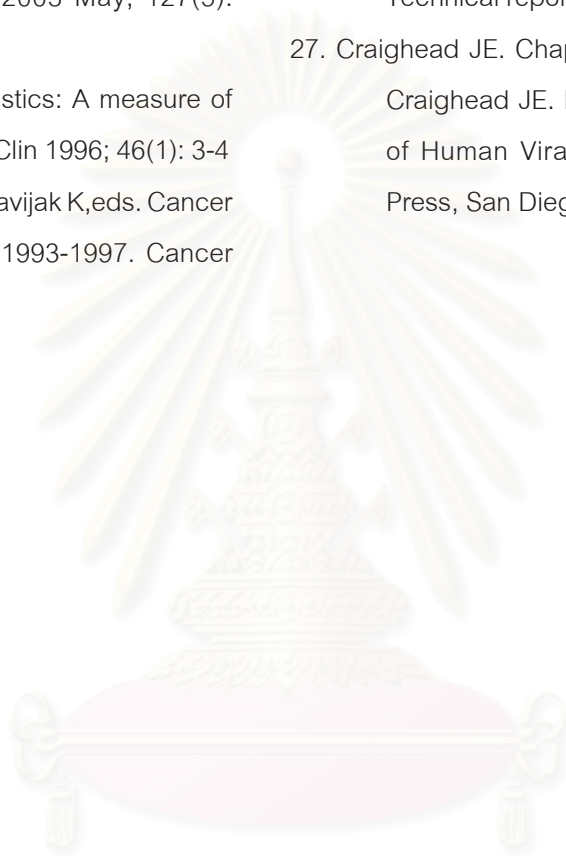
It is very important to be well aware of lung cancer risk, or else lung cancer will continue to be undiagnosed. For physicians taking care of HIV-infected patients, primary lung cancer must now be in the differential diagnosis of abnormal CXR, especially a solitary nodule. Investigations including FOB with biopsy and/or fine needle aspiration should be performed in all HIV-infected patients with masses, nodules, or focal lesions that persist despite appropriate treatment for opportunistic infections.

References

1. Vongsivavilas Y, Yenrudi S. Histopathology of lung complications in 147 AIDS/HIV infected Thai patients. Chula Med J 2003 Oct; 47(10): 641 - 51
2. Bruan MA, Killam DA, Remick SC, Ruckdeschel JC. Lung cancer in patients seropositive for human immunodeficiency virus. Radiology 1990 May;175(2): 341 - 3
3. Sridhar KS, Flores MR, Raub WA Jr, Saldana M. Lung cancer in patients with human immunodeficiency virus infection compared with historic control subjects. Chest 1992 Dec; 102(6): 1704 - 8
4. Vaccher E, Tirelli U, Spina M, Errante D, Crosata I, Sabbatani S, Sinicco A, Monfardini S. Lung cancer in 19 patients with HIV infection [letter to the editor]. Ann Oncol 1993 Jan; 4(1): 85 - 6
5. Gruden JF, Webb WR, Yao DC, Klein JS, Sandhu JS. Bronchogenic carcinoma in 13 patients infected with the human immunodeficiency virus (HIV): clinical and radiographic findings. J Thorac Imaging 1995; 10(2): 99-105

6. Karp J, Profeta G, Marantz PR, Karpel JP. Lung cancer in patients with immunodeficiency syndrome. *Chest* 1993 Feb; 103(2): 410 - 3
7. Chan TK, Aranda CP, Rom WN. Bronchogenic carcinoma in young patients at risk for acquired immunodeficiency syndrome. *Chest* 1993; 103: 862 - 64
8. Tenhoder MF, Jackson HD. Bronchogenic carcinoma in patients seropositive for human immunodeficiency virus. *Chest* 1993 Oct; 104(4): 1049 - 53
9. Aaron SD, Warner E, Edelson JD. Bronchogenic carcinoma in patients seropositive for human immunodeficiency virus. *Chest* 1994 Aug; 106(2): 640 - 2
10. Fishman JE, Schwartz DS, Sais GJ, Flores MR, Sridhar KS. Bronchogenic carcinoma in HIV-positive patients: finding on chest radiographs and CT scan. *AJR AM J Roentgenol* 1995 Jan; 164(1): 57 - 61
11. Remick SC. Lung cancer: An HIV-related neoplasm or a coincidental finding? *Chest* 1992 Dec; 102 (6): 1643 - 4
12. Santos Gonzalez J, Velasco Garrido JL, Rivero Roman A, Marquez Solero M, Abarca Costalago M. Cancer of the lung in patients with HIV infection. *Rev Clin Esp* 1996 Sep; 196 (9): 603 - 5
13. Fraire AE, Awe RJ. Lung cancer in association with human immunodeficiency virus infection. *Cancer* 1992 Jul; 70 (2): 432 - 6
14. Parker SM, Leveno MD, Campbell TJ, Worrell JA, Carozza SE. AIDS-Related Bronchogenic carcinoma, Fact or Fiction? *Chest* 1998 Jan; 113(1): 154 - 61
15. Burke M, Furman A, Hoffman M, Marmor S, Blum A, Yust I. Lung cancer in patients with HIV infection: is it AIDS-related? *HIV Med* 2004 Mar; 5 (2): 110 - 4
16. Cailhol J, Calatroni MI, Roudiere L, Aaron L, Viard JP. Increased incidence of lung neoplasms among HIV-infected men and the need for improved prevention. *J Acquir Immune Defic Syndr*. 2003 Oct 1; 34(2): 247 - 9
17. Chiao EY, Krown SE. Update on non-acquired immunodeficiency syndrome-defining malignancies. *Curr Opin Oncol* 2003 Sep; 15(5): 389 - 97
18. White JD, Bowman CA, Woll PJ. Lung cancer as the presenting feature of AIDS. *Lung cancer* 2001 Jul; 33(1): 81 - 7
19. Bower M, Powles T, Nelson M, Shah P, Cox S, Mandelia S, Gazzard B. HIV-related lung cancer in the era of highly active antiretroviral therapy. *AIDS* 2003 Feb 14; 17 (3): 371 - 5
20. Spina M, Sandri S, Serraino D, Gobitti C, Fasan M, Sinicco A, Garavelli PL, Ridolfo A, Tirelli U. Therapy of non-small-cell lung cancer (NSCLC) in patients with HIV infection. *GICAT. Cooperative Group on AIDS and Tumors. Ann Oncol* 1999; 10 Suppl 5: S87 - 90
21. Bazot M, Cadranel J, Khalil A, Benayoun S, Milleron B, Bigot JM, Carette MF. Computed tomographic diagnosis of bronchogenic carcinoma in HIV-infected patients. *Lung Cancer* 2000 Jun; 28 (3): 203 - 9
22. Frisch M, Biggar RJ, Engels EA, Goedert JJ. AIDS-Cancer Match Registry Study Group. Association of cancer with AIDS-related immunosuppression in adults. *JAMA* 2001

- Apr 4; 285 (13): 1736 - 45
23. Demopoulos BP, Vamvakas E, Ehrlich JE, Demopoulos R. Non-acquired immunodeficiency syndrome-defining malignancies in patients infected with human immunodeficiency virus. Arch Pathol Lab Med 2003 May; 127(5): 589 - 92
24. Lenhard RE Jr. Cancer statistics: A measure of progress. CA Cancer J Clin 1996; 46(1): 3-4
25. Martin N, Sontipong S, Chindavijak K, eds. Cancer incidence in Bangkok, 1993-1997. Cancer Research Foundation for National Cancer Institute, © 2001: 9
26. Vatanasapt V, Martin N, Sriplung K, Chindavijak K, Sontipong S, Sriamporn S, Parkin DM, Ferlay J. Cancer in Thailand 1988-1991. IARC Technical report, Lyon 1993; 16: 66
27. Craighead JE. Chapter 21 Papillomaviruses. In: Craighead JE. Pathology and Pathogenesis of Human Viral Disease. (Ed), Academic Press, San Diego, © 2000: 321



สถาบันวิทยบริการ
จุฬาลงกรณ์มหาวิทยาลัย