

ผลทางวิทยาเนื้อเยื่อของคาร์โบฟูแรนต่อปลาหางนกยูง *Poecilia reticulata* Peters



นางสาว วชิพร เย็นจ๋า

ศูนย์วิทยทรัพยากร
จุฬาลงกรณ์มหาวิทยาลัย

วิทยานิพนธ์นี้เป็นส่วนหนึ่งของการศึกษาตามหลักสูตรปริญญาวิทยาศาสตรดุษฎีบัณฑิต

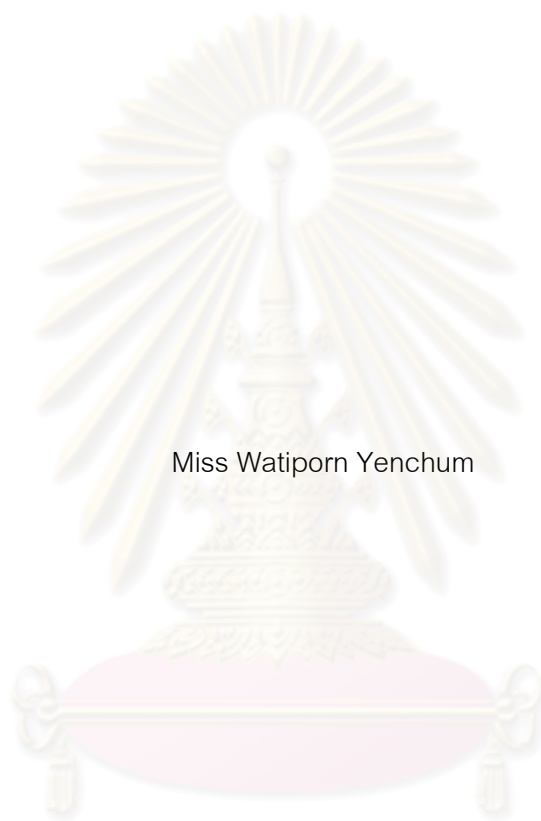สาขาวิชาวิทยาศาสตร์ชีวภาพ

คณะวิทยาศาสตร์ จุฬาลงกรณ์มหาวิทยาลัย

ปีการศึกษา 2553

ลิขสิทธิ์ของจุฬาลงกรณ์มหาวิทยาลัย

HISTOLOGICAL EFFECTS OF CARBOFURAN ON GUPPY *Poecilia reticulata* Peters



Miss Watiporn Yenchum

ศูนย์วิทยทรัพยากร
จุฬาลงกรณ์มหาวิทยาลัย

A Dissertation Submitted in Partial Fulfillment of the Requirements
for the Degree of Doctor of Philosophy Program in Biological Sciences

Faculty of Science

Chulalongkorn University

Academic Year 2010

Copyright of Chulalongkorn University

วิพร เย็นฉ่ำ : ผลทางวิทยาเนื้อเยื่อของคาร์โบฟูแรนต่อปลาหางนกยูง *Poecilia reticulata* Peters. (HISTOLOGICAL EFFECTS OF CARBOFURAN ON GUPPY *Poecilia reticulata* Peters) อ.ที่ปรึกษาวิทยานิพนธ์หลัก: รศ. ดร. กิ่งแก้ว วัฒนเสริมกิจ, อ.ที่ปรึกษาวิทยานิพนธ์ร่วม: อ. ดร. จิรารัช กิตนะ, 188 หน้า.

คาร์โบฟูแรนเป็นสารฆ่าแมลงกลุ่มคาร์บาเมต ใช้อย่างกว้างขวางในการเพาะปลูกและนาข้าวทั่วประเทศ ไทย ถึงแม้มีรายงานว่าคาร์โบฟูแรนมีความเป็นพิษต่ำต่อสัตว์เลี้ยงลูกด้วยนม แต่พบว่ามีพิษสูงต่อสัตว์น้ำ การศึกษานี้ใช้ปลาหางนกยูง *Poecilia reticulata* ศึกษาผลกระทบของคาร์โบฟูแรนต่อสัตว์น้ำ การศึกษาความเป็นพิษเฉียบพลันของคาร์โบฟูแรนต่อปลาหางนกยูงเป็นเวลา 96 ชั่วโมง ได้ค่า LC_{50} เท่ากับ 0.10 ส่วนในล้านส่วน ซึ่งแสดงว่าคาร์โบฟูแรนมีความเป็นพิษสูงต่อปลาชนิดนี้ ศึกษาจุลพยาธิวิทยาของปลาหางนกยูงหลังจากเลี้ยงในสารละลายคาร์โบฟูแรนระยะสั้นและการกลับคืนสู่เนื้อเยื่อปกติ โดยวิธีทางเนื้อเยื่อวิทยาและฮิสโตเคมี ปลาหางนกยูงเลี้ยงในสารละลายคาร์โบฟูแรนความเข้มข้น 0.005 0.01 0.025 0.04 และ 0.05 ส่วนในล้านส่วน เป็นระยะเวลา 6 24 48 72 และ 96 ชั่วโมง ผลการศึกษาเนื้อเยื่อวิทยาเหงือก ตับ และไต พบการเปลี่ยนแปลงทางจุลพยาธิสภาพ ผลการกลับคืนสู่เนื้อเยื่อปกติ พบว่าความผิดปกติที่พบในเนื้อเยื่อเหงือกสามารถกลับคืนสภาพสู่เนื้อเยื่อปกติได้ แต่ความผิดปกติในตับและไตไม่สามารถกลับคืนสภาพสู่เนื้อเยื่อปกติได้ การสะสมไขมันในตับของกลุ่มทดลองเพิ่มขึ้นอย่างมีนัยสำคัญเมื่อเปรียบเทียบกับกลุ่มควบคุม ($P < 0.05$) นอกจากนี้การศึกษานเนื้อเยื่อวิทยาหลังจากเลี้ยงในสารละลายคาร์โบฟูแรนความเข้มข้น 0.04 ส่วนในล้านส่วน ระยะยาวเป็นเวลา 5 เดือน ผลจุลพยาธิวิทยาพบว่าเหงือก ตับ ไต และอวัยวะสืบพันธุ์มีการเปลี่ยนแปลงหลายประการ การสะสมไขมันในตับเพิ่มขึ้นอย่างมีนัยสำคัญในกลุ่มทดลอง ($P < 0.05$) ความรุนแรงของการเกิดจุลพยาธิสภาพเพิ่มขึ้นเมื่อเวลาและความเข้มข้นเพิ่มขึ้น การศึกษาความเป็นพิษของระบบสืบพันธุ์ในมนุษย์และสัตว์ป่ายังคงมีข้อจำกัด การศึกษานี้ใช้ปลาหางนกยูงในการประเมินผลกระทบของคาร์โบฟูแรนระหว่างการตั้งท้อง ผลการศึกษาจำนวนลูกปลาหางนกยูงต่อคอกทดลองอย่างมีนัยสำคัญในกลุ่มทดลองที่เลี้ยงในสารละลายคาร์โบฟูแรนความเข้มข้น 0.05 ส่วนในล้านส่วน ($P < 0.05$) มีค่า 9.0 ± 0.3 ตัวต่อคอก เช่นเดียวกับผลของดัชนีการเกิดของลูกปลาที่ลดลงอย่างมีนัยสำคัญในกลุ่มทดลองความเข้มข้น 0.01 และ 0.05 ส่วนในล้านส่วน มีค่า 92.46 และ 77.58 เปอร์เซ็นต์ตามลำดับ ($P < 0.05$) นอกจากนี้การอยู่รอดของลูกปลาลงการเกิด 15 วัน ลดลงอย่างมีนัยสำคัญในกลุ่มทดลองที่ความเข้มข้น 0.01 และ 0.05 ส่วนในล้านส่วน ($P < 0.05$) มีค่า 90.68 และ 68.18 เปอร์เซ็นต์ตามลำดับ ขณะที่ระยะการตั้งท้องของปลาหางนกยูงในกลุ่มทดลองเพิ่มขึ้นอย่างมีนัยสำคัญ ($P < 0.05$) นอกจากนี้พบความผิดปกติของรูปร่างลักษณะของลูกปลาหางนกยูง 2 เปอร์เซ็นต์ของจำนวนลูกปลาในกลุ่มทดลองที่เลี้ยงในสารละลายคาร์โบฟูแรนความเข้มข้น 0.05 ส่วนในล้านส่วน โดยลูกปลาเกิดใหม่มี 2 หัว ใน 1 ตัว จากผลการศึกษาสรุปว่าคาร์โบฟูแรนสามารถทำให้เกิดความเสียหายต่อเนื้อเยื่อของปลาหางนกยูงหลังจากเลี้ยงในสารละลายคาร์โบฟูแรนทั้งระยะสั้นและระยะยาว และมีผลต่อจำนวนลูกต่อคอกของปลาหางนกยูงเพศเมีย เพิ่มระยะการตั้งท้อง การลดลงของดัชนีการเกิดและการลดจำนวนการอยู่รอดของลูกปลาในรุ่นที่ 1

สาขาวิชา.....วิทยาศาสตร์ชีวภาพ.....

ปีการศึกษา.....2553.....

ลายมือชื่อนิสิต..... วิพร เย็นฉ่ำ

ลายมือชื่อ อ.ที่ปรึกษาวิทยานิพนธ์หลัก..... กิ่งแก้ว วัฒนเสริมกิจ

ลายมือชื่อ อ.ที่ปรึกษาวิทยานิพนธ์ร่วม..... จิรารัช กิตนะ

4973841423 : MAJOR BIOLOGICAL SCIENCES

KEYWORDS : CARBOFURAN / *POECILIA RETICULATA* / HISTOLOGY / REPRODUCTIVE TOXICITY

WATIPORN YENCHUM: HISTOLOGICAL EFFECTS OF CARBOFURAN ON GUPPY *Poecilia reticulata* Peters. ADVISOR: ASSOC. PROF. KINGKEAW WATTANASIRMKIT, Ph.D., CO-ADVISOR: JIRARACH KITANA, Ph.D., 188 pp.

Carbofuran is a carbamate insecticide widely used on crops and in rice fields throughout Thailand. Although it has been reported to have low toxicity on mammals, it frequently found to be highly toxic on aquatic animals. In this study, guppy *Poecilia reticulata* was used to examine effects of carbofuran on aquatic organism. The acute toxicity of carbofuran on guppy at 96 hours showed the LC_{50} at 0.10 ppm, indicating its high toxicity to this fish species. Histopathology of carbofuran on guppy after short-term exposure and its recovery response were studied using histological and histochemical method. The guppies were exposed to carbofuran at 0.005, 0.01, 0.025, 0.04 and 0.05 ppm for 6, 24, 48, 72 and 96 hours. The results in gill, liver and kidney tissues showed histopathological changes. The recovery study showed that the lesions found in gill tissues were reversible while the lesions in liver and kidney tissues were irreversible. The lipid accumulation in liver of treatment group was significantly increased comparing with control groups ($P < 0.05$). Moreover, long-term exposure to 0.04 ppm carbofuran for 5 months was conducted on guppy. The results on histopathology of gill, liver kidney and gonad tissues showed various histological alterations. The lipid accumulation was also significantly increased in the treatment group ($P < 0.05$). The severity of histopathological effects of carbofuran found to be increase with time. The study of reproductive toxicity of carbofuran on human and wildlife is still limited. In this study, guppy was selected for an assessment of carbofuran effect during pregnancy. Reproductive capability of female guppy exposed to 0.05 ppm carbofuran was significantly reduced to 9.0 ± 0.3 individuals per female. Similarly, live birth index significantly decreased to 92.46% and 77.58% in 0.01 ppm and 0.05 ppm treatment group, respectively. Moreover, survival of offspring at the 15th day after birth was significantly reduced to 90.68% and 68.18% in 0.01 ppm group and 0.05 ppm treatment groups, respectively ($P < 0.05$). On the other hand, the pregnant period of female guppy was significantly increased in treatment groups ($P < 0.05$). Significant findings on morphological abnormality of the offspring revealed that 2% of the newborn in 0.05 ppm treatment had two heads in one body. The result from this study suggested that carbofuran can damage fish tissues and can impair reproductive capability of female guppy and reduce live birth index and the first generation (F_1).

Field of Study:Biological Sciences.....

Student's Signature..... Watiporn Yenchum.....

Academic Year:2010.....

Advisor's Signature..... K. Wattanasirmit.....

Co-advisor's Signature..... Jirarach Kitana.....

ACKNOWLEDGEMENTS

With my respect and heartfelt appreciation, I would like to express my deepest gratitude to my advisor, Associate Professor Dr. Kingkaew Wattanasirmit and my co-advisor, Dr. Jirarach Kitana for her encouragements, kindness supports and invaluable suggestions. Both of them played an influential role in encouraging and stimulating activity in my laboratory work. Moreover they were enthusiastically giving comments and suggestions while I had been writing dissertation book.

I would like to express my grateful thank to Associate Professor Dr. Kumthorn Thirakhupt, chairman of the thesis committee for his valuable advice. I also would like to express my appreciation to Assistant Professor Dr. Kanoktip Packdibamrung, Assistant Professor Dr. Duangkhae Sitthicharoenchai and Associate Professor Dr. Korakod Indrapichate, the thesis committee member for their valuable suggestions and comments.

I would like to thank Mr. Wattasit Siriwong, Miss Juthasiri Rohitrattana, Miss Waristha Angsirijinda, Mr. Sinlapachai Senarat and all members of the histology lab for their supports, suggestions and moral supports. The cheerful willingness of my friends is truly appreciated. I would like to thank the Department of Biology, Faculty of Science, Chulalongkorn University for facilities.

My greatest thanks is to the Development and Promotion of Science and Technology Talents Project (DPST) and a research fund from Graduate School, Chulalongkorn University who supports the scholarship of my education.

Finally, I am eternally grateful to my beloved parents and all my dearest family members for their enormously ever-willing support. Thanks are also extended to everyone who has contributed to the success of this dissertation.

CONTENTS

	page
Abstract (Thai).....	iv
Abstract (English).....	v
Acknowledgements.....	vi
Contents.....	vii
List of Tables.....	ix
List of Figures.....	xi
List of Graphs.....	xiv
CHAPTER I. GENERAL INTRODUCTION	1
CHAPTER II. LITERATURE REVIEW.....	3
Carbofuran.....	3
Guppy <i>Poecilia reticulata</i> Peters.....	8
The reason of selecting <i>Poecilia reticulata</i> Peters as test organism.....	10
Aquatic toxicology.....	11
CHAPTER III. INVESTIGATION ACUTE TOXICITY OF CARBOFURAN ON GUPPY <i>Poecilia reticulata</i> Peters.....	16
Introduction.....	16
Materials and methods	16
Results.....	19
Discussion.....	21
Tables and Figures.....	24
CHAPTER IV. HISTOPATHOLOGY OF GUPPY <i>Poecilia reticulata</i> Peters AFTER SHORT-TERM EXPOSURE TO SUBLETHAL CONCENTRATIONS OF CARBOFURAN.....	26
Introduction.....	26
Materials and methods	27

	page
Results.....	30
Discussion.....	41
Tables, Figures and Graphs.....	46
CHAPTER V. HISTOPATHOLOGY OF GUPPY <i>Poecilia reticulata</i> Peters AFTER LONG-TERM EXPOSURE TO SUBLETHAL CONCENTRATION OF CARBOFURAN.....	79
Introduction.....	79
Materials and methods	80
Results.....	82
Discussion.....	90
Tables, Figures and Graphs.....	98
CHAPTER VI. REPRODUCTIVE TOXICITY EFFECTS OF CARBOFURAN EXPOSURE ON PREGNANT GUPPY <i>Poecilia reticulata</i> Peters.....	141
Introduction.....	141
Materials and methods	142
Results.....	144
Discussion.....	146
Tables, Figures and Graphs.....	150
CHAPTER VII. GENERAL DISCUSSION AND CONCLUSION.....	153
REFFERNCES.....	157
APPENDICES.....	182
Appendix A.....	183
Appendix B	184
Appendix C.....	185
Appendix D.....	186
Appendix E.....	187
VITAE.....	188

LIST OF TABLES

	page
Table 2-1	The chemical and physical properties of carbofuran..... 4
Table 3-1	Percent of mean mortality of guppy <i>Poecilia reticulata</i> Peters at various carbofuran concentrations in range finding test..... 24
Table 3-2	Percent of mean mortality of guppy <i>Poecilia reticulata</i> Peters at various carbofuran concentrations in definitive test..... 24
Table 3-3	The median lethal concentration (LC ₅₀) and 95% confidence interval (ppm) of carbofuran on guppy <i>Poecilia reticulata</i> Peters..... 24
Table 4-1	The histopathological lesions and severity of gill tissues of guppy <i>P. reticulata</i> in control, DMSO and treatment groups in natural water..... 46
Table 4-2	The histopathological lesions and severity of gill tissues of guppy <i>P. reticulata</i> in control, DMSO and treatment groups in tap water.... 47
Table 4-3	The histopathological lesions and severity of liver tissues of guppy <i>P. reticulata</i> in control, DMSO and treatment groups in natural water..... 48
Table 4-4	The histopathological lesions and severity of liver tissues of guppy <i>P. reticulata</i> in control, DMSO and treatment groups in tap water.... 49
Table 4-5	The histopathological lesions and severity of kidney tissues of guppy <i>P. reticulata</i> in control, DMSO and treatment groups in natural water..... 50
Table 4-6	The histopathological lesions and severity of kidney tissues of guppy <i>P. reticulata</i> in control, DMSO and treatment groups in tap water..... 51
Table 4-7	The histopathological lesions and severity of gill tissues of <i>P. reticulata</i> after 96 hours recovery period..... 52
Table 4-8	The histopathological lesions and severity of liver tissues of <i>P. reticulata</i> after 96 hours recovery period..... 52

Table 4-9	The histopathological lesions and severity of kidney tissues of <i>P. reticulata</i> after 96 hours recovery period.....	53
Table 5-1	Mean of body weight of guppy in control, DMSO solvent control and treatment groups in various month.....	98
Table 5-2	The degree of gill histopathological lesions of <i>P. reticulata</i> in control, DMSO control and treatment group after the exposure of 0.04 ppm carbofuran in various periods.....	98
Table 5-3	The degree of liver histopathological lesions of <i>P. reticulata</i> in control, DMSO control and treatment group after the exposure of 0.04 ppm carbofuran in various periods.....	99
Table 5-4	The degree of kidney histopathological lesions of <i>P. reticulata</i> in control, DMSO control and treatment group after the exposure of 0.04 ppm carbofuran in various periods.....	99
Table 5-5	The degree of testis histopathological lesions of <i>P. reticulata</i> in control, DMSO control and treatment group after the exposure of 0.04 ppm carbofuran in various periods.....	100
Table 5-6	The degree of ovary histopathological lesions of <i>P. reticulata</i> in control, DMSO control and treatment group after the exposure of 0.04 ppm carbofuran in various periods.....	100
Table 6-1	Mean number of offspring per female with different concentration	150
Table 6-2	Mean live birth index of offspring with different concentration.....	150
Table 6-3	Mean pregnant period of offspring with different concentration.....	150
Table 6-4	Mean pregnant period in each batch of offspring with different concentration.....	151

LIST OF FIGURES

	page
Figure 2-1 The chemical formula of carbamate.....	4
Figure 2-2 Female and male guppy <i>Poecilia reticulata</i> Peters.....	9
Figure 3-1 Probit transformed responses from probit analysis program of the guppy <i>Poecilia reticulata</i> Peters after exposed to carbofuran at 96 hours.....	25
Figure 4-1 Photomicrograph treated gill of guppy <i>Poecilia reticulata</i>	58
Figure 4-2 Photomicrograph treated liver of guppy <i>Poecilia reticulata</i>	60
Figure 4-3 Photomicrograph treated liver of guppy <i>Poecilia reticulata</i>	62
Figure 4-4 Photomicrograph treated kidney of guppy <i>Poecilia reticulata</i>	64
Figure 4-5 Photomicrograph treated liver of guppy <i>Poecilia reticulata</i> (Oil Red O).....	66
Figure 4-6 Photomicrograph treated liver of guppy <i>Poecilia reticulata</i> (PAS)....	68
Figure 4-7 Photomicrograph recovery gill of guppy <i>Poecilia reticulata</i>	70
Figure 4-8 Photomicrograph recovery liver of guppy <i>Poecilia reticulata</i>	72
Figure 4-9 Photomicrograph recovery kidney of guppy <i>Poecilia reticulata</i>	74
Figure 4-10 Photomicrograph recovery liver of guppy <i>Poecilia reticulata</i> (Oil Red O).....	76
Figure 4-11 Photomicrograph recovery liver of guppy <i>Poecilia reticulata</i> (PAS)..	78
Figure 5-1 Photomicrograph gill of guppy <i>Poecilia reticulata</i> at 1 month post-exposure.....	102
Figure 5-2 Photomicrograph gill of guppy <i>Poecilia reticulata</i> at 2 month post-exposure.....	104
Figure 5-3 Photomicrograph gill of guppy <i>Poecilia reticulata</i> at 3 month post-exposure.....	106
Figure 5-4 Photomicrograph gill of guppy <i>Poecilia reticulata</i> at 4 and 5 month post-exposure.....	108
Figure 5-5 Photomicrograph liver of guppy <i>Poecilia reticulata</i> at 1 month post-	

	page
exposure.....	110
Figure 5-6 Photomicrograph liver of guppy <i>Poecilia reticulata</i> at 2 month post-exposure.....	112
Figure 5-7 Photomicrograph liver of guppy <i>Poecilia reticulata</i> at 3 month post-exposure.....	114
Figure 5-8 Photomicrograph liver of guppy <i>Poecilia reticulata</i> at 4 month post-exposure.....	116
Figure 5-9 Photomicrograph liver of guppy <i>Poecilia reticulata</i> at 5 month post-exposure.....	118
Figure 5-10 Photomicrograph liver of guppy <i>Poecilia reticulata</i> (Oil Red O).....	120
Figure 5-11 Photomicrograph liver of guppy <i>Poecilia reticulata</i> (PAS).....	122
Figure 5-12 Photomicrograph kidney of guppy <i>Poecilia reticulata</i> at 1 month post-exposure.....	124
Figure 5-13 Photomicrograph kidney of guppy <i>Poecilia reticulata</i> at 2 month post-exposure.....	126
Figure 5-14 Photomicrograph kidney of guppy <i>Poecilia reticulata</i> at 3 month post-exposure.....	128
Figure 5-15 Photomicrograph kidney of guppy <i>Poecilia reticulata</i> at 4 month post-exposure.....	130
Figure 5-16 Photomicrograph kidney of guppy <i>Poecilia reticulata</i> at 5 month post-exposure.....	132
Figure 5-17 Photomicrograph testis of guppy <i>Poecilia reticulata</i> in control groups.....	134
Figure 5-18 Photomicrograph testis of guppy <i>Poecilia reticulata</i> at 1 to 5 month post-exposure.....	136
Figure 5-19 Photomicrograph ovary of guppy <i>Poecilia reticulata</i> in control group.....	138

Figure 5-20	Photomicrograph ovary of guppy <i>Poecilia reticulata</i> at 1 to 5 month post-exposure.....	140
Figure 6-1	The morphological abnormality of newborn guppy in treatment group at 0.05 ppm of carbofuran.....	151



ศูนย์วิทยทรัพยากร
จุฬาลงกรณ์มหาวิทยาลัย

LIST OF GRAPHS

	page
Graph 4-1 The mean of lipid accumulation in hepatocytes of <i>P. reticulata</i> in control, DMSO and treatment groups at 96 hours exposure period in liver tissue per 100 μm^2 of natural water at various concentrations....	53
Graph 4-2 The mean of lipid accumulation in hepatocytes of <i>P. reticulata</i> in control, DMSO and treatment groups at 96 hours exposure period in liver tissue per 100 μm^2 of tap water at various concentrations.....	54
Graph 4-3 The mean of lipid accumulation in hepatocytes of <i>P. reticulata</i> in control, DMSO and treatment groups at 96 hours recovery period in liver tissue per 100 μm^2 in natural water.....	54
Graph 4-4 The mean of lipid accumulation in hepatocytes of <i>P. reticulata</i> in control, DMSO and treatment groups in liver tissue per 100 μm^2 in natural water at exposure period and recovery period.....	55
Graph 4-5 The mean of lipid accumulation in hepatocytes of <i>P. reticulata</i> in control, DMSO and treatment groups at 96 hours recovery period in liver tissue per 100 μm^2 in tap water.....	55
Graph 4-6 The mean of lipid accumulation in hepatocytes of <i>P. reticulata</i> in control, DMSO and treatment groups in liver tissue per 100 μm^2 in tap water at exposure period and recovery period.....	56
Graph 4-7 The mean of lipid accumulation in hepatocytes of <i>P. reticulata</i> in control, DMSO and treatment groups at 96 hours exposure period in liver tissue per 100 μm^2 in natural water and tap water at various concentrations.....	56
Graph 5-1 Means of lipid accumulation in hepatocytes of <i>P. reticulata</i> in control, DMSO and treatment groups after exposure of 0.04 ppm carbofuran in various exposure periods.....	100

Graph 6-1 Means of survival index of *P. reticulata* in control, DMSO and treatment groups after exposure of 0.01 and 0.05 ppm carbofuran.... 152



ศูนย์วิทยทรัพยากร
จุฬาลงกรณ์มหาวิทยาลัย

CHAPTER I

GENERAL INTRODUCTION

Nowadays, pesticides play an important role in crop protection and maintain the quality of yields. Pesticide residues have been causing health hazard to human and non target organisms because they have been extensively applied on crops. The pesticide used in Thailand significantly increases both in term of quantity and variety (DOA, 2002). In 2007, Thailand imported pesticides in the amount of 116,322,789 Kg and its value was 15,026,321,438 Baht (DOA, 2007). One important insecticide in Thailand is carbofuran. It is usually applied in rice fields, fruit and vegetable crops throughout Thailand. In 2007, Thailand imported 4,405,328 Kg of carbofuran and its value was 147,321,469 Baht (DOA, 2007).

Carbofuran is a carbamate insecticide. It is classified in toxicity class 1b or highly toxic class (WHO, 1999). It has been used for control a broad spectrum of insect pests. Therefore, its residues are continuously contaminated in the environment especially aquatic system by leaching and runoff from agricultural lands (Nimmo, 1985; Jaffe, 1991). Fish inhabit in contaminated aquatic environment can be affected by carbofuran both directly via water and indirectly via their food. Although carbofuran is rapidly broken down in the environment, the continuous use, in high dose and high frequent treatment, can produce the adverse effects on aquatic animals especially on fish (Bender, 1969). These effects may not immediately kill living organisms, but it can decrease fitness and survival ability.

In order to understand the effects of carbofuran on fish, the determination of its biological effects is necessary. In the attempt to define and measure the effects of carbofuran on organisms, biomarkers have attracted a great deal of interest. The study

on biological responses of fish in terms of histology and histochemistry provide the information concerning with changes of the external environments. Histological technique is a useful tool for observation of structural and histopathological changes in target organs after exposure to the toxicants (Dietrich and Krieger, 2009).

From the previous studies, information about the effects of carbofuran on the histopathology is limited. Therefore, the histopathology of gill, liver, kidney and gonad are demonstrating the effects of carbofuran on fish. Anticipated benefits of this study is a basic knowledge about common histology of gill, liver, kidney and gonad of guppy *Poecilia reticulata* Peters. Besides, toxicological information about short-term and long-term exposure to carbofuran on gill, liver, kidney, gonad of guppy and reproductive indices of *Poecilia reticulata* Peters are investigated. Moreover, toxicological data of long-term exposure of carbofuran on guppy *Poecilia reticulata* Peters can be used to determine suitability and safety of carbofuran using.

Objectives

1. To determine the median lethal concentration (LC_{50}) of carbofuran on guppy *Poecilia reticulata* Peters at 96 hours
2. To study the basic histology of gill, liver, kidney and gonad of guppy *Poecilia reticulata* Peters
3. To study the histological and histochemical effects on guppy *Poecilia reticulata* Peters after short-term and long-term exposures to sublethal concentrations of carbofuran
4. To study the effects of carbofuran on some reproductive indices of guppy *Poecilia reticulata* Peters

The experimental protocols of these studies are conducted according to a guideline for animal care and use, and have been approved by Chulalongkorn University Animal Care and Use Committee (CU-ACUC Protocol Review No. 0923011).

CHAPTER II

LITERATURE REVIEW

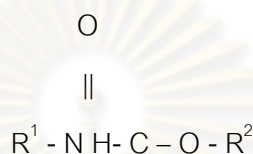
2.1 Carbofuran

The carbamates are mainly used in agriculture as insecticide, fungicide, herbicide, nematocide and sprout inhibitor. Thus, they are part of a large group of pesticides that have been developed, produced and used on a large scale. The chemical formula of carbamates is shown in Figure 2-1. Carbofuran is one of the most toxic carbamate insecticides. It is widely used because it can destroy unwanted pests at once (DOA, 2004). Carbofuran is classified in toxicity class 1b or highly toxic class (WHO, 1999). It is intensively applied in fruit and vegetable crops and rice fields throughout Thailand. Carbofuran is applied for the control of soil-dwelling, foliar-feeding insects and other insect pests such as corn rootworm, wireworms, boll weevils, mosquitoes, alfalfa weevils, aphids and white grubs (Trotter, Kent and Wong, 1991). Because of widespread use, its residues can contaminate in surface water (Willis and McDowell, 1982; Capel, Larson and Winterstein, 2001). Contaminated carbofuran was often found in agricultural products and environments and it could affect on non target organisms such as aquatic animals (Radka, 2003). In aquatic environments, carbofuran can be degraded within one to eight weeks in neutral and moderate alkaline water (Anton et al., 1993). The toxicity of carbofuran results in the inhibition of acetylcholinesterase (AChE), a key enzyme of the nervous system. The inhibition causes an accumulation of acetylcholine in synapses leading to the disruption of the nerve functions (Tucker and Thomson, 1987). Toxic signs observed are typical for cholinesterase inhibition including salivation, cramps, trembling and sedation. Moreover, nausea, vomiting, sweating, diarrhea, weakness, imbalance, blurring of vision, breathing

difficulty, increase blood pressure and incontinence are observed. Death may result at high doses from respiratory system failure (WHO, 2004).

2.1.1 General chemistry of carbofuran

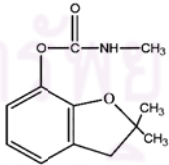
Carbofuran is a crystalline solid with limited solubility in water. The important physical and chemical properties of carbofuran are shown in Table 2-1.



where R¹ and R² are alkyl or aryl groups (U.S.EPA, 1995)

Figure 2-1 The chemical formula of carbamate

Table 2-1 The chemical and physical properties of carbofuran (U.S.EPA, 1995)

Property	Information
Common name	Carbofuran
Chemical name	2,3-dihydro-2,2-dimethyl-7-benzofuranyl methylcarbamate
Trade name	Furadan 4F or 3G, Curaterr, Bay 70143, Brifur, Crisfuran, D 1221, ENT 271 64, FMC 10242, NIA 10242, Pilarfuran, Kenofuran, Yaltox, Furacarb, Rampart
Chemical structure	
Chemical formulation	C ₁₂ H ₁₅ NO ₃
Molecular weight	221.3
Color/Form/Odor	White crystalline solid with slight phenolic odor
Melting point	153-154 °C
Vapor pressure	3.4 X 10 ⁻⁶ mm Hg at 25°C
Solubility	0.7 g/L of water at 25°C

2.1.2 Environmental fate of carbofuran

Air

Carbofuran has a low tendency to volatilize from water or moist soils (Deuel et al., 1979). Releases to the atmosphere occur during the usage of carbofuran to plants. Removal from the atmosphere can occur either by photolysis or sorption onto particles and deposition (EPA, 1991).

Soil

The half-life of carbofuran in soil is several days to over three months. The environmental fate of carbofuran depends on the organic content, moisture and pH of the soil (Miles, Tu and Harris, 1981; EPA, 1991).

Water

Carbofuran has limited water solubility but can migrate with water and can be found in ground water and runoff (Winston and Joan, 2000). Carbofuran phenol is the major metabolites of carbofuran by hydrolysis degradation in water (Yu et al., 1974; Seiber, Catahan and Barril, 1978; Brahma Prakash, Panda and Sethunathan 1987; Bailey et al., 1996; Talebi and Walker, 1993). Other metabolites are 3-hydroxy-7-phenolcarbofuran, carbofuran phenol, *N*-methylcarbamic acid via hydroxylation of the benzofuranyl moiety (Yu et al., 1974; Seiber, Catahan and Barril, 1978; Chiron et al., 1996). Half-life in paddy water and DI water at pH 7 is 240 hours and 864 hours, respectively (EPA, 2002).

2.1.3 Metabolism and Pharmacokinetics

Carbofuran can be absorbed by dermal uptake and digestive tract. After that, it is distributed to all organs such as stomach, intestine, liver and blood (Ahdaya, Monroe and Guthrie, 1981; Ahdaya and Guthrie, 1982; Shah, Monroe and Guthrie, 1981). The main route of metabolism composes of oxidation of the benzylic carbon to 3-hydroxycarbofuran and then they can be hydrolyzed to 3-hydroxycarbofuran phenol and 3-ketofuran-7-phenol. Another pathway of metabolism is to hydrolyze carbofuran directly

to the carbofuran phenol (Metcalf et al., 1968; Dorough, 1968; Dorough 1983 and U.S.EPA, 1990). After that, it was rapidly eliminated by exhaled breath, urine and feces. The concentration of excretion by feces was about half of the administered concentration. Although carbofuran are quickly hydrolyzed in mammals, becoming inactive, but it is very slowly in fish (Areechon and Plumb, 1990).

2.1.4 Contaminated carbofuran in environment

Resulting from intensive usage, carbofuran residues were found in water, soil and crop products all over Thailand (Anat and Paul, 2000). Water, soil and agricultural products along the main rivers in Thailand were contaminated by carbofuran at the level of 0.01 to 1.37 ppb, 0.045 to 8.41 ppm and 0.03 to 2.28 ppm, respectively (Pollution Control Department, 1997). Natural water resources along the rivers and canals in various agricultural areas were found contaminated with carbofuran residues (Chumraskul, Srira and Lertveerasirikul, 1995). Water resources from Fang and Chaiprakarn District, Chiangmai Province found range of carbofuran residues from 0.027 to 0.128 ppm (DOA, 2004).

2.1.5 Toxicology of carbofuran

Acute toxicity

Acute toxicity of carbofuran was evaluated in several animals that showed high toxicity (WHO, 1999). The LC_{50} was 0.38 ppm in rainbow trout, 0.8-0.9 ppm in climbing perch, 0.8 ppm in bluegill, 0.16 ppm in *Cyprinus carpio*, 0.8 ppm in Nile tilapia and 0.2 ppm in snake-head catfish (EPA, 2002).

Subchronic and chronic toxicity

Neurotoxicity

Carbofuran impairs the function of nervous system by synaptic poisons. In general, acetylcholine (ACh), a neurotransmitter, is released from the pre-synapse and then binds to receptor at post-synapse. The binding leads to a depolarization of post-

synaptic membrane. After that, ACh is hydrolyzed by acetylcholinesterase (AChE) to cholin and acetate and nerve impulse is terminated. If carbofuran binds to AChE and prevent this enzyme from working, the stimulation of nerve will occur continuously (EPA, 2002). Many researchers reported the neurotoxicity of carbofuran on small mammals and fish (Monreno et al., 2010; Scholz et al., 2006; Bretaud, Toutant and Saglio, 2000; Dembele, Haubruge and Gaspar, 2000). Carbofuran can induce the decrease of dendritic lengths and spine density as well as the alterations in morphology of hippocampal neurons (Gupta et al., 2007). It can produce neurotoxic effects by increasing lipid peroxidation, altering lipid composition and activity of membrane bound enzymes (Kamboj, Kiran, and Sandhir, 2006a; Kamboj Kiran, and Sandhir, 2006b). Moreover, carbofuran was reported to increase the norepinephrine and dopamine level in telencephalic hemispheres and hypothalamus of goldfish (Bretaud et al., 2002).

Developmental and reproductive toxicity

Carbofuran affected on mesenchymal stem cell differentiation capacity by inhibiting osteogenic differentiation (Hoogduijn, Rakonczay and Genever, 2006). Carbofuran was reported to decrease the number of developing follicles and corpora lutea while increase the atretic follicles (Baligar and Kaliwal, 2004). Moreover, it was reported to reduce 17β -estradiol content and ovarian vitellogenin levels in fish. These results suggested that carbofuran acted as an antiestrogenic endocrine-disrupting agent in fish (Chatterjee, Kumar and Ghosh, 2001). Moreover, after exposing to carbofuran in water it was found that the fetal toxicity and visceral and skeletal abnormality (IRCD, 1981; Courtney et al., 1989). In addition, it decreased the amount of sperm in rats (Yousef et al., 1995; Pant et al., 1997).

Genetic toxicity and metabolism toxicity

Carbofuran and its metabolites were reported as potential mutagens on mice (Zhou, Liu and Lu, 2005). Total adenine nucleotides and total creatine compounds markedly declined in rats after exposed to carbofuran (Gupta, et al., 2007). Carbofuran

decreased Ca^{2+} ATPase activity with a concomitant increase in K^+ induced Ca^{2+} uptake through voltage operated calcium channels in rat (Kamboj and Sandhir, 2007). The total protein in liver and muscular tissues decreased while ammonia and the activity of alanine aminotransaminase, aspartate aminotransaminase and glutamate dehydrogenase were increased in *Clarias batrachus* exposed to carbofuran (Begum, 2004).

Blood toxicity and behavior toxicity

The erythrocyte count, hemoglobin content and hematocrit were decreased while the leukocyte count, mean cell volume and mean cell hemoglobin were increased after exposed to carbofuran (Adhikari et al., 2004). The effects of carbofuran in goldfish induced the increase in sheltering, burst swimming and nipping behavior and decrease in attraction to the food extracts (Saglio, Trijasse and Azam, 1996).

2.2 Guppy *Poecilia reticulata* Peters

2.2.1 Taxonomy

The guppy, *Poecilia reticulata*, is viviparous fish belonging to the family Poeciliidae, genus *Poecilia*. Guppy has many synonyms including *Poecilia reticulates*, *Lebistes poeciloides*, *Girardinus guppii* and *Acanthophaelus guppii*. Robert John Lechmere Guppy discovered this tiny fish in Trinidad in 1866. The fish was named *Girardinus guppii* in his honour by Albert C.L.G. Gunther later that year. However, the fish had previously been described by Wilhelm Peters in 1859 on material collected from South America. Although *Girardinus guppii* is now considered a junior synonym of *Poecilia reticulata* Peters and the common name "guppy" remains (Arthington and Lloyd, 1989).




Figure 2-2 Female (top) and male (bottom) guppy *Poecilia reticulata* Peters
(Riehl and Baensch, 1994)

2.2.2 Morphology

The dorsal fin origin of female guppy is directly over the anal fin origin. In male guppy, the dorsal fin origin is slightly behind anal fin origin. The lateral scales are ranged from 22 to 28 scales in both male and female guppy. They are ranges in color from the drab green to bright orange, red, blue and yellow. Male has longer and more colorful fin than female which tend to be dull colored. However, the most definitive feature in male is the gonopodium, a stick-like modified anal fin, instead of the normal rounded anal fin as female (Diethrich and Krieger, 2009).

2.2.3 Size and longevity

In general, the male guppy is smaller in size than female guppy. Male is 2.5 ± 0.5 cm in total length, whereas the female is up to 3.0 ± 0.5 cm in total length. The life span of guppy is ranged from 2 to 3 years (Eldredge, 2000).

2.2.4 Diet

Guppy is omnivorous fish. It feeds on a wide variety of foods such as zooplankton, small aquatic insect larvae, and other fish's eggs (Arthington and Lloyd, 1989; Eldredge, 2000).

2.2.5 Habitat

Guppy is a tropical fish and inhabits fresh and brackish waters. Guppy can survive in a wide range of habitats and different types of water bodies. It can be found in ponds, canals and ditches with muddy water to pristine mountain streams. Guppy has a wide salinity range and requires warm, slow flowing and vegetated water for survival. However, they cannot survive in cold water, below 10°C (Arthington and Lloyd, 1989; Eldredge, 2000).

2.2.6 Breeding

Guppy is livebearers or viviparous fish. It has a polygamous mating with internal fertilization. The female can produce up to 6 batches of offspring at a time of fertilization. The gestation period of guppy is 22 to 30 days, with an average of 28 days. She hangs out near hiding places for the new offspring at birthing time, often sitting on the bottom near some plants. The female gives birth to offspring in broods of 7 to 12 fish at a time. They breed throughout the year about four weeks interval after maturity (Riehl and Baensch, 1994).

2.3 The reason for selecting *Poecilia reticulata* Peters as a test organism

Guppy is selected as a biological model in this study because of several reasons. They are widely available in Thailand and they are small fish so it is more convenient to maintain, culture and breed in laboratory. Additionally, guppy is a viviparous fish with a short reproductive period (Constanz, 1989; Houde, 1997; Casto et al., 2004). These reasons make is fish an important model for the study of pregnancy, fertility, viability and survival of offspring. It is a year-round breeder that suitable for reproductive study. Guppy is used in a variety of studies including behaviour, life evolution, water quality, genetic and ecotoxicology. Moreover, guppy is used for the study about the toxicology and endocrine disruption (Araujo et al., 2006; Dietrich and Krieger, 2009). Guppy is also very useful for the study of environmental pollution problem (Wester et al., 2002; Camilo et al., 2008). Guppy *Poecilia reticulata* used in this

study was obtained from the laboratory stock of Department of Biology, Faculty of Science, Chulalongkorn University.

2.4 Aquatic toxicology

2.4.1 Aquatic system

An aquatic system is complex and diverse with many different biotic and abiotic components. Therefore, it is difficult to understand the response of the system to chemicals unless the relationships between components are well defined. Moreover, similar ecosystems are not necessarily affected in the same response by contamination of the same chemical (Rand and Petrocelli, 1985). Aquatic toxicology is the qualitative and quantitative studies of the adverse or toxic effects of toxicants on aquatic organism (Rand and Petrocelli, 1985). Toxic effects may include lethality and sublethal effects such as the effects on growth, reproduction, pathology, biochemistry, physiology and behavior. Scientific criteria has been used for monitoring the effects such as the lesions and their severity. In general, an acute toxicity concerns a short period of time compare to the life cycle of an organism. The test usually covers within 4 days and the mortality is chosen as the end point. On the other hand, exposure time of chronic or subchronic toxicity study is a month to several months. It is less than a complete reproductive life cycle and covers the sensitive early stages of development of the organisms (Sprague, Schreck and Moyle, 1990). The crucial concept of toxicology is “no substance is completely safe and no substance is completely harmful” (Rand and Peteocelli, 1985). The factor that determines whether a chemical agent is potentially harmful or safe is the relationship between the concentration and the duration of exposure (Rand and Peteocelli, 1985).

The results of toxicity test are used to determine the compliance with permit toxicity limits. Furthermore, this data can use in the development and implementation of toxicity reduction plans and in risk assessment to wildlife and human. The data of toxicity test may be assembled to derive water quality criteria, to monitor the toxicity and

to evaluate the quality of surface water (Sprague, Schreck and Moyle, 1990; U.S.EPA., 1991).

2.4.2 The effects of toxicants on fish organ

The histological effects of toxic substances in many fish species were documented especially in a past few decades. When the aquatic environments were contaminated with toxicants, the adverse effects on fish organs were concerned.

2.4.2.1 Histological alterations of gill

Gill of a fish is a multifunction organ with multifunction including respiration, ion-regulation, acid-base regulation and nitrogenous waste excretion. Gill has over 50 percent of total surface area on a fish body. The diffusion distance between water and blood is very short and the effectiveness of diffusive exchange is maximized by the countercurrent system. From this information, gill is not only the major site of uptake for most pollutants but it is the first and most important site of contact of toxicants (Wood, 2001). All functions of gill are essential for life therefore, interruption of fish gill function leads to death, whereas sublethal disturbances will chronically depress the fitness of fish (Schlenk and Benson, 2001).

The histological alterations of gill after the exposure to pesticides were reported. The *Jenynsia multidentata* exposed to endosulfan showed hypertrophy, aneurisms and lifting of the epithelium in the secondary lamellar (Ballesteros et al., 2007). *Cirrhinus mrigala* exposed to fenvalerate showed epithelial hyperplasia, epithelial necrosis, desquamation, lamellar fusion and epithelial lifting (Velmurugan et al., 2007). The fish gill from canals near contaminated rice fields showed hyperplasia, hypertrophy and club shaped deformities (Wijeyaratne and Pathiratne, 2006). *Gambusia affinis* exposed to malathion showed necrosis, edema, fusion of secondary lamellar, haemorrhage, disorganization and rupture in secondary lamellar (Cengiz and Unlu, 2003). *Anabas*

testudineus exposed to monocrotophos displayed degeneration, necrosis of epithelial cells and distortion of the secondary lamellar (Santhakuma, Balaji and Ramudu, 2001).

2.4.2.2 Histological alterations of liver

Liver is the largest internal organ and it is a target organ of toxicant deposits because there is large blood supply. Its function involves macrovasculature and metabolic capacity. Moreover, it involves assimilation of nutrients, production of bile, detoxification, biotransformation, hematopoiesis and red blood cell destruction (Hinton, Segner and Braunbeck, 2001). When liver is damaged, it can affect on internal homeostasis and survival of the organisms.

The hepatotoxicity was reported in fish exposed to many pesticides. After the exposure of cypermethrin, *Heteropneustes fossilis* showed necrosis and fibrosis of perivascular region in the liver (Joshi, Dharmalata and Sahu, 2007). The liver of fish collected from Rangsit Klong 7 showed hydropic swelling, hyaline granule accumulation, foci and diffuse necrosis (Yenchum, 2004). After the exposure of dimecron to *Gambusia affinis*, liver showed necrosis, pyknosis, vacuolation, blood vessel damage and accumulation of cytoplasmic granule (Sakthivel and Gaikwad, 2002). *Ctenopharyngodon idellus* liver exposed to fenvalerate showed foci and diffuse necrosis, vacuolar degeneration and blood congestion in sinusoid (Tilak and Yacobu, 2002). After the exposure of endosulfan on catfish *Heteropneustes fossilis*, the liver showed the decrease of glycogen content. The depletion in glycogen contents is greatly associated with cellular damage in hepatocytes (Rawat, Bais and Agrawal, 2002). The effects of thiodan on *Gambusia affinis* exhibited degeneration, hypertrophy, sinusoids enlargement and hemorrhage in the liver tissue (Cengiz, Unlü and Balci, 2001).

2.4.2.3 Histological alterations of kidney

Kidney is a primary organ for ion re-absorption and elimination of waste. The overall appearance of kidney from different groups of fish varies greatly from a rather

simple looking string to a firm well define kidney. The teleost kidney composes of two compartments including the anterior head and the posterior trunk kidney. The head kidney contains lymphoid and hematopoietic tissue. The trunk kidney contains nephrons (Larsen and Perkins, 2001).

Many reports about renal pathology in fish after pesticide exposure were documented. *Cirrhinus mrigala* exposed to fenvalerate showed necrosis of tubular epithelium, pyknosis in the hematopoietic tissue and narrowing of the tubular lumen (Velmurugan et al., 2007). *Dicentrarchus labrax* exposed to cadmium had tubular epithelial cells necrosis, dilatation of nuclear envelope and cytoplasmic vacuolization (Giari et al., 2007). *Hypophthalmichthys molitrix* exposed to nickel showed necrosis of tubular cells, contraction of glomerulus and hyperplasia (Athikesavan et al., 2006). Nile Tilapia exposed to 30 degree distills water had glomerular shrinkage, hydropic swelling in renal tubular cells and sinusoid dilation (Pumchae, 2004). *Lates calcarifer* exposed to cadmium showed hydropic swelling, vacuolation and numerous dark granules accumulation in renal tubules (Thophon et al., 2003). *Channa punctatus* exposed to Elsan displayed foci necrosis, tubular epithelial degeneration, karyolysis and dilation or shrinkage of Bowman's capsule and glomerulus (Banerjee and Bhattachrya, 1994).

2.4.2.4 Histological alterations of reproductive organs

Reproductive toxicity is the occurrence of adverse effects on male and female reproductive system resulted from the exposure to chemicals or toxicants (Eaton, and Gilbert, 2008). The three part system of reproductive toxicity test adopted by the FDA in 1996 (Palmer, 1997) is basically consisted of;

1. An investigation of effects on fertility and general reproductive performance.
2. An investigation of effects during pregnancy and in particular the potency to cause malfunction of the offspring.
3. An investigation of effects during late pregnancy and lactation, in particular the potency to cause damage during late fetal and early neonatal development.

Many pesticides induced the reproductive toxicity in fish. Pituitary (gonadotropin secreting cells-GTH) and testis of *Glossogobius giuris* (HAM) exposed to fenthion showed reduction in number of sperms and degranulation of GTH cells (Zutshi, 2005). The bluegill *Lepomis macrochirus* testis exposed to diazinon showed abnormality of sperm and testis (Dutta and Meijer, 2003a). The effects of diazinon on the ovaries of bluegill *Lepomis macrochirus* induced atretic oocyte and retraction in oocyte (Dutta and Meijer, 2003b). Histological changes in ovarian tissue of Nile tilapia exposed to neem extract showed hyperbasophilic of oocyte and abnormal in shape of oocyte (Srijunngam, 1998).

Carbofuran was not only toxic to animals but could also affect on human (Satar et al., 2005; Titlic, Josipovic-Jelic and Punda, 2008). The main adverse health effects after exposure to carbofuran were difficulty in breathing, headaches and neurological or psychological effects (EPA, 2006). Moreover, carbofuran induced the risks of Hodgkin's lymphoma, colon and lung cancers (Bacigalupo, Meroni and Longhi, 2006; EPA, 2006; Zeljezic, et al., 2008; Zeljezic et al., 2007; Andreotti et al., 2010). Carbofuran and its major metabolites could cross the placental barrier and produce serious effects on the maternal-placental-fetal unit (Gupta, 1994; Barr et al., 2010). A case of carbamate pesticide poisoning in a pregnant woman was reported. The mother recovered from the poisoning in a hospital but necrosis of the fetus was found. Chemical analysis of carbofuran in the liver, brain, and kidney tissue of the fetus revealed carbofuran in concentrations comparable with the mother's blood (Klys, 1989). In addition, women who were reported to have agrochemical exposure during pregnancy showed risk of gestational diabetes mellitus (GDM) in association with ever-use of carbofuran (Saldana et al., 2007). Carbofuran caused one hundred seventy-six poisonings to death (Recena, Pires and Caldas, 2006). Moreover, it induced genotoxicity in somatic cells and derangement of hepatic and renal function in human (Naravaneni and Jamil, 2005; Khan, et al., 2010).

CHAPTER III

ACUTE TOXICITY OF CARBOFURAN ON GUPPY *Poecilia reticulata* Peters

3.1 INTRODUCTION

For understanding the effects of toxicants on aquatic animal, it is customary to use lethality as index. Acute aquatic toxicity test is to determine the concentration of the test material that produces a deleterious effect on a group of test organisms during a short-term exposure under controlled conditions (Parrish, 1985; Donald, 1992). Acute toxicity test is the first step toward understanding the toxic effects of chemicals in aquatic ecosystems. Moreover, the assessment of the lethal properties of chemicals is an integral part of the acute toxicity phase of the safety evaluation process (Parrish, 1985; Eaton and Gilbert, 2008). WHO (2009) classified carbofuran as highly hazardous (LD_{50} 5 to 50 mg/kg body weight) which determined by acute toxicity test. Carbofuran is highly toxic by inhalation and ingestion, and moderately toxic by dermal absorption (Baron, 1991). In environment, carbofuran is classified as highly toxic to aquatic animals (Johnson and Finley, 1980; Kidd and Jame, 1991; U.S.EPA, 1991; Collective SPA, 2002) and birds (Hill and Camardes, 1986; Howard, 1991; Smith, 1992). Ecotoxicological evaluations are required by chemical control regulation to classify the carbofuran with respect to their potential hazard to the environment (Vittozzi and Angelis, 1991). Nevertheless, the information on acute toxicity of carbofuran is very limited. Therefore, the objective of this study was to determine the LC_{50} value of carbofuran after 96 hours on guppy *Poecilia reticulata* Peters.

3.2 MATERIALS AND METHODS

The standard method for the acute static toxicity bioassay was carried out to determine the LC_{50} value and 95% confidence intervals of carbofuran after 96 hours

(ASTM, 1980; FAO No. 185, 1982). Static non-renewal system was used in this experiment.

3.2.1 Experimental animal

Guppies (average total length 1.1 ± 0.1 cm) at the age of 15 days post partum were maintained under laboratory conditions. The fish were acclimatized in 12-L glass aquarium in dechlorinated tap water with aeration prior to the experiment. During the experiment, they were maintained in 27-30°C water, on 12h light: 12h dark photoperiod, and were fed twice daily with commercial guppy food (See-All Aquariums Co., Ltd.). The fish were fasted for 24 hours prior to the experiment.

3.2.2 Experimental chemical

The commercial grade of carbofuran, (Furadan 3G), contains 3% (w/w) active ingredient was used in this experiment. Carbofuran was dissolved in 1% dimethylsulphoxide (DMSO) before diluting into water to obtain the final concentration. The solvent control group was contained DMSO at a concentration of 0.05 ppm which was the maximum concentration used to dissolve the test chemicals.

3.2.3 Experimental design

Acute toxicity test comprising two protocols, range finding test and definitive test, are presented below.

3.2.3.1 Range finding test

The range finding test was conducted in 2-L glass aquaria containing different concentrations of carbofuran. Five glass aquaria were filled with the test solution at 0.001, 0.01, 0.1, 1 and 5 ppm. The control group was the group of guppy that exposed to filtered tap water and the solvent control group was exposed to DMSO solution at a concentration of 0.05 ppm. Five fish were used in each aquarium and triplicate aquaria were designated for each concentration. Mortality of fish was observed and recorded every 24 hours throughout the test period of 96 hours. The fish was considered dead

when gill opercula and body movement ceased. Then the dead fish were removed immediately.

3.2.3.2 Definitive test

Based on range finding test, a definitive test was carried out with concentrations of 0.050, 0.075, 0.10, 0.2, 0.4, 0.6 and 0.8 ppm of carbofuran. Five fish were used for each aquarium and three replicates were designated for each concentration. The test protocol was as described in the range finding test. In addition, the behavioral responses of guppy in each concentration were observed after exposure to carbofuran every 24 hours during acute toxicity test.

3.2.3.3 Analysis for LC₅₀ values

The acute toxicity of carbofuran in fish was determined using a logarithmic probability regression analysis (probit analysis). This analytical technique was commonly used for prediction of dose response relationship and 95% confidence intervals in the test data (Finney, 1971; Fisher, Galinat and Brown, 1999). The median lethal concentration (LC₅₀) values and its corresponding 95% confidence interval of each exposure time were computed by probit analysis using SPSS for Windows version 17.0 (Chicago, IL).

3.2.4 Determination of application factor (AF)

The maximum acceptable toxicant concentration (MATC) was hypothetical concentration and it was in range of no observe effect concentration (NOEC) and the lowest observe effect concentration (LOEC) (Petrocelli, 1985; Sprague, Schreck and Moyle, 1990). The range of NOEC and LOEC were selected from the previous calculation of LC₅₀ value in definitive test. The test concentration in long-term study was estimated using the application factor (AF) concept. The application factor was computed as presented below.

$$AF = MATC / LC_{50} \text{ at 96 hours}$$

The long-term concentration of carbofuran was determined at the level lower than the MATC by multiplying the MATC with AF (Petrocelli, 1985).

3.3 RESULTS

3.3.1 Range finding test

The mortal fish was not observed in control, DMSO solvent control and treatment groups at concentration of 0.001 and 0.01 ppm. In contrast, 100% mortality was found after the exposure of 5 ppm carbofuran within 24 hours. This preliminary result from the range finding test indicated that the concentration of 5 ppm carbofuran was the lethal concentration for guppy, yielding 100% mortality in this fish species. On the other hand, the concentration of 0.1 ppm carbofuran was the maximum nonlethal concentration, yielding 0% mortality in guppy. The percentage of mortality in each concentration is presented in Table 3-1.

3.3.2 Definitive test

The fish mortality was not observed in control, DMSO solvent control and treatment groups at concentration of 0.05 ppm. At concentration of 0.8 ppm carbofuran, all fish were found dead within 24 hours. From the result, carbofuran at the concentration of 0.8 ppm was the lethal concentration, yielding 100% mortality in guppy while the concentration of 0.05 ppm was NOEC and 0.075 ppm was LOEC. The maximum acceptable toxicant concentration (MATC) was estimated as a median value between NOEC and LOEC. Therefore, MATC in this study was 0.0625 ppm. The percentage of mortality observed in 96 hours at 0.050, 0.075, 0.10, 0.20, 0.40, 0.60 and 0.80 ppm were 0, 13.33, 60, 100, 100, 100 and 100, respectively (Table 3-2).

3.3.3 Analysis for LC_{50} values

The median lethal concentration (LC_{50}) of carbofuran to guppy *Poecilia reticulata*

Peters at 96 hours of exposure was determined at 0.1 ppm (Table 3.4 and Figure 3.1). The 95% confidence interval was between 0.08 and 0.15 ppm. In addition, the LC₅₀ values were 1.37, 1.08 and 0.88 ppm at the exposure period of 24, 48, and 72 hours, respectively. The LC₅₀ value and its 95% confidence intervals for guppy at various exposure times are shown in Table 3-3.

3.3.4 Determination of application factor (AF)

The MATC was 0.0625 ppm. The test concentration was estimated using the application factor (AF) concept. Base on this value, the application factor was computed as shown below.

$$\begin{aligned} \text{AF} &= \text{MATC} / \text{LC}_{50} \text{ at 96 hours} \\ \text{AF} &= 0.0625 / 0.10 \\ \text{AF} &= 0.625 \end{aligned}$$

From the AF, the sublethal concentration of the solution used for long-term test was determined at AF x MATC. Thus, the concentration of solution for long-term exposure was 0.04 ppm or 40 ppb.

3.3.5 Behavioral response

The observations of behavioral responses of guppy were conducted every 24 hours during the acute toxicity test. The guppy in control and DMSO solvent control groups showed normal behavior during the test period. The changes of behavioral responses were noticed for the first time after exposure to carbofuran for half an hour. At concentration of 0.05 ppm, swimming responses were increased for the first time, after that they were less general activity, loss of equilibrium and erratic swimming. In 0.075 ppm treatment group the guppies showed less general activity and loss of equilibrium. At 0.10 ppm treatment group, the guppies stayed motionless close to the water surface and later fell to bottom. After that, they showed spiral movement and died. At high concentration, 0.2 to 0.8 ppm treatment groups, the guppies swam in less of equilibrium,

hanging vertically in the water. Rapid gill movement, erratic swimming and spiral movement were observed. After long period of motionless, the guppy laid down on the bottom of aquarium and died.

3.4 DISCUSSIONS

In aquatic environment, carbofuran acute toxicity in fish was resulted from brain acetylcholinesterase inhibition because of the high volume usage in agriculture. The AChE inhibition in fish commonly occurred following heavy rain in agricultural areas when the insecticides and their residues were contaminated (Leblanc and Buchwalter, 2010). The advantage of acute toxicity information is a quantitative LC_{50} value that can be used to compare with other substances. Moreover, it can provide dose ranging guidance for other studies (Parrish, 1985; Hodgson, 2010). In this study, the commercial grade of carbofuran, Furadan 3G, was used for investigation of acute toxicity on guppy *Poecilia reticulata* Peters. The LC_{50} value at 96 hours of carbofuran on 15 days post partum guppy was 0.1 ppm and 95% confidence interval was between 0.08 and 0.15 ppm. Therefore, the toxicity of commercial carbofuran was determined as highly toxic to this fish (Hunn, Multer and DeFelice, 1993). The toxicity of carbofuran to guppy increased with increasing carbofuran concentration and duration of exposure time. In other studies, the technical grade of carbofuran was highly toxic to guppy and the LC_{50} value of carbofuran was reported between 0.1 and 0.5 ppm in one year old guppy (Radka, 2003) whereas the LC_{50} value in adult guppy was reported that 90 ppb (Vassanthi, Baskaran and Palanichamy, 1990). Water resources from Chiangmai Province found carbofuran residues at level 0.027 to 0.128 ppm (DOA, 2004) that higher than LC_{50} in this experiment. This concentration may kill guppy and other fish in environment such as *Mystus vittatus*, *Notopterus notopterus*, *Tilapia nilotica* that the LC_{50} value of carbofuran was between 0.09 and 0.2 ppm (Eisler, 1985).

Several reports showed that carbofuran was highly toxic to other fish. The LC_{50} values of carbofuran were reported in many fish species for example in rainbow trout at

150 ppb, in bluegill at 80 ppb, in goldfish at 1 to 100 ppb and in mosquito fish at 0.10 to 0.76 ppm (Saglio, Trijasse and Azam, 1996). Besides, the LC_{50} values after 72 to 96 hours exposure ranged from 130 to 1,420 ppb in yellow perch (*Perca flavescens*), green sunfish (*Lepomis cyanellus*) and lake trout (*Salvelinus namaycush*), the most sensitive species (Eisler, 1985) while channel catfish and fathead minnow (*Pimephales promelas*) were the most resistant species for carbofuran toxicity (Eisler, 1985). Nevertheless, carbofuran showed moderate toxicity in some fish. The LC_{50} value in adult snake head catfish was 6 ppm (Gopal and Ram, 1995), in adult carp *Cyprinus carpio communis* was ranged between 1 and 20 ppm (Pawar, 1994), in climbing perch *Anabas testudineus* was 1.6 to 1.7 ppm (Bakthavathsalam and Reddy, 1982) and in *Labeo rohita* was 4.8 ppm (Kulshrestha, Arora and Sharma, 1986). The lethal toxicity of carbofuran on fish depended on the difference of experimental animal species, the duration, intensity of exposure and water quality. Furthermore, the lethal toxicity also depended on the susceptibility of the organisms, which were impacted by age, sex, fitness and genetic variation. The toxicity testing methods directly on fish will be very useful in assessing possible ecological risk of these insecticides.

The general behavioral responses of guppy after the exposure to carbofuran were that the fish increased their swimming activity and burst swimming. After that, the fish lost their balance, decreased swimming and laid down on the bottom of aquarium. Moreover, they increased respiration and died with the body twist. Carbofuran disturbed the normal behavior of the fish because it is a AChE inhibitor (Scott and Sloman, 2004). It resulted accumulation ACh in nerve junction and led to continuous stimulation nerve impulse. In other experiments, exposure to carbaryl (carbamate insecticides) caused a reduction in brain AChE activity and this decrease was positive correlated with decrease swimming behavior of rainbow trout (Beauvias et al., 2001). In addition, behavioral changes due to carbofuran exposure in this experiment were similar to other AChE inhibitor insecticides (Brewer et al., 2001; Rukiya et al., 2003; Baser et al., 2003; Mehmet, Ali and Kazim, 2004; Jarrad, Delanney and Kennedy, 2004).

3.5 CONCLUSIONS

Carbofuran has been widely employed in agriculture. The result from this study shows that It is highly toxic on non target organisms in the aquatic environment. The test of acute toxicity with commercial carbofuran confirmed the high toxicity of the chemical on aquatic animals. LC_{50} value at 96 hours exposure to carbofuran on guppy *Poecilia reticulata* Peters at 15 days post partum was 0.10 ppm and 95% confidence interval was between 0.08 and 0.15 ppm. It indicated that carbofuran was highly toxic to guppy. Carbofuran affected on behaviors of guppy after exposure to 0.05 to 0.80 ppm. Guppy was loss the general activity, loss of equilibrium, spiral movement, increased respiration and death. The acute toxicity of carbofuran on guppy depended on the exposure time and intensity of exposure. The toxicity testing methods directly on fish will be very useful in assessing possible ecological risk of these insecticides.



ศูนย์วิทยทรัพยากร
จุฬาลงกรณ์มหาวิทยาลัย

TABLES AND FIGURES

Table 3-1 Percentage of mean mortality of guppy *Poecilia reticulata* Peters from probit analysis at various carbofuran concentrations in range finding test (n=15)

Exposure time	Mean mortality (%) at carbofuran concentration (ppm)						
	0.001	0.01	0.1	1	5	control	DMSO
24-hour	0.00	0.00	0.00	66.67	100.00	0.00	0.00
48-hour	0.00	0.00	13.33	73.33	100.00	0.00	0.00
72-hour	0.00	0.00	33.33	86.67	100.00	0.00	0.00
96-hour	0.00	0.00	66.67	100.00	100.00	0.00	0.00

Table 3-2 Percentage of mean mortality of guppy *Poecilia reticulata* Peters from probit analysis at various carbofuran concentrations in definitive test (n=15)

Exposure time	Mean mortality (%) at carbofuran concentration (ppm)								
	0.05	0.075	0.10	0.2	0.4	0.6	0.8	control	DMSO
24-hour	0.00	0.00	13.33	33.33	66.67	80.00	100.00	0.00	0.00
48-hour	0.00	0.00	20.00	66.67	80.00	100.00	100.00	0.00	0.00
72-hour	0.00	6.67	33.33	80.00	100.00	100.00	100.00	0.00	0.00
96-hour	0.00	13.33	60.00	100.00	100.00	100.00	100.00	0.00	0.00

Table 3-3 The median lethal concentration (LC_{50}) and 95% confidence interval (ppm) of carbofuran on guppy *Poecilia reticulata* Peters from probit analysis program (n=15)

Exposure time	LC_{50} ppm	95% confidence intervals		R^2
		Lower	Upper	
24-hour	1.37	0.69	2.75	0.96
48-hour	1.08	0.59	1.91	0.94
72-hour	0.88	0.40	1.89	0.80
96-hour	0.10	0.08	0.15	0.95

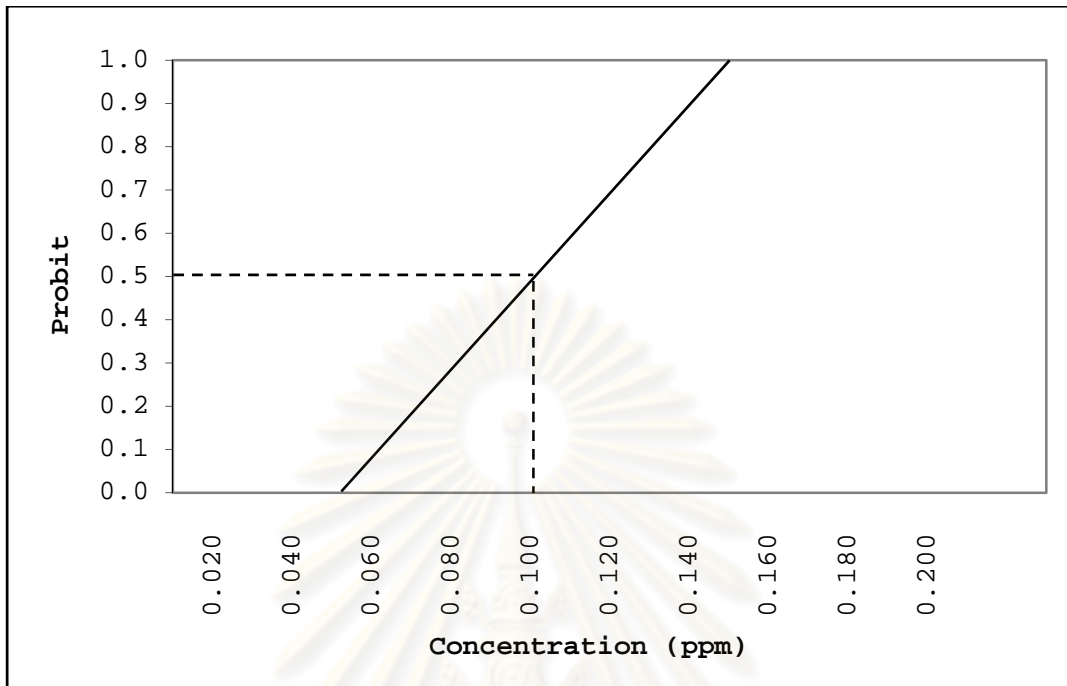


Figure 3-1 Probit transformed responses from probit analysis program of the guppy *Poecilia reticulata* Peters after exposed to carbofuran at 96 hours (SPSS version 17.0).

ศูนย์วิทยทรัพยากร
จุฬาลงกรณ์มหาวิทยาลัย

CHAPTER IV

HISTOPATHOLOGY OF GUPPY *Poecilia reticulata* Peters AFTER SHORT-TERM EXPOSURE TO SUBLETHAL CONCENTRATIONS OF CARBOFURAN

4.1 INTRODUCTION

The sublethal concentration of carbofuran may not produce death but they may produce the effects on the fitness of an organism. Many sublethal effects do not persist therefore, it commonly returns to normal conditions (EPA, 2002). Although carbofuran can be rapidly eliminated in mammals, fish are an exception because they seem to slowly excrete of carbofuran residuals (Areechon and Plumb, 1990). Therefore, fish are among the group of non-target aquatic organisms. According to Crepeau and Kuivila (2000) the continuous presence of carbofuran in water channel and river may cause severe sublethal effects to fish. Disturbance of living organisms at the cellular levels of biological organization by carbofuran can lead to cell injury, resulting in degeneration and malfunction of target organs (Tucker and Thomson, 1987). The histopathological biomarkers are proven to use as an indicator of toxicity of toxicants on organisms. Histological studies are the useful tool because the changes in histological structure may often significantly change the function of the tissues and organs. Furthermore, diagnosis and prediction of physiological consequences of sublethal contamination can be obtained through histopathology (Wester and Canton, 1991; Hinton, Segner and Braunbeck, 2001; Adams, 2002; Dietrich and Krieger, 2009).

Several studies were reported the effects of insecticide contamination on fish. Nevertheless, the available literatures revealed little information about histopathology of guppy after exposure to commercial grade carbofuran in short-tem period. Therefore, the objectives of this study were focused on evaluation the sublethal effects of

carbofuran on guppy *Poecilia reticulata* Peters in short-term exposure and their recovery. The target organs including the gills, liver and kidney were used for histopathological observation. The second purpose was to define which organs would be more sensitive in the fish. Reduction in the state of health of each individual would suggest the ecological consequences and interference in the food chain. Besides, this study investigated the effects of microbial biodegradation carbofuran on the level of toxic effects in the fish.

4.2 MATERIALS AND METHODS

4.2.1 *Experimental animal*

Guppy (average total length 1.1 ± 0.1 cm) at the age of 15 days post partum was maintained in laboratory conditions. The fish were acclimatized in 12-L glass aquarium in dechlorinated tap water with aeration prior to the experiment. During the experiment, they were maintained in 27-30°C water, on 12h light: 12h dark photoperiod, and were fed twice daily with commercial guppy food (See-All Aquariums Co., Ltd.). Fish were fasted for 24 hours prior to experiment.

4.2.2 *Experimental chemical*

The commercial grade carbofuran (Furadan 3G) contains 3% (w/w) active ingredient was used in the experiment. Carbofuran was dissolved in dimethylsulphoxide (DMSO) before diluting into water to obtain the final concentration. The solvent control was contained DMSO at a concentration of 5 ppb. Sublethal concentrations of carbofuran in this experiment were 0.005, 0.010, 0.025, 0.040 and 0.050 ppm. These concentrations were calculated from 1/20, 1/10, 1/4, 1/2.5 and 1/2 of the LC₅₀ value at 96 hours.

4.2.3 *Experimental design*

To compare, the water sources used in this experiment comprising two sources, natural water and tap water. The effects of microbial biodegradation of carbofuran on its

toxicity in guppy were investigated. The natural water was the insecticide free water that obtained from the pond in Muang District, Nakhon Nayok Province. This area settles far away from agricultural areas and has not been contaminated with insecticides. This pond contained many living organisms such as small fish, shrimp, mollusk and aquatic plant. The water samples were collected using glass bottle. The water from this area was tested by GT- pesticide test Kit that invented by Gobthong Thoophom. This kit was used for screen organophosphorous, carbamate and cholinesterase inhibitor pesticides for fifty three pesticides. From the GT-test kit, natural water from Nakhon Nayok Province was not detected the pesticides. After collecting, the water was rapidly transferred to laboratory and used in the experiment. Another source of water was tap water filtered through carbon-resin filter.

Both natural water and tap water were prepared into the final concentrations of carbofuran. The treatment aquarium was filled with carbofuran solution at a concentration of 0.005, 0.010, 0.025, 0.040 and 0.050 ppm while two control aquaria were filled with uncontaminated water and DMSO solution. Thirty guppies were placed in each aquarium and two replicates were made. Static non-renewal system was used in this experiment. After the exposure period of 6, 24, 48, 72 and 96 hours, five guppies were collected from each aquarium. After 96 hours of exposure period, other fish were transferred into carbofuran-free water for 96 hours for recovery study. After that, the guppies were collected and all fish samples were fixed in 10% neutral buffered formalin.

4.2.4 *Histological study*

The fish samples were prepared by standard paraffin technique (Humason, 1979). Following fixation, the tissues were dehydrated in graded alcohol solution of 70%, 90%, 95% and n-butanol, respectively. The tissues were cleared in xylene and embedded in paraffin. Then the tissue blocks were cut at 6 μm by rotary microtome and the sections were stained with Hematoxylin and Eosin (Gurr, 1969).

4.2.5 Histochemical study

For histochemistry, the freezing method was used for the detection of fatty and glycogen degeneration in liver tissues. The tissues were embedded in frozen medium (Tissue-Tek[®] OCT compound, Sakura). The samples were cut at 6 μm by cryostat microtome. After that, a group of sections were stained with PAS for studying the glycogen composition (Culling, 1963; Gurr, 1969). Another group of sections were stained with Oil Red O for studying the lipid composition (Culling, 1963; Gurr, 1969).

4.2.6 Data analysis

4.2.6.1 Histological analysis

Six guppies were randomly selected from each treatment and two control groups (3 fish/replicate). Approximately eight sections were observed from each fish for analysis. Therefore, forty eight sections in each group were observed for the histopathology under light microscope. The gill, liver and kidney were observed for the histological changes. Semi-quantitative scores of the severity of the histological changes were observed. According to Zodrow, Stegeman and Tanguay (2004) and Frias-Espericueta et al. (2008), the histopathological lesions were determined based on severity of changes compared to control sections. The degree of histological alteration observed in each group was scored according to the percentage of the histological damage area per the total tissue section area observed in the samples of each group (-, no histological damage; +, mild histological damage presented < 25% of the fields on the slides; ++, moderate histological damage presented 26%-50% of the fields on the slides; +++, strong histological damage presented 51%-75% of the fields on the slides and ++++, extreme histological damage presented 76% - 100% of the fields on the slides).

4.2.6.2 Histochemical analysis

Four guppies were randomly selected from each treatment and two control groups (2 fish/replicate). Approximately six sections were observed from each fish for

analysis. The sections were divided into two groups for glycogen and lipid composition study. Therefore, twelve sections were used for studying in each group. The lipid accumulation in liver tissues per 100 μm^2 was calculated by Image-Pro express version 4.5.1.3. The mean and standard error of lipid accumulation was calculated. Kruskal-Wallis One Way Analysis of Variance on Ranks followed by Dunn's Method at $P < 0.05$ was used to compare the differences between controls and treatment groups and also between control and recovery groups. Moreover, it was used for the comparison of the differences of lipid accumulation between natural water and tap water groups.

4.3 RESULTS

4.3.1 Gill

4.3.1.1 Control gill tissues

No histopathological changes were observed in the gill tissue of both control fish. Each gill arch contained numerous gill filaments or primary lamellae. The surface of primary lamellar was covered by stratified squamous epithelium. Two rows of secondary lamellar or respiratory lamellar ran perpendicular to each gill filament. The secondary lamellar surface was covered with a simple squamous epithelium for gas exchange. Blood space in secondary lamellar was supported by pillar cell. Generally, one erythrocyte was found inside each blood space of secondary lamellar. Moreover, there were the chloride cells at the base of the secondary lamellar. The control gill tissues are shown in Figures 4-1.

4.3.1.2 Treated gill tissues

4.3.1.2.1 Treated gill tissues in natural water contaminated with carbofuran

After 0.005 ppm treatment for 6 and 24 hours and 0.010 ppm for 6 hours, there were no found histopathological changes in gill tissues. The common changes after exposure to carbofuran displayed desquamation, the detachment of epithelial layer from secondary lamellar, edema, blood congestion in both primary and secondary lamellar in mild degree. Additionally, dilation of blood vessels and epithelium necrosis were found

in mild degree. After 0.010 ppm treatment for 96 hours, the shortening of secondary lamellar was observed in mild degree. Besides, after 0.025 ppm treatment for 48 to 72 hours, the gills showed hyperplasia in mild degree and after 96 hours the gills displayed hyperplasia in moderate degree. After 0.025 ppm treatment for 72 and 96 hours, the secondary lamellar fusions with neighbours were found in mild and moderate degree, respectively. Moreover, after 0.025 ppm treatment for 96 hours, the gills showed mild degree of hypertrophy of epithelial cell. The pillar cell system was rupture after exposure to 0.040 and 0.050 ppm carbofuran for 24 to 96 hours. The severity of gill lesions at 0.040 and 0.050 ppm were moderate degree with blood congestion in both primary and secondary lamellar, dilation of blood vessels, desquamation and epithelium necrosis. While the detachment of epithelium, edema, lamellar fusion and shortening were found in strong degree. The histological changes and the semi-quantitative scores of gill lesions after exposure to carbofuran contaminated natural water are shown in Table 4-1 and Figures 4-1.

4.3.1.2.2 Treated gill tissues in tap water contaminated with carbofuran

After 0.005 ppm treatment for 6 to 24 hours and 0.010 ppm for 6 hours there were no histopathological changes in brancial tissues. The general changes exhibited as the gill tissues in natural water. The desquamation, the detachment and edema of epithelial layer from secondary lamellar were noticed. The necrosis of secondary lamellar epithelium was found for first time in 0.005 ppm treatment at 96 hours. After 0.005 and 0.010 ppm treatment for 72 hours, blood congestion were shown in primary and secondary lamellar. In contrast, after 0.040 and 0.050 ppm treatment for 24 hours the gills showed the pillar cell system damage. In addition, epithelial hyperplasia, shortening and fusion of secondary lamellar were noticed. Moreover, the aneurism in secondary lamellar was shown. The histological changes and the semi-quantitative scores of gill lesions after exposure to carbofuran contaminated tap water are shown in Table 4-2 and Figures 4-1.

4.3.2 Liver

4.3.2.1 Control liver tissues

No abnormality was observed in the liver tissues of the fish in control and DMSO solvent control groups. The guppy liver was encapsulated with a thin layer of connective tissues. Two layers of polygonal hepatocytes arranged along the sinusoid in cord-like structure, arraying from the hepatic central vein. The hepatocyte contained a spherical basophilic nucleus with disperse chromatin and a single nucleolus. The cytoplasm of hepatocyte was slightly eosinophilic stained and found with small lipid droplets. The control liver tissue is shown in Figures 4-2.

4.3.2.2 Treated liver tissues

4.3.2.2.1 Treated liver tissues in natural water contaminated with carbofuran

After 0.005 and 0.010 ppm treatment for 6 to 48 hours there were no abnormal changes in liver tissues. Similarly, liver tissues in 0.025, 0.040 and 0.050 ppm treatment groups at 6 to 24 hours did not displayed the liver lesions also. The liver tissues of guppy exposed to carbofuran showed several pathological changes. The general lesions found in all concentrations were cellular swelling, amorphous nucleus shape and pyknosis of hepatic cells. After 0.005 and 0.010 ppm treatment for 96 hours, mild degrees of cellular swelling, amorphous nucleus shape and pyknotic nucleus were noticed. In addition, the moderate degree of hyperplasia or regeneration of hepatic cells were detected. After 0.010 ppm treatment for 48 hours, the livers showed fluid infiltration under the hepatic capsule layer. After 0.025 ppm treatment for 48 hours, liver tissues exhibited constriction of sinusoid and for 72 to 96 hours, the livers showed blood congestion in sinusoids and vein in mild degree. After 0.025 ppm treatment for 96 hours, hypertrophy and karyolysis of hepatic cells were detected in mild degree. After 0.040 ppm treatment for 96 hours the livers exhibited hepatic capsule rupture and cellular debris resulting from necrotic cells. At 0.040 and 0.050 ppm, the liver showed the same lesions as at 0.025 ppm group but they showed more severity in amorphous nucleus shape and pyknosis. Some liver areas were detected with the infiltration of a

few leukocytes. The histological alterations including hypertrophy and hyperplasia were observed in mild degree. Semi-quantitative scores of lesions of the liver after exposure to carbofuran contaminated natural water are shown in Table 4-3 and Figures 4-2 to 4-3.

4.3.2.2 Treated liver tissues in tap water contaminated with carbofuran

The liver tissues at 0.005 ppm treatment group for 72 hours showed cellular swelling and hyperplasia in mild degree. After 0.005 ppm and 0.010 ppm treatment group for 96 hours, the livers showed mild degree of pyknotic nucleus, cellular swelling, amorphous nucleus shape and moderate degree of hyperplasia. After 0.025 ppm treatment for 48 hours, constriction of sinusoidal capillaries was detected in mild degree. After 0.025 ppm treatment for 72 hours, the livers showed blood congestion in sinusoid and vein in mild degree. After 0.025 ppm treatment for 96 hours, the livers exhibited the damage of endothelial cell of blood vessels and karyolysis in mild degree. After 0.040 ppm treatment for 96 hours, the livers showed moderate degree of amorphous nucleus shape and pyknosis. The majority of liver lesions in 0.050 ppm treatment showed mild degree of severity but amorphous nucleus shape and pyknotic nucleus were observed in moderate degree. Semi-quantitative scores of the lesions of the liver after exposure to carbofuran contaminated tap water are shown in Table 4-4 and Figures 4-2 to 4-3.

4.3.3 Kidney

4.3.3.1 Control kidney tissues

No histopathological changes were observed in the kidney of both control groups. The kidney was composed of nephron unit and glomerulus. The renal tubule was composed of proximal tubule and distal tubule. The proximal tubule was lined by columnar cells with brush border of microvilli. The distal tubule was lined by cuboidal cells. The renal corpuscle consisted of Bowman's capsule, a double layered epithelial structure. The visceral layer covered the exposed surface of the glomerulus. The

parietal layer formed the boundary of the capsule. The glomerulus comprised of numerous capillaries. The control kidney tissues are shown in Figures 4-4.

4.3.3.2 Treated kidney tissues

4.3.3.2.1 Treated kidney tissues in natural water contaminated with carbofuran

After 0.005 ppm treatment for 96 hours, the kidneys showed mild degree of karyolysis of renal tubules. After 0.010 ppm treatment for 72 hours, mild degree of pyknotic nucleus was found. After 0.010 ppm treatment for 96 hours, Bowman's capsule rupture, cellular debris accumulation in lumen, karyolysis and pyknotic nucleus in renal tubular cell in mild degree were observed. Furthermore, after 0.025 ppm treatment for 96 hours, glomerular shrinkage was found resulting in empty Bowman's space. Additionally, hypertrophy, hyaline droplets accumulation, hydropic swelling and cellular debris accumulation in lumen were also observed in a few areas. Semi-quantitative scores of kidney lesions after exposure to carbofuran contaminated natural water are shown in Table 4-5 and Figures 4-4.

4.3.3.2.2 Treated kidney tissues in tap water contaminated with carbofuran

After 0.005 ppm treatment for 96 hours, the kidneys showed mild degree of karyolysis. After 0.010 ppm treatment for 72 hours, a mild degree of pyknotic nucleus was noticed. After 0.010 ppm treatment for 96 hours, Bowman's capsule rupture, karyolysis and pyknosis were observed in mild degree. Hyaline droplets accumulation was also observed in a few areas after exposure to 0.050 ppm of carbofuran for 96 hours. Moreover, the moderate degree of pyknotic nucleus was shown at 0.050 ppm treatment group at 72 and 96 hours. Some tubules were dilated, hydropic swelling and cellular debris accumulation were found in lumen. Semi-quantitative score of kidney lesions after exposure to carbofuran contaminated tap water are shown in Table 4-6 and Figures 4-4.

4.3.4 Histochemical alteration of fish liver

4.3.4.1 Control liver tissues

From control and DMSO solvent control liver, the Oil Red O staining technique showed treated small size of lipid droplets were distributed throughout the liver tissue. The mean of lipid accumulation in control and DMSO solvent control liver in natural water were 0.662 ± 0.009 and $0.666 \pm 0.004 \mu\text{m}^2$ per $100 \mu\text{m}^2$, respectively (Appendix B, table 1-B). Moreover, the mean of lipid accumulation in control and DMSO solvent control liver in carbofuran contaminated tap water were 0.660 ± 0.002 and $0.662 \pm 0.002 \mu\text{m}^2$ per $100 \mu\text{m}^2$, respectively (Appendix B, Table 1-B and Figures 4-5).

The PAS staining technique for glycogen accumulation of control and DMSO solvent control groups in both natural and tap water showed the positive staining with pinkish color. It indicated that both control groups accumulated glycogen in the liver tissues. The PAS staining is shown in Figures 4-6.

4.3.4.2 Treated liver tissues

4.3.4.2.1 Treated liver tissues in natural water contaminated with carbofuran

Histochemical study of treatment liver after 96 hours exposed to carbofuran at various concentrations in natural water was stained with Oil Red O technique for lipid study. The liver tissues showed large lipid droplets that were larger than the lipid droplets in both control groups and more number of lipid droplets than control liver. The mean of lipid accumulation in treatment groups were 0.746 ± 0.005 , 0.823 ± 0.003 , 1.199 ± 0.005 , 1.855 ± 0.006 and $1.888 \pm 0.004 \mu\text{m}^2$ per $100 \mu\text{m}^2$ in 0.005, 0.010, 0.025, 0.040 and 0.050 ppm, respectively (Appendix B, Table 1-B). The lipid accumulation in treatment group at 0.005 ppm was not significant difference when compared with control and DMSO solvent control groups ($P < 0.05$). On the other hand, the lipid accumulation in treatment groups at 0.010, 0.025, 0.040 and 0.050 ppm were significant difference compared with control and DMSO control groups ($P < 0.05$). The mean of lipid accumulation in liver tissues is shown in Graph 4-1 and Figure 4-5.

The PAS staining technique showed negative staining with brownish color of hepatic plate at all concentrations. It indicated that in treatment groups there were no glycogen accumulation in the liver tissues (Figure 4-6).

4.3.4.2.2 Treated liver tissues in tap water contaminated with carbofuran

Histochemical study of treated liver after 96 hours in tap water gave similar results as in natural water. The liver tissues showed large lipid droplets and more number of droplets than control groups. The mean of lipid accumulation in treatment groups were 0.761 ± 0.003 , 0.820 ± 0.002 , 1.199 ± 0.009 , 1.865 ± 0.006 and 1.876 ± 0.003 μm^2 per $100 \mu\text{m}^2$ in 0.005, 0.010, 0.025, 0.040 and 0.050 ppm, respectively (Appendix B, Table 1-B). Lipid accumulation in treatment groups at 0.005 ppm was not significant difference comparing with control groups ($P < 0.05$). In contrast, the lipid droplets accumulation in treatment groups at 0.010, 0.025, 0.040 and 0.050 ppm were significant difference compared with control groups ($P < 0.05$). The mean of lipid accumulation in liver tissue is shown in Graph 4-2 and Figures 4-5.

The PAS staining technique showed negative PAS staining with brownish color of hepatic plate at all concentrations. It indicated that in treatment groups, there was no glycogen accumulation found in the liver tissues. The glycogen accumulation in liver tissue is shown in Figures 4-6.

4.3.5 Recovery study

4.3.5.1 Gill tissues in natural water and tap water contaminated with carbofuran

The gill tissues after recovery period showed the same lesions and severity in both natural water and tap water. The severity of gill lesions after recovery period was decreased compared with exposure period (96 hours). The dilation of blood vessels, hypertrophy and desquamation were not found at all concentrations after recovery period. The mild degree of blood congestion in primary lamellar, epithelium necrosis, hyperplasia and rupture of pillar cell were recorded. Furthermore, blood congestion in

secondary lamellar, epithelial detachment, cellular swelling, secondary lamellar fusion and shortening were shown in moderate degree. The 0.005 and 0.010 ppm treatment groups could completely recover the gill lesions to normal because there could not detect the histological changes in gill tissues. The 0.025, 0.040 and 0.050 ppm treatment groups showed some gill injury with decrease in severity. Semi-quantitative scores of gill lesions after recovery period in natural water and tap water are shown in Table 4-7 and Figures 4-7.

4.3.5.2 Liver tissues in natural water and tap water contaminated with carbofuran

The histological alterations in liver tissues after recovery period showed the same lesions and severity in both natural water and tap water. The lesions included constriction of sinusoid, damage of endothelium of blood vessels, cellular swelling and hyperplasia were at the same severity as exposure period. Furthermore, amorphous nucleus shape, pyknosis and karyolysis of hepatocytes were still found in the same severity with exposure period (96 hours). Hypertrophy and blood congestion were not found after recovery period at all concentrations. Semi-quantitative scores of liver lesions in recovery period in natural water and tap water are shown in Table 4-8 and Figures 4-8.

4.3.5.3 Kidney tissues in natural water and tap water contaminated with carbofuran

The kidney tissues after recovery period showed the same lesions and severity in both natural water and tap water. The severity of most kidney lesions were the same degree compared with exposure period (96 hours) including Bowman's capsule damage and glomerulus rupture. Additionally, pyknosis, karyolysis and hyaline droplet accumulation were still in the same degree with exposure period (96 hours). Semi-quantitative scores of kidney lesions in recovery period in natural water and tap water are shown in Table 4-9 and Figures 4-9.

4.3.5.4 Lipid accumulation in natural water and tap water contaminated with carbofuran

After recovery period, the lipid accumulation in control and DMSO solvent control liver of natural water were 0.663 ± 0.002 and $0.0657 \pm 0.002 \mu\text{m}^2$ per $100 \mu\text{m}^2$, respectively (Appendix B, Table 2-B). The lipid accumulation in 0.005, 0.010, 0.025, 0.040 and 0.050 ppm treatment groups in natural water after recovery period were 0.764 ± 0.003 , 0.846 ± 0.004 , 1.222 ± 0.007 , 1.864 ± 0.006 and $1.878 \pm 0.006 \mu\text{m}^2$ per $100 \mu\text{m}^2$, respectively (Appendix B, Table 2-B). The lipid accumulation of natural water after recovery period showed that at 0.005 ppm treatment there was no significant difference comparing with the control groups. In contrast, lipid accumulation at 0.010, 0.025, 0.040 and 0.050 ppm treatment groups showed significant increase comparing with control groups (Graph 4-3). Moreover, after recovery period lipid accumulation in 0.010 and 0.025 ppm treatment groups were significantly increased when compared with the same concentration of exposure period (96 hours). The mean and standard error of lipid accumulation in natural water is shown in Graph 4-4.

After recovery period, the lipid accumulation in control and DMSO solvent control liver of tap water group were 0.661 ± 0.002 and $0.0659 \pm 0.002 \mu\text{m}^2$ per $100 \mu\text{m}^2$, respectively (Appendix B, Table 3-B). The lipid accumulation in 0.005, 0.010, 0.025, 0.040 and 0.050 ppm treatment groups after recovery period was 0.770 ± 0.003 , 0.851 ± 0.002 , 1.212 ± 0.004 , 1.865 ± 0.007 and $1.866 \pm 0.005 \mu\text{m}^2$ per $100 \mu\text{m}^2$, respectively (Appendix B, Table 3-B). The lipid accumulation at 0.005 ppm treatment group after recovery period was not difference comparing with control groups ($P < 0.05$). On the other hand, the 0.010, 0.025, 0.040 and 0.050 ppm treatment groups were significant increase comparing with control groups ($P < 0.05$) (Graph 4-5). Besides, at 0.010 ppm treatment after recovery period, lipid accumulation was significantly increased when compared with 0.010 ppm treatment group after exposure period (Graph 4-6). The lipid accumulation in tap water is shown in Figures 4-10.

4.3.5.5 Glycogen accumulation in natural water and tap water contaminated with carbofuran

After recovery period, liver tissues at all treatment groups showed negative staining with brown color comparing with positive stain in control groups. The glycogen accumulation in liver after recovery period is shown in Figures 4-11.

4.3.6 Comparison of the histopathology after the exposure of various concentrations of carbofuran in natural water and tap water contaminated with carbofuran

4.3.6.1 Gill

During the exposure period, the gill lesions and their severity after exposure to various sublethal concentrations of carbofuran showed a few differences between natural water and tap water. The gill lesions in treatment groups of both natural water and tap water showed the same lesions including blood congestion in primary and secondary lamellar, dilation of blood vessels and desquamation of epithelium. In addition, epithelial detachment, edema, secondary lamellar shortening and fusion, epithelium necrosis, hyperplasia and hypertrophy were detected. At high concentration (0.040 and 0.050 ppm), rupture of pillar cell system was observed. The degree of gill injury was increased when the exposure time and concentration were increased. The severity of gill lesions between natural water and tap water showed the difference in 0.040 and 0.050 ppm treatment groups. After 0.040 ppm treatment for 6 hours, moderate degree of blood congestion in primary and secondary lamellar was found in natural water while in tap water it was in mild degree. After 0.040 ppm treatment for 96 hours, epithelial detachment and swelling in natural water showed moderate degree but in tap water showed strong degree. Moreover, the 0.050 ppm treatment group had three differences of lesion severity between natural water and tap water. In natural water, epithelial detachment, cellular swelling, and shortening of secondary lamellar were found in strong degree but in tap water they were moderate degree. Conversely, the severity of necrosis in natural water showed moderate degree while in tap water showed strong degree. After recovery period, both natural water and tap water showed the

same recovery pattern. The severity of gill lesions after recovery period in natural water and tap water trended to decrease.

4.3.6.2 Liver

The histological alterations in liver tissues after 96 hours exposure to sublethal concentrations of carbofuran in natural water and tap water included the same lesions. The histological changes in liver tissues showed blood congestion and constriction of sinusoid. Additionally, cellular swelling, endothelium of blood vessels damage, hyperplasia, amorphous nucleus shape and necrosis with pyknosis and karyolysis were noticed. The severity of liver lesions between natural water and tap water showed a few differences. After 0.005 ppm treatment for 96 hours, amorphous nucleus shape was detected in natural water while in tap water this lesion was not presented. After 0.040 ppm treatment for 72 hours, damage of endothelium of blood vessels was observed in natural water while in tap water this lesion was not presented. Furthermore, after 0.050 ppm treatment for 48 hours, blood congestion was found only in tap water. Amorphous nucleus shape was found in tap water after exposure of 0.050 ppm for 48 hours but in natural water this lesion was not presented. After the recovery period, both natural water and tap water showed the same recovery lesions and their severity. The severity of liver toxicity in recovery period trended to equal and increase when compared with the exposure period (96 hours).

4.3.6.3 Kidney

After exposure period, kidney tissues showed the same renal toxicity in both natural water and tap water groups. The renal toxicity in this experiment included Bowman's capsule rupture and glomerular degeneration. Necrosis and hyaline droplet accumulation in the renal tubular cells were observed. The degree of lesions in exposure period in natural water and tap water displayed a few differences at 0.025 and 0.050 ppm treatment groups. After 0.025 ppm treatment for 72 hours, pyknosis was found in natural water but this lesion was not found in tap water. After 0.050 ppm

treatment for 48 hours in natural water, glomerular degeneration was not detected while it was found in tap water. After 0.050 ppm treatment for 72 hours, mild degree of pyknosis in natural water were detected while in tap water it was in moderate degree. After the recovery period, both natural water and tap water showed the same lesions and severity. The severity in recovery period of kidney lesion trended to equal degree comparing with the end of exposure period (96 hours).

4.3.6.4 Lipid accumulation

At the same concentration, lipid accumulation in liver tissues between natural water and tap water were not different ($P < 0.05$) in both control groups and treatment groups (Graph 4-7).

4.3.6.5 Glycogen accumulation

After exposure period, liver tissues showed negative stain with PAS technique. After recovery period, liver tissues of all treatment groups showed the same results as in the exposure period. The glycogen accumulation study in both natural water and tap water groups had similar results in both exposure period and recovery period.

4.4 DISCUSSIONS

Although it was a short-term exposure to the sublethal concentrations of carbofuran, the histopathological changes in small fish were observed. The federal maximum contaminant level (MCL) of carbofuran in water was 40 $\mu\text{g/L}$ (U.S.EPA, 1995). From the histological results, gill showed more sensitivity and more severity of lesions when compared with liver and kidney. In recovery period, gill lesions were reversible while liver and kidney lesions were irreversible. These results indicated that gill was the main target organ affected by carbofuran after short-term exposure. Fish gills are vulnerable to carbofuran in water because of their large surface area and external location. The gills are not only the crucial site of uptake the carbofuran in water but also the first important site of carbofuran impacts. The gills of teleost play a key role between

the organism and its environment. The gills are essential for life and are sensitive to both structure and biochemical disturbance. Interruption of gill function can result in death, whereas sublethal disturbances can depress the fitness of fish (Wood, 2001; Evans, Piermarini and Choe, 2005). Therefore, functional impairment of gills caused by carbofuran can damage the health of fish. Consequently, fish gills are considered to be the most appropriate indicators of water pollution levels (Alazemi, Lewis and Andrews, 1996).

The histological changes of gills in this experiment showed many histological changes. The severity of gill lesions was ranged from mild degree to strong degree. The histopathological changes of gill tissues including epithelial necrosis, desquamation and pillar cell system damage were the direct effects of carbofuran (Richmonds and Dutta, 1989). Epithelial rupture was probably the direct consequences of epithelial cell detachment and it indicated severe gill damage. The severe damages in term of necrosis and rupture of gill epithelium resulted in hypoxia and respiratory failure leading to the death of fish (Richmonds and Dutta, 1989). The defence responses of gill tissues in this study involved many processes. The detachment of epithelial cell away from basement membrane and edema resulted from fluid infiltration. These effects would be expected to increase passive fluxes of ions and water by disrupting tight junction. At the same time, this process might retard carbofuran uptake (Mallatt, 1985). Furthermore, hypertrophy of epithelial cell was related to necrosis as volume regulatory processes breakdown and cellular swelling occurred. Hyperplasia or proliferation of epithelial cell was shown as the defensive responses. It increased diffusion distance from the blood to water and reduction in the diffusive conductance of the gill to respiratory gases (Perry et al., 1996). Fusions of neighbouring lamellar caused a decrease of the gill surface retarding carbofuran uptake. The other lesions for example, lamellar aneurysms, vascular congestion, dilation of blood vessels and leukocyte infiltration could be considered as part of an inflammatory response ((McDonald, 1983; Mallatt, 1985; Wood, 2001).

Other studies showed the similar results that obtained from other insecticides. Mosquitofish exposed to deltamethrin showed desquamation, necrosis, epithelial hypertrophy, the detachment of the lamellar epithelium and fusion of the secondary lamellar (Cengiz and Unlu, 2006). Nile tilapia exposed to methyl parathion showed edema, hyperplasia, contracted pillar cell and necrosis (Wattanasirmit and Thirakhupt, 2006). Mosquitofish exposed to malathion displayed necrosis, cellular swelling, fusions of the secondary lamellar and epithelial detachment (Cengiz and Unlu, 2003). Fish exposed to organophosphate insecticides showed epithelial hyperplasia and edema, necrosis and detachment of epithelium (Fanta et al., 2003). *Channa punctatus* exposed to deltamethrin showed oxidative stress in gills (Sayeed et al., 2003).

The liver is an important organ for metabolism, detoxification of toxicants and biotransformation, etc. The severity of liver lesions in this experiment was ranged from mild degree to moderate degree. Hyperplasia of hepatic cell was the regenerative process of liver tissues. Hypertrophy and vacuolation were apparently caused by accumulation of fat. It was explained that the fat vacuolation resulted from microsomal and mitochondrial dysfunctions, which in turn inhibited synthesis of lipoprotein. The function of lipoprotein was transfer of lipid out of the cell resulting in lipid accumulation in hepatocytes. In this study, the absent of glycogen accumulation in hepatic cells might occur from the transfer of glycogen into the other forms such as glucose-1-phosphate by the action of glycogen phosphorylase (Morgan and Parmeggiani, 1964). Disturbance of the homeostasis of an organism led to compensatory, adaptive and finally pathological processes which were mostly energy-demanding. Therefore, the metabolic rate of an organism might increase under toxic stress (Dutra, Fernandes and Oliveira, 2008).

From other studies, the effects of insecticides were also shown similar alterations in liver. Hydropic swelling, vacuolization, hyaline accumulation and necrosis were found in liver of Nile tilapia exposed to methyl parathion (Wattanasirmit and Thirakhupt, 2006). *Labeo rohita* exposed to carbofuran and cypermethrin exhibited

diffuse necrosis and cordal disarrangement (Sarkar et al., 2005). After exposure to thiodan, the liver showed hepatic lesions including degeneration, hypertrophy, sinusoids enlargement and hemorrhage. Pyknosis of nuclei, vacuolization of cytoplasm and infiltration of mononuclear lymphocyte were also found (Cengiz, Unlu and Balci, 2001). *Cyprinus carpio* exposed to endosulfan showed extensive vacuolation, indistinct cell boundaries, loss of polygonal shape of the cell and degenerative necrosis (John, Jayabalan and George, 1993). The endosulfan, phosphamidon and aldicarp affected on histological changes in liver tissues (Gill, Pande and Tewari, 1990).

The kidney of fish receives blood from postbranchial blood vessels, therefore, renal lesions might be expected to be a good indicator of environmental pollution. In the present study, the pathology of kidney was found from mild degree to moderate degree. The degree of injuries correlated with carbofuran concentrations and the exposure time. Renal toxicity in fish was reported in many documents. *Cirrhinus mrigala* exposed to fenvalerate showed necrosis of tubular epithelium, pyknosis in the hematopoietic tissue and hypertrophied epithelial cells of renal tubules (Velmurugan et al., 2007). Glomerular shrinkage, vacuolization, hydropic swelling and hyaline droplet were displayed in the kidney of Nile tilapia exposure to methyl parathion (Wattanasirmit and Thirakhuat, 2006). After exposed to lindane, kidney showed tubular necrosis, desquamation and vacuolisation of tubular epithelial cells (Ortiz, Canales and Sarasquete, 2003). *Labeo rohita* exposed to hexachlorocyclohexane was reported to have the dilation of tubules, necrosis characterized by karyorrhexis and karyolysis (Dass and Mukherjee, 2000).

In this study, the histological alterations after short-term exposure to carbofuran in tap water and natural water showed the similar results in both lesions and their severity. These results suggested that microorganisms in natural water were not affected on degradation of carbofuran in this experiment. These might cause by the experiment period were only 4 days. It was shorter than half-life of carbofuran. The half-life of carbofuran in water was 8.2 weeks (Talebi and Walker, 1993; WHO, 2004).

Moreover, carbofuran can be degraded in water by hydrolysis and photolysis with or without microbial degradation (Winston and Joan, 2000; EPA, 2002). Degradation products in water are carbofuran phenol, 3-hydroxycarbofuran-7-phenol, 2, 3 dihydro-2,2-dimethyl benzofuran 4,7-diol and 3-ketocarbofuran. The degradation process of carbofuran molecule (represented as RX) occurred when it reacted with the water molecule originating a new C-H bond and breaking a C-H bond in the original molecule. The net reaction was essentially a direct displacement of X by OH (Luis Pedro et al., 2005).

4.5 CONCLUSIONS

In conclusion, the overall results indicated that carbofuran exposure, even in a short period, can induce histopathological alterations in the fish organs. All the histopathological observations indicated that the short-term exposure to sublethal concentrations of carbofuran caused destructive effects in the gill, liver and kidney tissues of guppy *Poecilia reticulata* Peters. The histopathological alterations and their severity in the gill, liver and kidney tissues of guppy increased with increasing concentrations and exposure time. Nevertheless, the lesions of gill were reversible after recovery period whereas that of liver and kidney were not reversible. This study suggested that the gill was the most important organ for survival of fish and it was more sensitive to both structural and biochemical disturbance of branchial epithelium. Disturbance to any of them would result in death. Therefore, fish might have physiological adaptation processes for survival. The histological result from tap water and natural water were not different in both lesions and severity. Gill, liver and kidney tissue alterations, such as those observed in this study and findings from previous studies, may result in severe functional problems, ultimately leading to the decrease in the fitness and the survival of fish.

TABLES, FIGURES AND GRAPHS

Table 4-1 The histopathological lesions and severity of gill tissues of guppy *P. reticulata* in control, DMSO and treatment groups in natural water (n=48).

Concentration (ppm)	Exposure time (hours)	Lesion										
		Blood congestion in primary lamellar	Blood congestion in secondary lamellar	Dilation of blood vessels	Desquamation of epithelium	Epithelial detachment and edema	Secondary lamellar fusion	Shortening of secondary lamellar	Epithelium necrosis	Hyperplasia	Hypertrophy	Rupture of pillar cell
Control		-	-	-	-	-	-	-	-	-	-	-
DMSO control		-	-	-	-	-	-	-	-	-	-	-
0.005	6	-	-	-	-	-	-	-	-	-	-	-
	24	-	-	-	-	-	-	-	-	-	-	-
	48	+	+	+	+	+	-	-	-	-	-	-
	72	+	+	+	+	+	-	-	-	-	-	-
	96	+	+	+	+	+	-	-	+	-	-	-
0.010	6	-	-	-	-	-	-	-	-	-	-	-
	24	-	-	+	+	+	-	-	-	-	-	-
	48	+	+	++	+	++	-	-	-	-	-	-
	72	+	+	+	++	++	-	-	-	-	-	-
	96	+	+	+	++	++	-	+	+	-	-	-
0.025	6	+	+	+	+	+	-	-	-	-	-	-
	24	+	++	+	+	++	-	-	+	-	-	-
	48	++	++	++	++	++	-	+	+	+	-	-
	72	+	++	++	++	++	+	++	++	+	-	-
	96	+	++	+	++	++	++	++	++	++	+	-
0.040	6	++	++	+	+	+	-	-	-	-	-	-
	24	++	++	++	++	++	+	+	+	+	-	+
	48	+	++	++	++	++	++	++	++	++	-	++
	72	+	+++	++	++	++	++	++	++	++	-	++
	96	+	+++	+	++	++	+++	+++	++	++	+	++
0.050	6	++	++	+	+	+	-	-	-	-	-	-
	24	++	++	++	++	++	+	+	+	+	-	+
	48	+	++	++	++	++	++	++	++	++	-	++
	72	+	+++	++	++	++	++	++	++	++	-	++
	96	+	+++	+	++	+++	+++	+++	++	++	+	++

Table 4-2 The histopathological lesions and severity of gill tissues of guppy *P. reticulata* in control, DMSO and treatment groups in tap water (n=48).

Concentration (ppm)	Exposure time (hours)	Lesion											
		Blood congestion in primary lamellar	Blood congestion in secondary lamellar	Dilation of blood vessels	Desquamation of epithelium	Epithelial detachment and edema	Secondary lamellar fusion	Shortening of secondary lamellar	Epithelium necrosis	Hyperplasia	Hypertrophy	Rupture of pillar cell	
Control		-	-	-	-	-	-	-	-	-	-	-	-
DMSO		-	-	-	-	-	-	-	-	-	-	-	-
control	6	-	-	-	-	-	-	-	-	-	-	-	-
0.005	24	-	-	-	-	-	-	-	-	-	-	-	-
	48	+	+	+	+	+	-	-	-	-	-	-	-
	72	+	+	+	+	+	-	-	-	-	-	-	-
	96	+	+	+	+	+	-	-	+	-	-	-	-
0.010	6	-	-	-	-	-	-	-	-	-	-	-	-
	24	-	-	+	+	+	-	-	-	-	-	-	-
	48	+	+	++	+	++	-	-	-	-	-	-	-
	72	+	+	+	++	++	-	-	-	-	-	-	-
0.025	96	+	+	+	++	++	-	+	+	-	-	-	-
	6	+	+	+	+	+	-	-	-	-	-	-	-
	24	+	++	+	+	++	-	-	+	-	-	-	-
	48	++	++	++	++	++	-	+	+	+	-	-	-
0.040	72	+	++	++	++	++	+	++	++	+	-	-	-
	96	+	++	+	++	++	++	++	++	++	+	-	-
	6	+	+	+	+	+	-	-	-	-	-	-	-
	24	++	++	++	++	++	+	+	+	+	-	-	+
0.050	48	+	++	++	++	++	++	++	++	++	-	-	++
	72	+	+++	++	++	++	++	++	++	++	-	-	++
	96	+	+++	+	++	+++	+++	+++	++	++	+	-	++
	6	++	++	+	+	+	-	-	-	-	-	-	-
0.050	24	++	++	++	++	++	+	+	+	+	-	-	+
	48	+	++	++	++	++	++	++	++	++	-	-	++
	72	+	+++	++	++	++	++	++	++	++	-	-	++
	96	+	+++	+	++	++	+++	++	+++	++	+	-	++

Table 4-3 The histopathological lesions and severity of liver tissues of guppy *P. reticulata* in control, DMSO and treatment groups in natural water (n=48).

Concentration (ppm)	Exposure time (hours)	Lesion							
		Constriction of sinusoid	Blood congestion	Cellular swelling	Endothelium of blood vessels damage	Hyperplasia	Amorphous nucleus shape	Pyknosis	Karyolysis
Control		-	-	-	-	-	-	-	-
DMSO control		-	-	-	-	-	-	-	-
0.005	6	-	-	-	-	-	-	-	-
	24	-	-	-	-	-	-	-	-
	48	-	-	-	-	-	-	-	-
	72	-	-	+	-	+	-	-	-
	96	-	-	+	-	++	-	+	-
0.010	6	-	-	-	-	-	-	-	-
	24	-	-	-	-	-	-	-	-
	48	-	-	-	-	-	-	-	-
	72	-	-	+	-	+	-	-	-
	96	-	-	+	-	++	+	+	-
0.025	6	-	-	-	-	-	-	-	-
	24	-	-	-	-	-	-	-	-
	48	+	-	+	-	-	-	-	-
	72	-	+	+	-	-	+	-	-
	96	-	+	+	+	-	+	+	+
0.040	6	-	-	-	-	-	-	-	-
	24	-	-	-	-	-	-	-	-
	48	+	-	+	-	-	+	-	-
	72	+	+	+	+	-	+	+	+
	96	-	+	+	+	-	++	++	+
0.050	6	-	-	-	-	-	-	-	-
	24	-	-	-	-	-	-	-	-
	48	+	+	+	+	-	-	+	-
	72	+	+	+	+	-	+	+	+
	96	+	+	+	+	-	++	++	+

Table 4-4 The histopathological lesions and severity of liver tissues of guppy *P. reticulata* in control, DMSO and treatment groups in tap water (n=48).

Concentration (ppm)	Exposure time (hours)	Lesion							
		Constriction of sinusoid	Blood congestion	Cellular swelling	Endothelium of blood vessels damage	Hyperplasia	Amorphous nucleus shape	Pyknosis	Karyolysis
Control		-	-	-	-	-	-	-	-
DMSO control		-	-	-	-	-	-	-	-
0.005	6	-	-	-	-	-	-	-	-
	24	-	-	-	-	-	-	-	-
	48	-	-	-	-	-	-	-	-
	72	-	-	+	-	+	-	-	-
	96	-	-	+	-	++	+	+	-
0.010	6	-	-	-	-	-	-	-	-
	24	-	-	-	-	-	-	-	-
	48	-	-	-	-	-	-	-	-
	72	-	-	+	-	+	-	-	-
	96	-	-	+	-	++	+	+	-
0.025	6	-	-	-	-	-	-	-	-
	24	-	-	-	-	-	-	-	-
	48	+	-	+	-	-	-	-	-
	72	-	+	+	-	-	+	-	-
	96	-	+	+	+	-	+	+	+
0.040	6	-	-	-	-	-	-	-	-
	24	-	-	-	-	-	-	-	-
	48	+	-	+	-	-	+	-	-
	72	+	+	+	-	-	+	+	+
	96	-	+	+	+	-	++	++	+
0.050	6	-	-	-	-	-	-	-	-
	24	-	-	-	-	-	-	-	-
	48	+	-	+	+	-	+	+	-
	72	+	+	+	+	-	+	+	+
	96	+	+	+	+	-	++	++	+

Table 4-5 The histopathological lesions and severity of kidney tissues of guppy *P. reticulata* in control, DMSO and treatment groups in natural water (n=48).

Concentration (ppm)	Exposure time (hours)	Lesion				
		Bowman's capsule rupture	Glomerular degeneration	Pyknosis	Karyolysis	Hyaline droplet
Control		-	-	-	-	-
DMSO control		-	-	-	-	-
0.005	6	-	-	-	-	-
	24	-	-	-	-	-
	48	-	-	-	-	-
	72	-	-	-	-	-
	96	-	-	-	+	-
0.010	6	-	-	-	-	-
	24	-	-	-	-	-
	48	-	-	-	-	-
	72	-	-	+	-	-
	96	+	-	+	+	-
0.025	6	-	-	-	-	-
	24	-	-	-	-	-
	48	-	-	-	-	-
	72	+	-	+	+	-
	96	+	+	+	+	-
0.040	6	-	-	-	-	-
	24	-	-	-	-	-
	48	-	-	+	-	-
	72	+	+	+	+	-
	96	+	+	+	+	-
0.050	6	-	-	-	-	-
	24	-	-	-	-	-
	48	-	-	+	-	-
	72	+	+	+	+	-
	96	+	+	++	+	+

Table 4-6 The histopathological lesions and severity of kidney tissues of guppy *P. reticulata* in control, DMSO and treatment groups in tap water (n=48).

Concentration (ppm)	Exposure time (hours)	Lesion				
		Bowman's capsule rupture	Glomerular degeneration	Pyknosis	Karyolysis	Hyaline droplet
Control		-	-	-	-	-
DMSO control		-	-	-	-	-
0.005	6	-	-	-	-	-
	24	-	-	-	-	-
	48	-	-	-	-	-
	72	-	-	-	-	-
	96	-	-	-	+	-
0.010	6	-	-	-	-	-
	24	-	-	-	-	-
	48	-	-	-	-	-
	72	-	-	+	-	-
	96	+	-	+	+	-
0.025	6	-	-	-	-	-
	24	-	-	-	-	-
	48	-	-	-	-	-
	72	+	-	-	+	-
	96	+	+	+	+	-
0.040	6	-	-	-	-	-
	24	-	-	-	-	-
	48	-	-	+	-	-
	72	+	+	+	+	-
	96	+	+	+	+	-
0.050	6	-	-	-	-	-
	24	-	-	-	-	-
	48	-	-	+	-	-
	72	+	+	++	+	-
	96	+	+	++	+	+

Table 4-7 The histopathological lesions and severity of gill tissues of *P. reticulata* after 96 hours recovery period (n=48).

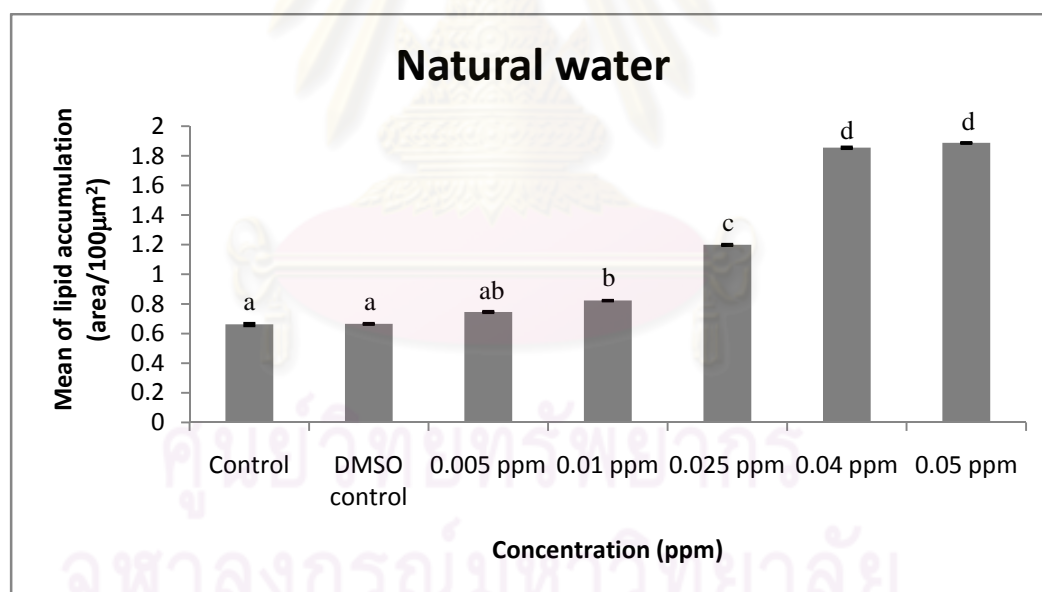
Lesion	In natural water					In tap water				
	0.005	0.01	0.025	0.04	0.05	0.005	0.01	0.025	0.04	0.05
Blood congestion in primary lamellar	-	-	-	-	+	-	-	-	-	+
Blood congestion in secondary lamellar	-	-	+	++	++	-	-	+	++	++
Dilation of blood vessels	-	-	-	-	-	-	-	-	-	-
Desquamation	-	-	-	-	-	-	-	-	-	-
Epithelium detachment and oedema	-	-	-	+	++	-	-	-	+	++
Secondary lamellar fusion	-	-	+	++	++	-	-	+	++	++
Shortening of secondary lamellae	-	-	+	++	++	-	-	+	++	++
Epithelium necrosis	-	-	-	+	+	-	-	-	+	+
Hyperplasia	-	-	-	-	+	-	-	-	-	+
Hypertrophy	-	-	-	-	-	-	-	-	-	-
Rupture of pillar cell	-	-	-	+	+	-	-	-	+	+

Table 4-8 The histopathological lesions and severity of liver tissues of *P. reticulata* after 96 hours recovery period (n=48).

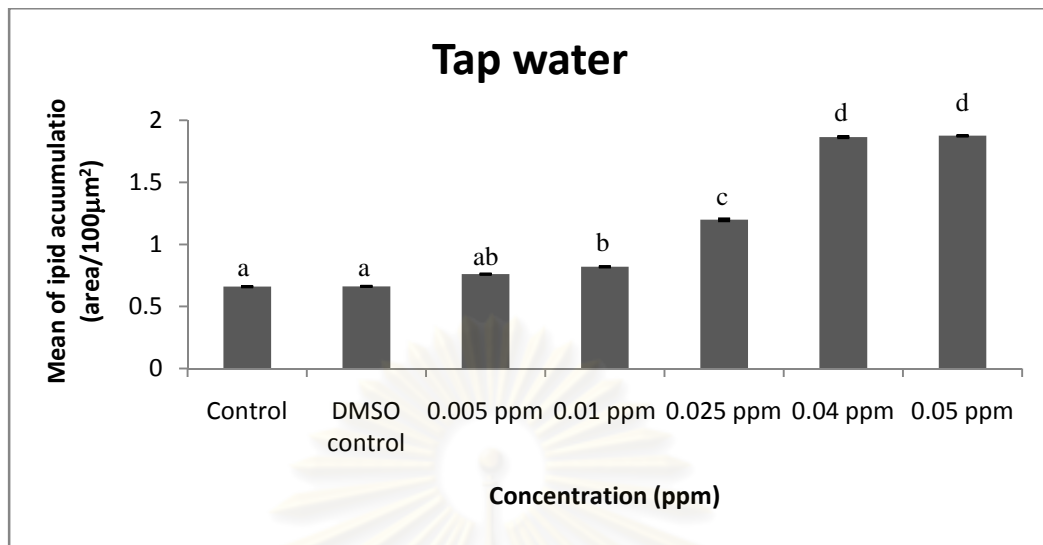
Lesion	In natural water					In tap water				
	0.005	0.01	0.025	0.04	0.05	0.005	0.01	0.025	0.04	0.05
Constriction of sinusoid	-	-	-	-	+	-	-	-	-	+
Blood congestion	-	-	-	-	-	-	-	-	-	-
Cellular swelling	-	+	+	+	+	+	+	+	+	+
Endothelium of blood vessels damage	-	-	+	+	+	-	-	+	+	+
Hyperplasia	++	++	-	-	-	++	++	-	-	-
Amorphous nucleus shape	+	+	+	++	++	+	+	+	++	++
Pyknosis	+	+	+	++	++	+	+	+	++	++
Karyolysis	-	-	+	+	++	-	-	+	+	++

Table 4-9 The histopathological lesions and severity of kidney tissues of *P. reticulata* after 96 hours recovery period (n=48)

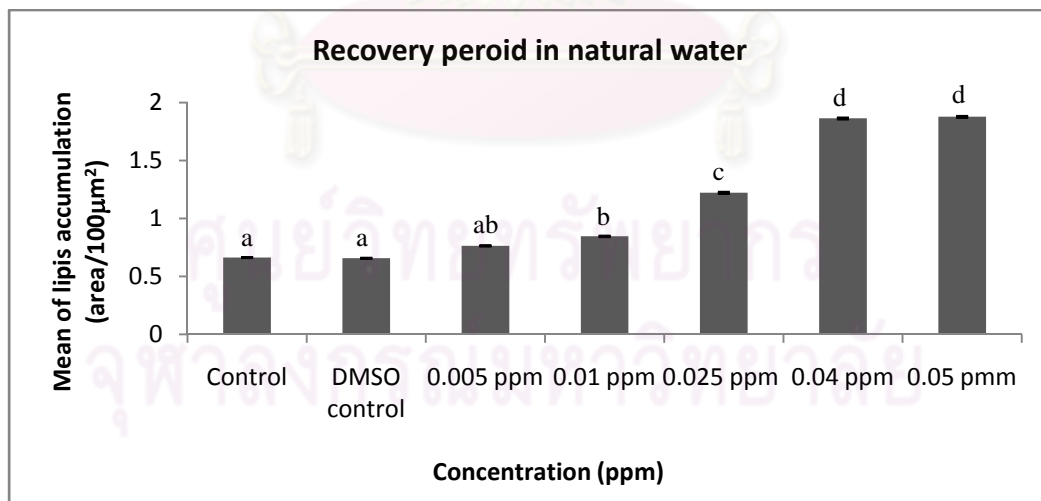
Lesion	In natural water					In tap water				
	0.005	0.01	0.025	0.04	0.05	0.005	0.01	0.025	0.04	0.05
Bowman's capsule rupture	-	+	+	+	+	-	+	+	+	+
Glomerular degeneration	-	-	+	+	+	-	-	+	+	+
Pyknosis	-	+	+	+	++	-	+	+	+	++
Karyolysis	+	+	+	+	+	+	+	+	+	+
Hyaline droplet	-	-	-	-	+	-	-	-	-	+



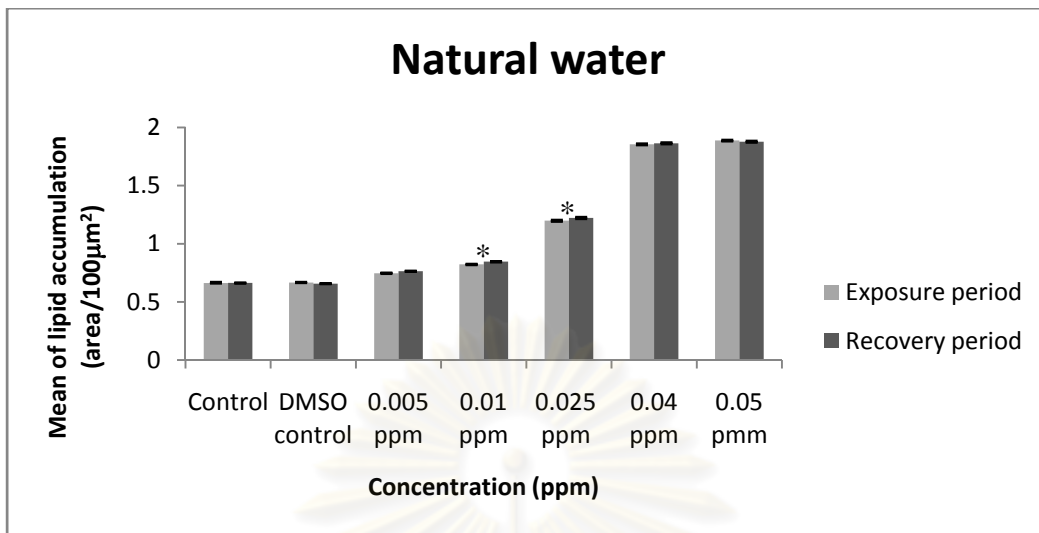
Graph 4-1 The mean of lipid accumulation in hepatocytes of *P. reticulata* in control, DMSO and treatment groups at 96 hours exposure period in liver tissues per 100 µm² of natural water at various concentrations. Mean with different letters (a, b, c and d) are significantly different ($P < 0.05$).



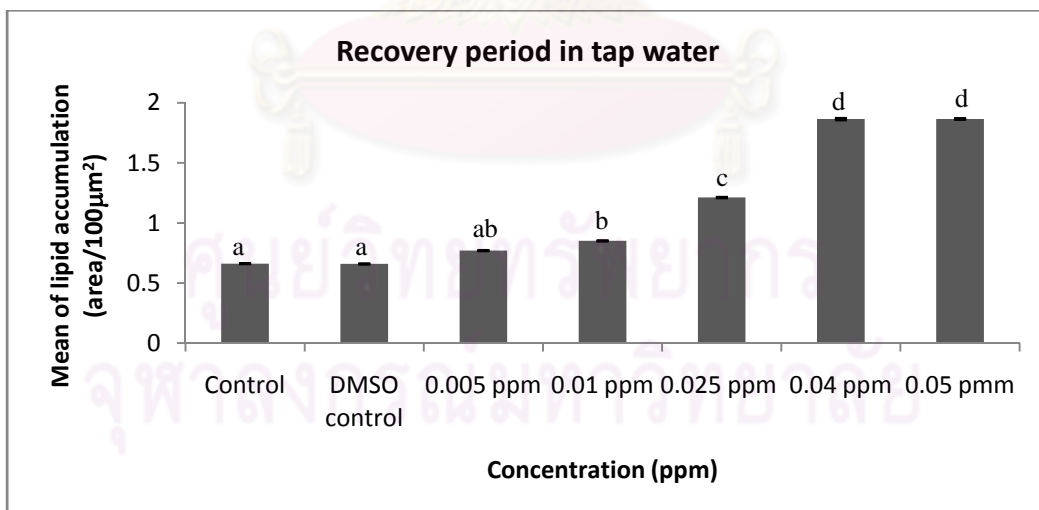
Graph 4-2 The mean of lipid accumulation in hepatocytes of *P. reticulata* in control, DMSO and treatment groups at 96 hours exposure period in liver tissues per 100 μm^2 of tap water at various concentrations. Mean with different letters (a, b, c and d) are significantly different ($P < 0.05$).



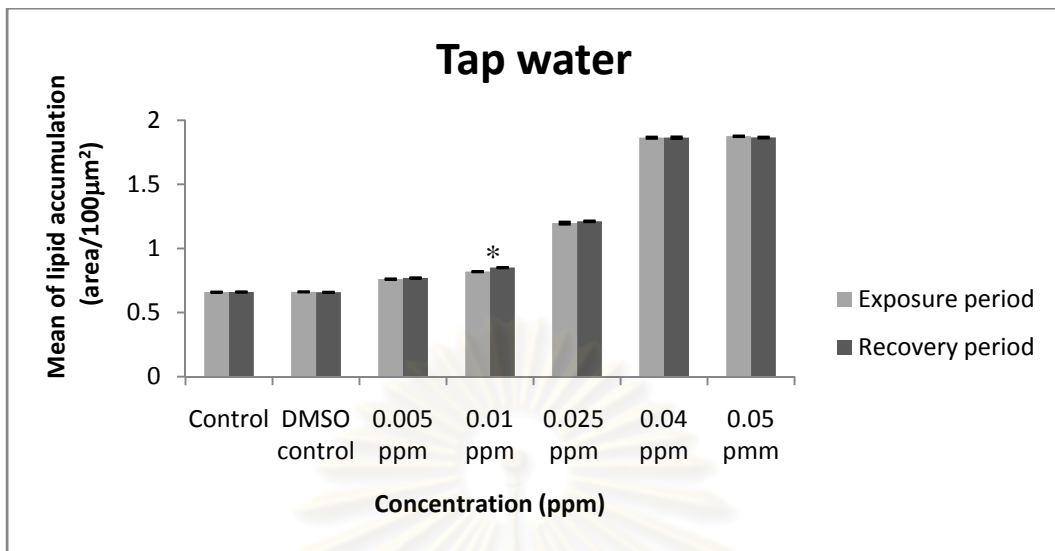
Graph 4-3 The mean of lipid accumulation in hepatocytes of *P. reticulata* in control, DMSO and treatment groups at 96 hours recovery period in liver tissues per 100 μm^2 in natural water. Mean with different letters (a, b, c and d) are significantly different ($P < 0.05$).



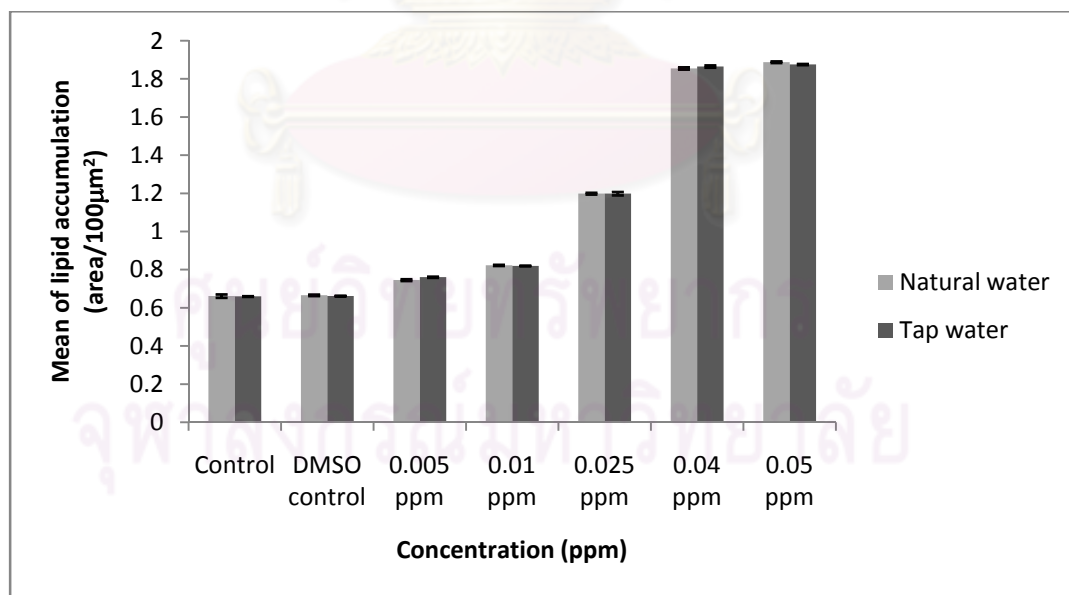
Graph 4-4 The mean of lipid accumulation in hepatocytes of *P. reticulata* in control, DMSO and treatment groups in liver tissues per 100 µm² in natural water at exposure period and recovery period. Mean with (*) is significantly different ($P < 0.05$).



Graph 4-5 The mean of lipid accumulation in hepatocytes of *P. reticulata* in control, DMSO and treatment groups at 96 hours recovery period in liver tissues per 100 µm² in tap water. Mean with different letters (a, b, c and d) are significantly different ($P < 0.05$).



Graph 4-6 The mean of lipid accumulation in hepatocytes of *P. reticulata* in control, DMSO and treatment groups in liver tissues per 100 μm^2 in tap water at exposure period and recovery period. Mean with (*) is significantly different ($P < 0.05$).



Graph 4-7 The mean of lipid accumulation in hepatocytes of *P. reticulata* in control, DMSO and treatment groups at 96 hours exposure period in liver tissue per 100 μm^2 in natural water and tap water at various concentrations.

Figure 4-1

Photomicrograph of treated gill of guppy *Poecilia reticulata*
(H&E staining)

- A Photomicrograph of control gill shows the normal gill structures comprising numerous gill filaments or primary lamellae (*) and secondary lamellae or respiratory lamellae (arrow). Bar: 20 μm .
- B Photomicrograph of treated gill tissue exposed to 0.005 ppm carbofuran for 72 h in tap water shows blood congestion in secondary lamellar (*). Bar: 20 μm .
- C Photomicrograph of treated gill tissue exposed to 0.025 ppm carbofuran for 96 h in natural water shows epithelial hyperplasia (dark triangle), secondary lamellar fusion (black arrowhead), epithelial delaminate and edema (arrow) and epithelium necrosis (circle). Bar: 40 μm .
- D Photomicrograph of treated gill tissue exposed to 0.040 ppm carbofuran for 24 h in tap water shows epithelial hyperplasia (dark triangle), necrosis of epithelial cell (circle), pillar cell system rupture with blood congestion in secondary lamellar (gray arrowhead), epithelial delaminate and edema (arrow). Bar: 40 μm .
- E Photomicrograph of treated gill tissue exposed to 0.040 ppm carbofuran for 24 h in tap water shows pillar cell system in secondary lamellar damage (gray arrowhead), epithelium necrosis (circle) and epithelial delaminate and edema (arrow). Bar: 20 μm .
- F Photomicrograph of treated gill tissue exposed to 0.050 carbofuran for 96 h in tap water shows secondary lamellar shortening and fusion (black arrowhead), epithelium necrosis (circle) and hypertrophy (triangle). Bar: 20 μm .

Figure 4-1

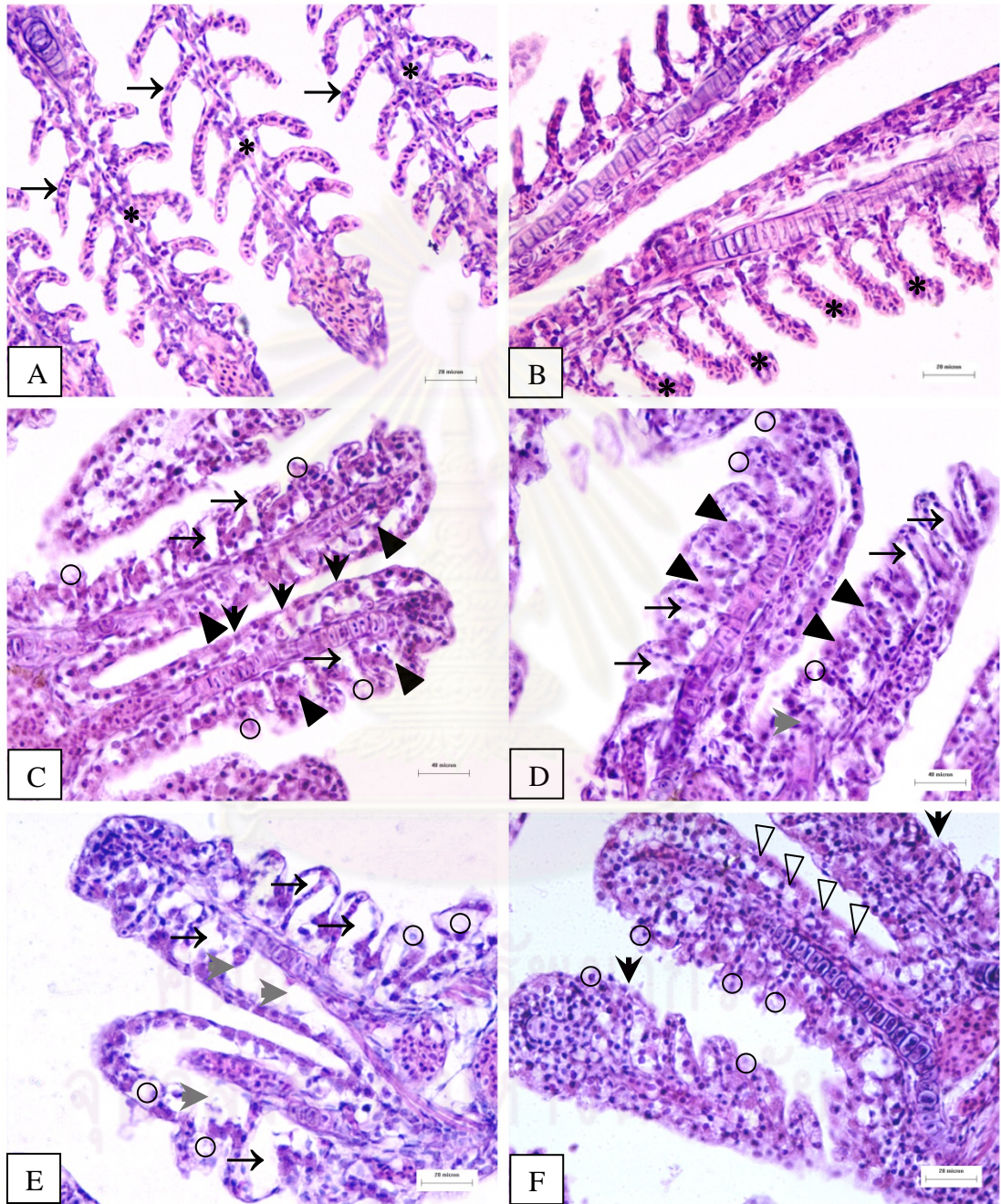


Figure 4-2

Photomicrograph of treated liver of guppy *Poecilia reticulata*
(H&E staining)

- A Photomicrograph of liver of the control fish shows hepatocytes (H) locating among the sinusoids (S). It contains round concentric nucleus (arrow). Bar: 20 μm .
- B Photomicrograph of treated liver tissue exposed to 0.010 ppm carbofuran for 96 h in natural water shows swelling of hepatic capsule with fluid infiltration under capsule lining (star), cellular swelling (gray arrowhead) and necrosis (circle). Bar: 20 μm .
- C Photomicrograph of treated liver tissue exposed to 0.010 ppm carbofuran for 96 h in natural water shows pyknotic nucleus ($>$), hepatic capsule rupture (star) and lipid droplet accumulation (dark triangle). Bar: 20 μm .
- D Photomicrograph of treated liver tissue exposed to 0.025 ppm carbofuran for 72 h in natural water shows blood congestion (*) and necrosis (circle). Bar: 20 μm .
- E Photomicrograph of treated liver tissue exposed to 0.040 ppm carbofuran for 96 h in natural water shows necrosis (circle), leukocyte infiltration in hepatic parenchyma ($>>>$), karyolysis ($>>$), cellular swelling (gray arrowhead) and lipid accumulation (dark triangle). Bar: 20 μm .
- F Photomicrograph of treated liver tissue exposed to 0.050 carbofuran for 96 h in tap water shows large size of lipid droplets fusion (dark triangle) and pyknosis ($>$). Bar: 20 μm .

Figure 4-2

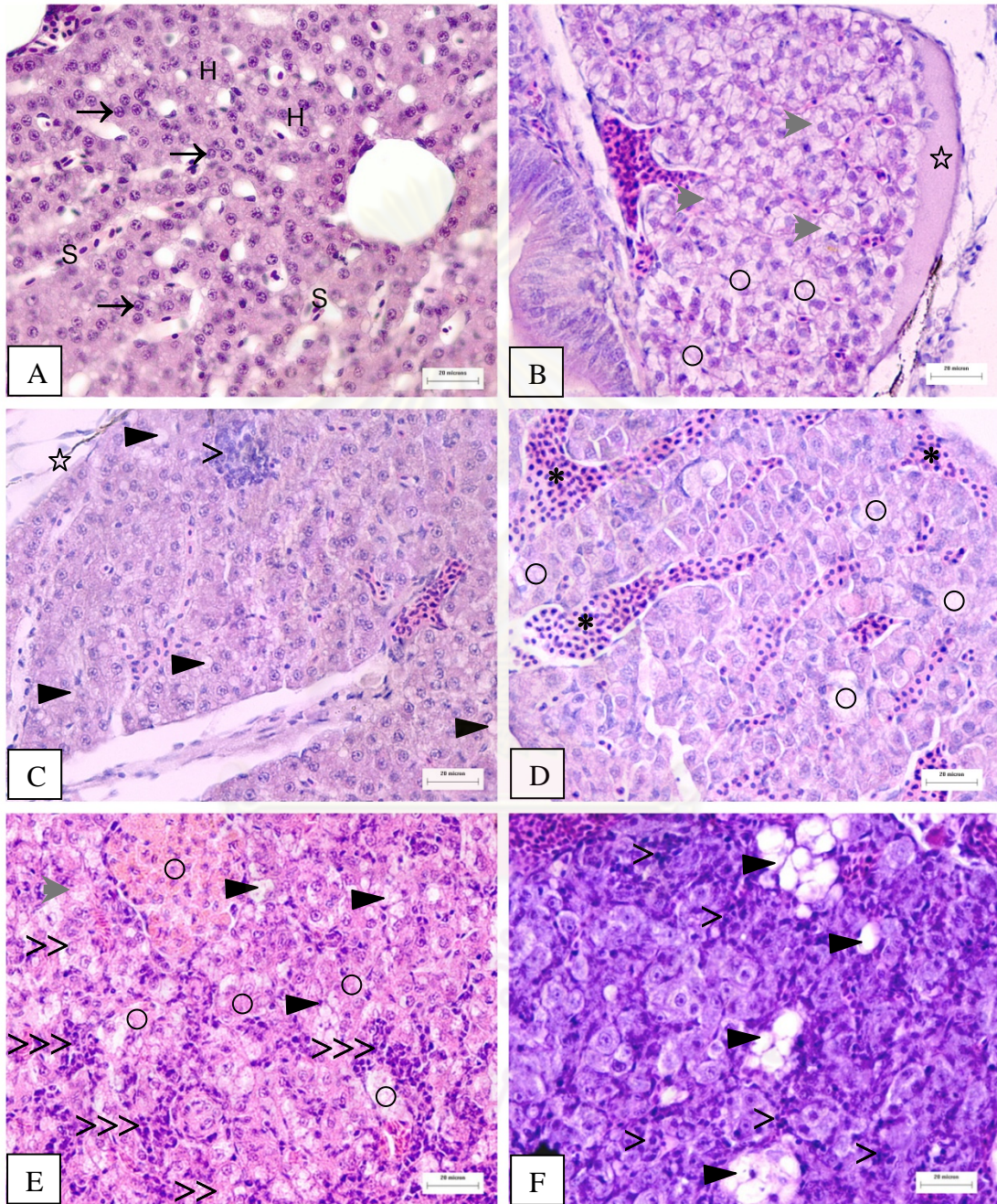


Figure 4-3

Photomicrograph of treated liver of guppy *Poecilia reticulata*
(H&E staining)

- A Photomicrograph of control liver shows normal histological structure. Bar: 20 μm .
- B Photomicrograph of treated liver tissue exposed to 0.005 ppm carbofuran for 96 h in natural water shows cellular swelling (gray arrowhead) and lipid accumulation (dark triangle). Bar: 20 μm .
- C Photomicrograph of treated liver tissue exposed to 0.050 ppm carbofuran for 96 h in natural water shows constriction of sinusoid (arrow), cellular swelling (gray arrowhead) and necrosis (circle). Bar: 20 μm .
- D Photomicrograph of treated liver tissue exposed to 0.040 ppm carbofuran for 48 h in tap water shows epithelium of blood vessels thickening and rupture in hepatic parenchyma (black arrowhead) and cellular swelling (gray arrowhead). Bar: 20 μm .
- E Photomicrograph of treated liver tissue exposed to 0.050 ppm carbofuran for 96 h in natural water shows pyknosis (>), karyolysis (>>) and cellular necrosis (circle). Bar: 10 μm .
- F Photomicrograph of treated liver tissue exposed to 0.050 ppm carbofuran for 96 h in natural water shows karyolysis (>>) and cellular necrosis (circle). Bar: 10 μm .

Figure 4-3

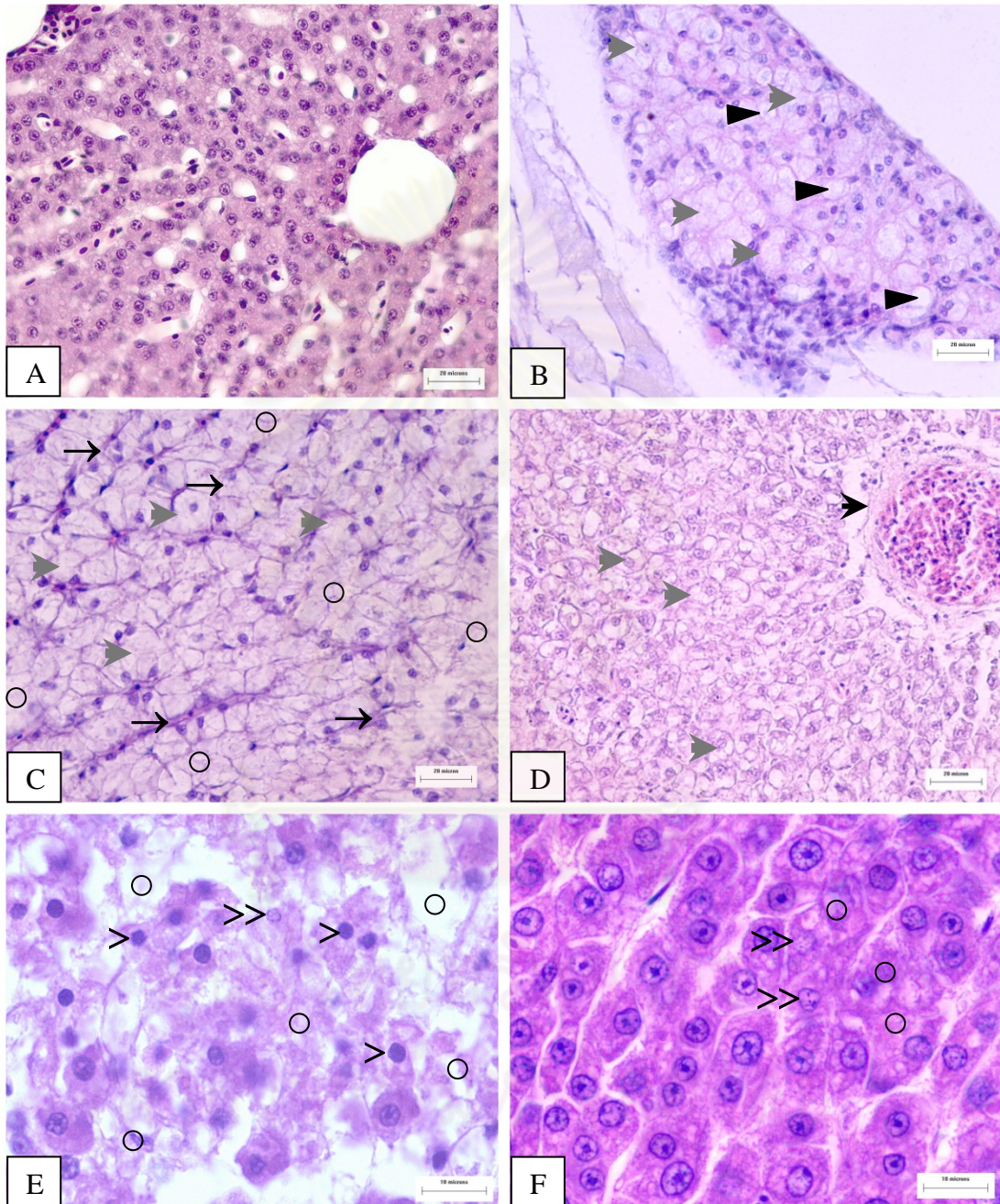


Figure 4-4

Photomicrograph of treated kidney of guppy *Poecilia reticulata*
(H&E staining)

- A Photomicrograph of control kidney shows the normal kidney. It comprises of distal tubule (DT) lining by cuboidal cell. Proximal tubule (PT) is lined by columnar cell and prominent brush border and glomerulus (G). Bar: 20 μm .
- B Photomicrograph of treated kidney tissue exposed to 0.010 ppm carbofuran for 48 h in natural water shows glomerular enlargement (black arrowhead), loss of hematopoietic tissue (circle) and clumping of blood cells in hematopoietic tissue (>>>). Bar: 40 μm .
- C Photomicrograph of treated kidney tissue exposed to 0.010 ppm carbofuran for 48 h in tap water shows dilation of glomerular capillaries with blood congestion (black arrowhead), Bowman's capsule rupture (gray arrowhead), cellular swelling (*) and renal tubular swelling (white triangle). Bar: 20 μm .
- D Photomicrograph of treated kidney tissue exposed to 0.050 carbofuran for 72 h in tap water shows macrophage infiltration (>), cellular debris in renal tubular lumen (star) and karyolysis (triangle). Bar: 20 μm .
- E Photomicrograph of treated kidney tissue exposed to 0.040 ppm carbofuran for 72 h in tap water shows pyknosis (arrow) and glomerular degeneration resulting enlargement of Bowman's capsule space (black arrowhead). Bar: 20 μm .
- F Photomicrograph of treated kidney tissue exposed to 0.025 ppm carbofuran for 96 h in natural water shows pyknosis (arrow), glomerular degeneration (black arrowhead) and necrosis of renal tubule (square). Bar: 20 μm .

Figure 4-4

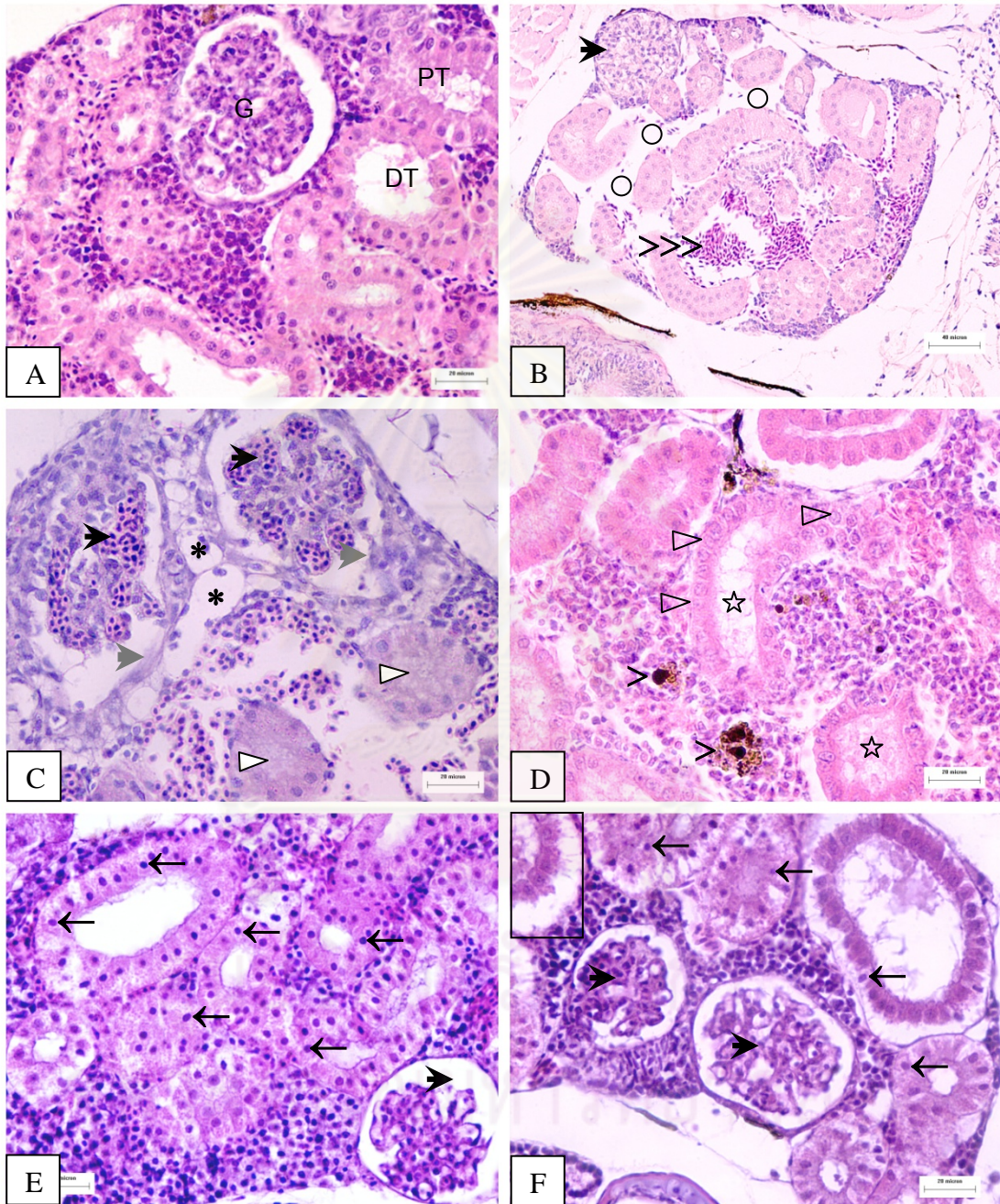


Figure 4-5

Photomicrograph of treated liver of guppy *Poecilia reticulata*
(Oil Red O staining)

- A Photomicrograph of control liver shows small size of lipid accumulation in hepatocyte. Bar: 20 μm .
- B Photomicrograph of treated liver tissue exposed to 0.005 ppm carbofuran for 96 h shows small size of lipid accumulation in hepatocyte. Bar: 20 μm .
- C Photomicrograph of treated liver tissue exposed to 0.010 ppm carbofuran for 96 h shows small size of lipid accumulation in hepatocyte. Bar: 20 μm .
- D Photomicrograph of treated liver tissue exposed to 0.025 ppm carbofuran for 96 h shows small size of lipid accumulation in hepatocyte. Bar: 20 μm .
- E Photomicrograph of treated liver tissue exposed to 0.040 ppm carbofuran for 96 h shows moderate size of lipid accumulation in hepatocyte. Bar: 20 μm .
- F Photomicrograph of treated liver tissue exposed to 0.050 ppm carbofuran for 96 h shows large size and more number of lipid accumulation in hepatocyte. Bar: 20 μm .

ศูนย์วิทยาศาสตร์
จุฬาลงกรณ์มหาวิทยาลัย

Figure 4-5

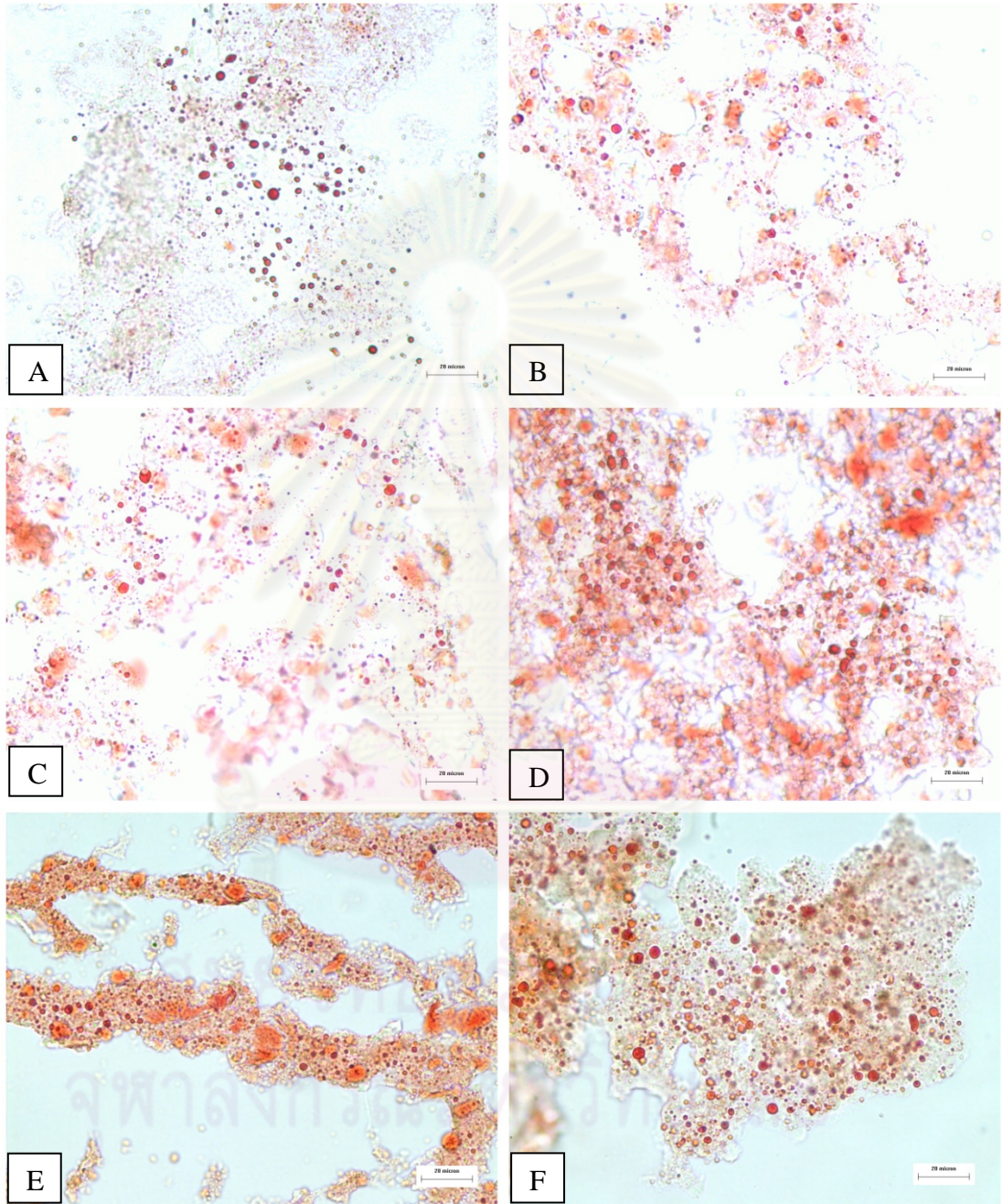


Figure 4-6

Photomicrograph of treated liver of guppy *Poecilia reticulata*
(PAS staining)

- A Photomicrograph of control liver shows positive PAS staining with pink color. Bar: 20 μm .
- B Photomicrograph of treated liver tissue exposed to 0.005 ppm carbofuran for 96 h shows negative PAS staining with brown color. Bar: 20 μm .
- C Photomicrograph of the liver tissue exposed to 0.010 ppm carbofuran for 96 h shows negative PAS staining with brown color. Bar: 20 μm .
- D Photomicrograph of treated liver tissue exposed to 0.025 ppm carbofuran for 96 h shows negative PAS staining with brown color. Bar: 20 μm .
- E Photomicrograph of treated liver tissue exposed to 0.040 ppm carbofuran for 96 h shows negative PAS staining with brown color. Bar: 20 μm .
- F Photomicrograph of treated liver tissue exposed to 0.050 ppm carbofuran for 96 h shows negative PAS staining with brown color. Bar: 20 μm .

Figure 4-6

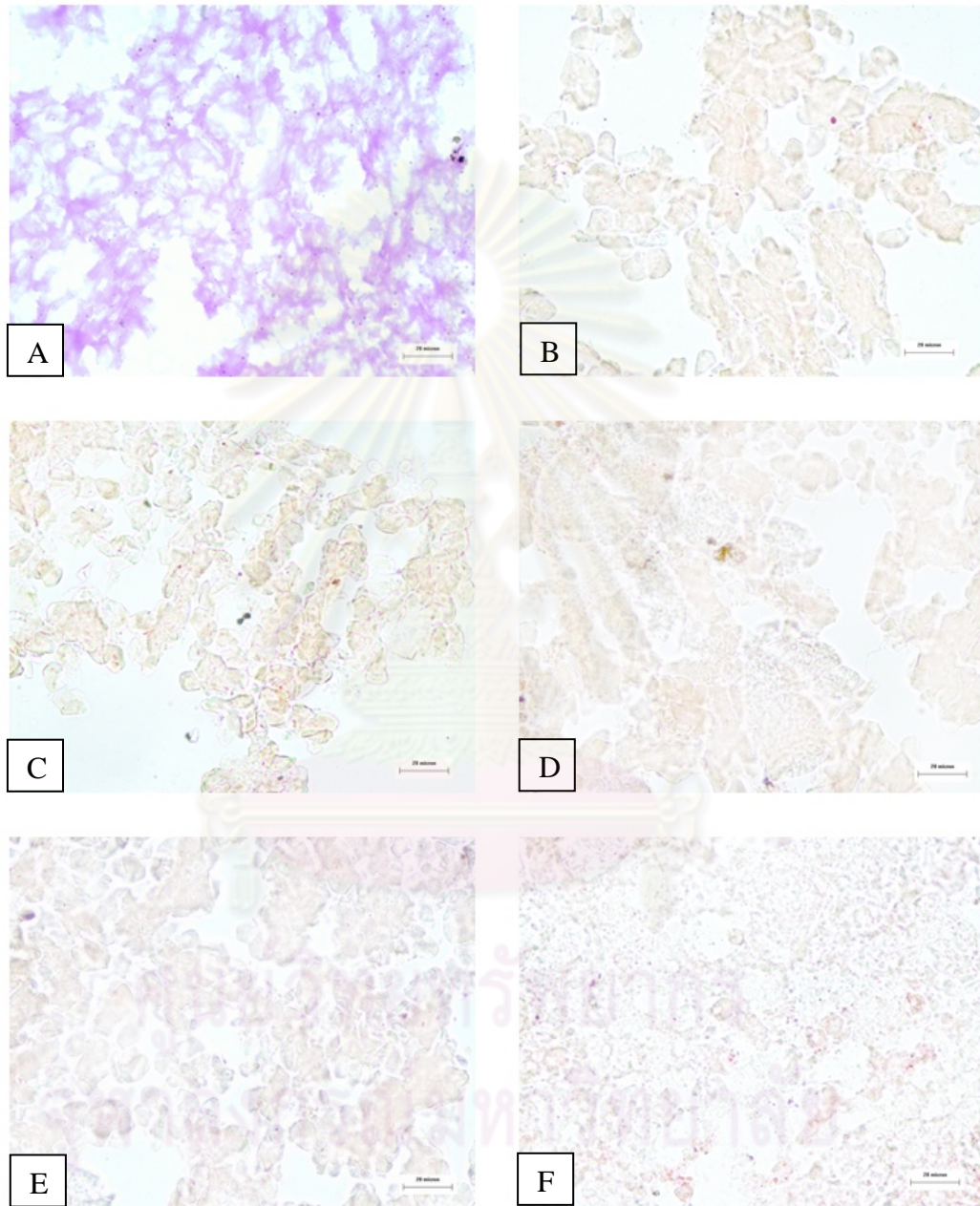


Figure 4-7

Photomicrograph of recovery gill of guppy *Poecilia reticulata*
(H&E staining)

- A Photomicrograph of the control gill shows normal histological structure. Bar: 40 μm .
- B Photomicrograph of treated gill tissue exposed to 0.005 ppm carbofuran in natural water shows complete recovery of lesions. Bar: 20 μm .
- C Photomicrograph of treated gill tissue exposed to 0.010 ppm carbofuran in tap water shows complete recovery of lesions. Bar: 40 μm .
- D Photomicrograph of treated gill tissue exposed to 0.025 ppm carbofuran in tap water still shows hyperplasia (dark triangle), desquamation (arrow) and epithelium necrosis (circle). Bar: 20 μm .
- E Photomicrograph of treated gill tissue exposed to 0.040 ppm carbofuran in natural water shows epithelium necrosis (circle), blood congestion in secondary lamellar (*) and hyperplasia (dark triangle). Bar: 20 μm .
- F Photomicrograph of treated gill tissue exposed to 0.050 carbofuran in tap water shows aneurism (*), shortening and fusion of secondary lamellar (black arrowhead) and epithelium necrosis (circle). Bar: 20 μm .

Figure 4-7

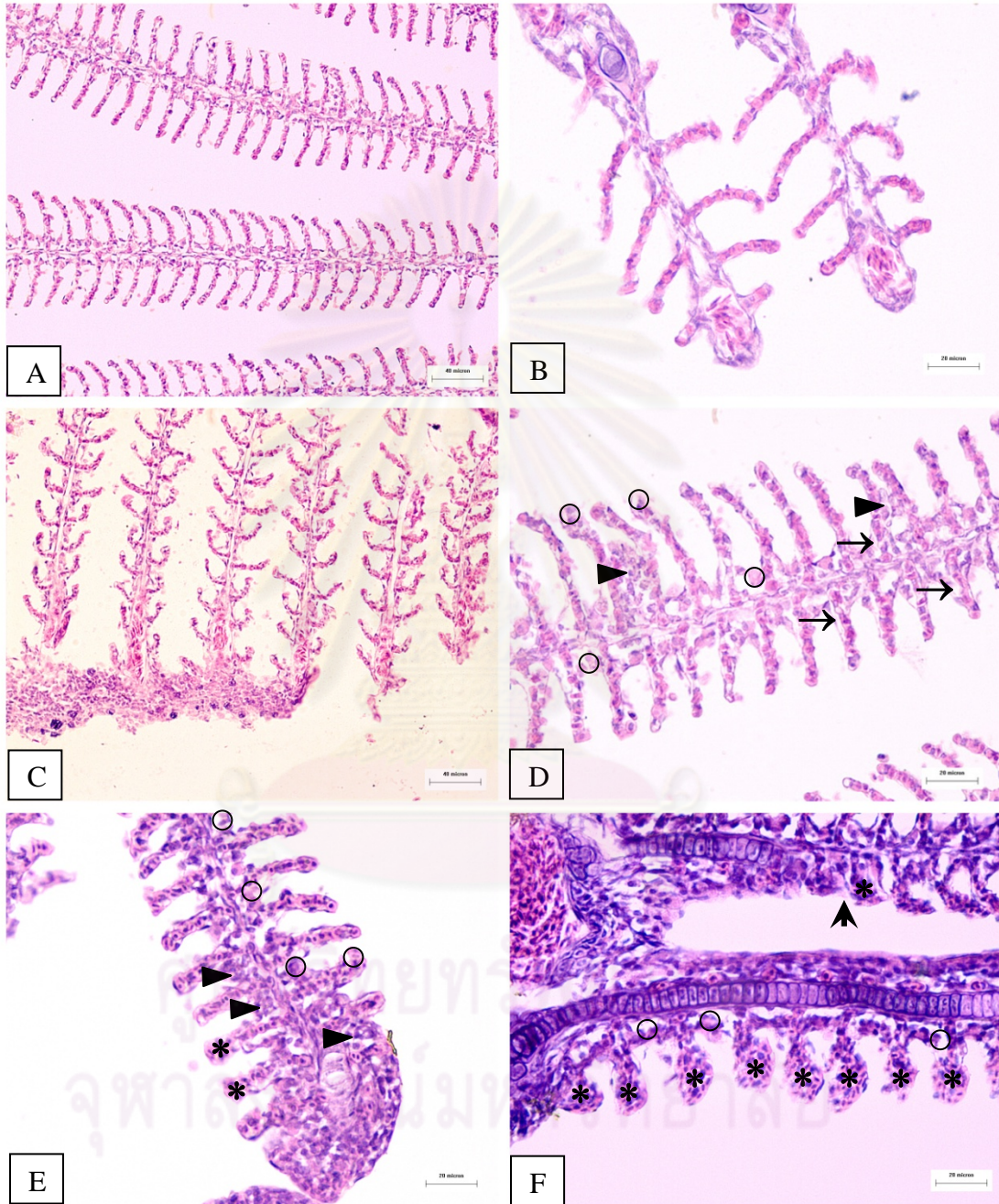


Figure 4-8

Photomicrograph of recovery liver of guppy *Poecilia reticulata*
(H&E staining)

- A Photomicrograph of control liver shows normal histological structure. Bar: 20 μm .
- B Photomicrograph of treated liver tissue exposed to 0.005 ppm carbofuran in tap water shows pyknotic nucleus (>), cellular necrosis (circle) and cellular swelling (gray arrowhead). Bar: 20 μm .
- C Photomicrograph of treated liver tissue exposed to 0.010 ppm carbofuran in natural water shows delamination of hepatic capsule layer and cellular debris (star). Bar: 20 μm .
- D Photomicrograph of treated liver tissue exposed to 0.025 ppm carbofuran in natural water shows cellular swelling (gray arrowhead) and necrosis (circle). Bar: 20 μm .
- E Photomicrograph of treated liver tissue exposed to 0.040 ppm carbofuran in natural water shows lipid accumulation throughout hepatic plate (dark triangle), pyknosis (>) and cellular necrosis (circle). Bar: 20 μm .
- F Photomicrograph of treated liver tissue exposed to 0.050 ppm carbofuran in tap water shows large lipid droplets fusion (dark triangle), cellular necrosis (circle) and pyknosis (>). Bar: 20 μm .

Figure 4-8

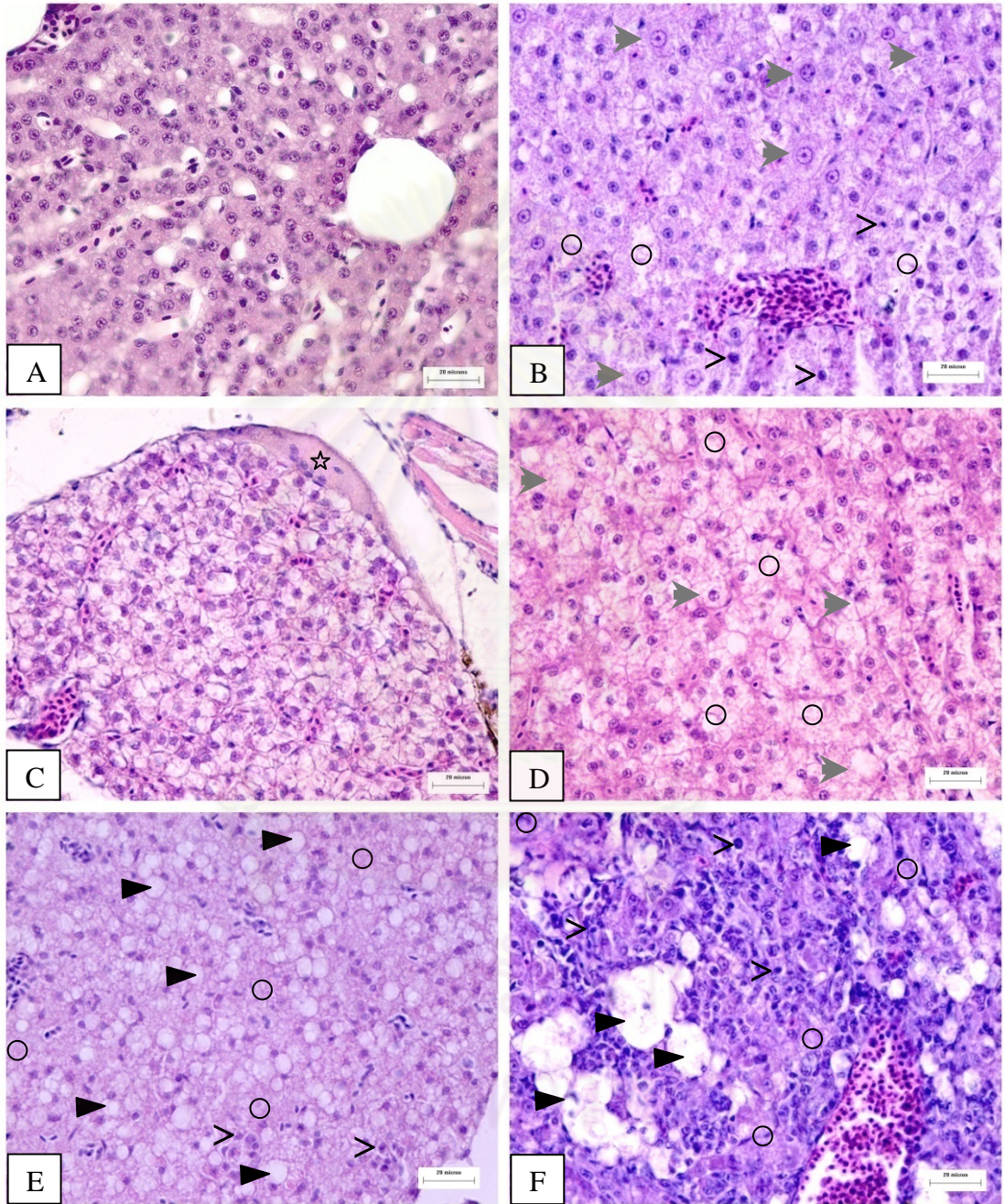


Figure 4-9

Photomicrograph of recovery kidney of guppy *Poecilia reticulata*
(H&E staining)

- A Photomicrograph of control kidney shows normal histological structure. Bar: 20 μm .
- B Photomicrograph of treated kidney tissue exposed to 0.005 ppm carbofuran in natural water shows clumping of blood cell in hematopoietic tissue (circle) and hyaline droplet accumulation (dark triangle). Bar: 20 μm .
- C Photomicrograph of treated kidney tissue exposed to 0.010 ppm carbofuran in natural water shows glomerular dilation (black arrowhead). Bar: 20 μm .
- D Photomicrograph of treated kidney tissue exposed to 0.025 ppm carbofuran in natural water shows pyknotic nucleus in renal tubule (arrow). Bar: 20 μm .
- E Photomicrograph of treated kidney tissue exposed to 0.040 ppm carbofuran in natural water shows glomerular degeneration (black arrowhead) and karyolysis (triangle). Bar: 20 μm .
- F Photomicrograph of treated kidney tissue exposed to 0.050 carbofuran in tap water shows karyolysis (triangle) and cellular debris in renal lumen (star). Bar: 20 μm .

Figure 4-9

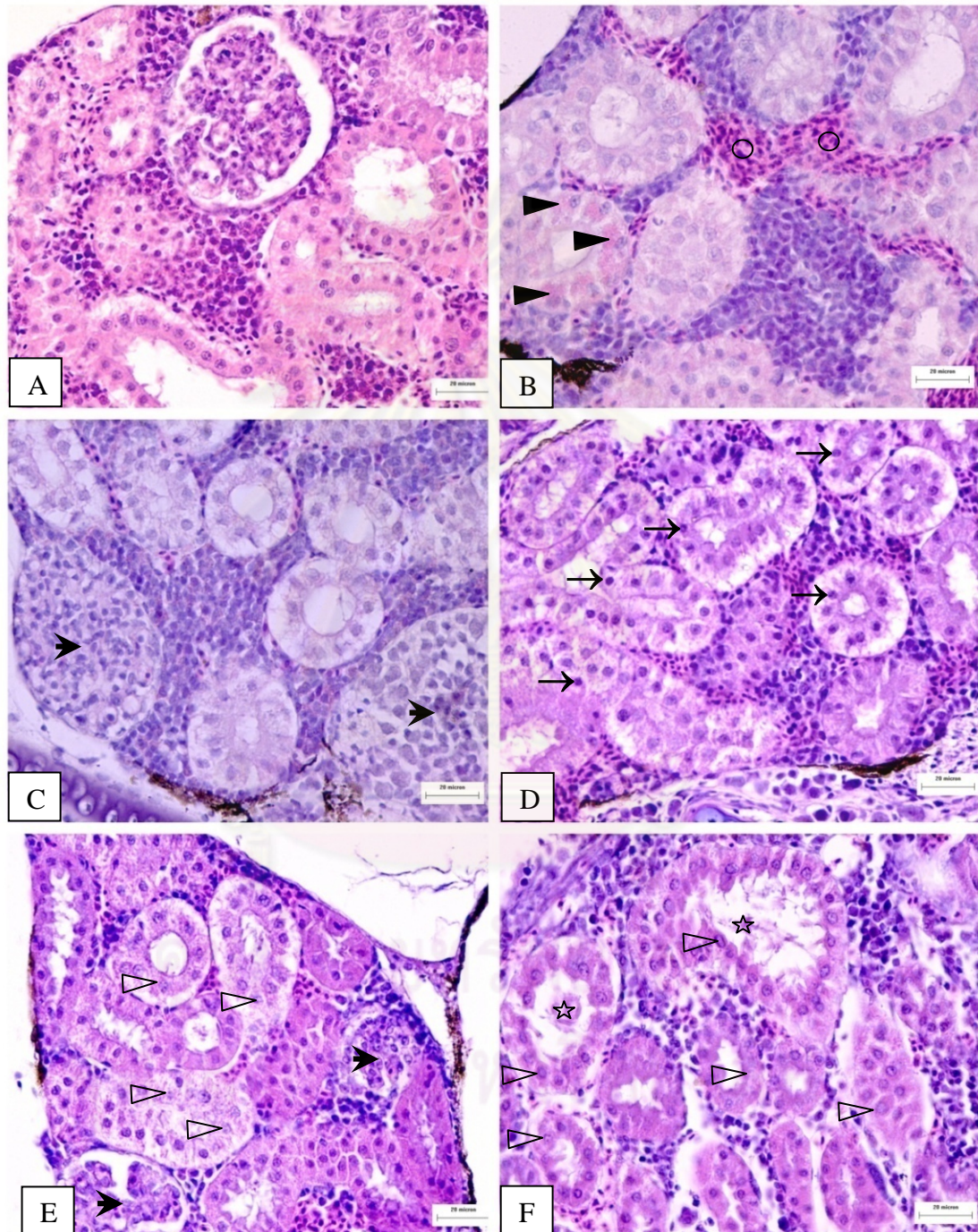


Figure 4-10

Photomicrograph of recovery liver of guppy *Poecilia reticulata*
(Oil Red O staining)

- A Photomicrograph of control liver shows small size of lipid accumulation in hepatocyte. Bar: 20 μm .
- B Photomicrograph of treated liver tissue exposed to 0.005 ppm carbofuran for 96 h shows small size of lipid accumulation in hepatocyte. Bar: 20 μm .
- C Photomicrograph of treated liver tissue exposed to 0.010 ppm carbofuran for 96 h shows small size of lipid accumulation in hepatocyte. Bar: 20 μm .
- D Photomicrograph of treated liver tissue exposed to 0.025 ppm carbofuran for 96 h shows small size of lipid accumulation in hepatocyte. Bar: 20 μm .
- E Photomicrograph of treated liver tissue exposed to 0.040 ppm carbofuran for 96 h shows moderate size of lipid accumulation in hepatocyte. Bar: 20 μm .
- F Photomicrograph of treated liver tissue exposed to 0.050 ppm carbofuran for 96 h shows large size of lipid accumulation in hepatocyte. Bar: 20 μm .

Figure 4-10

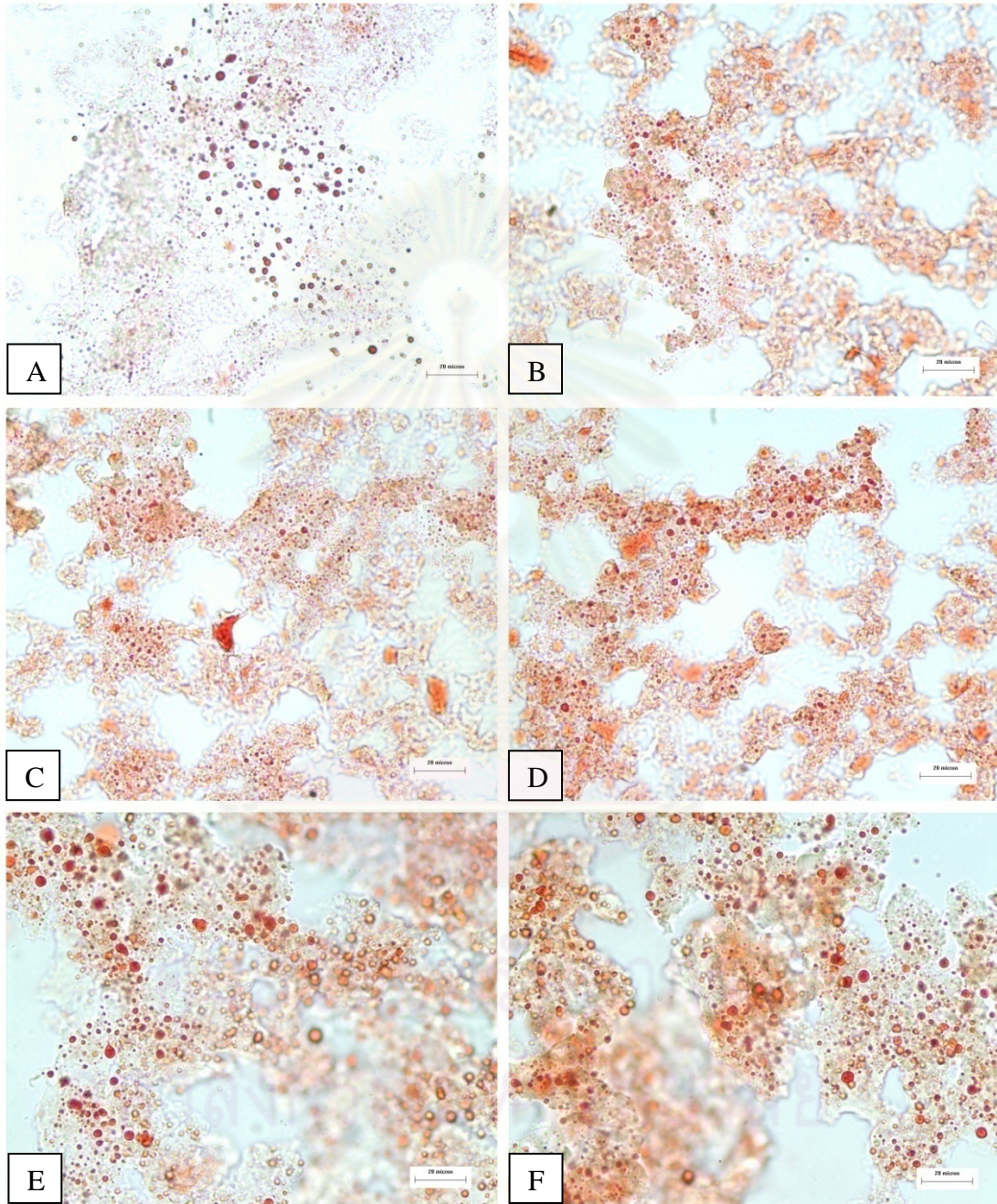


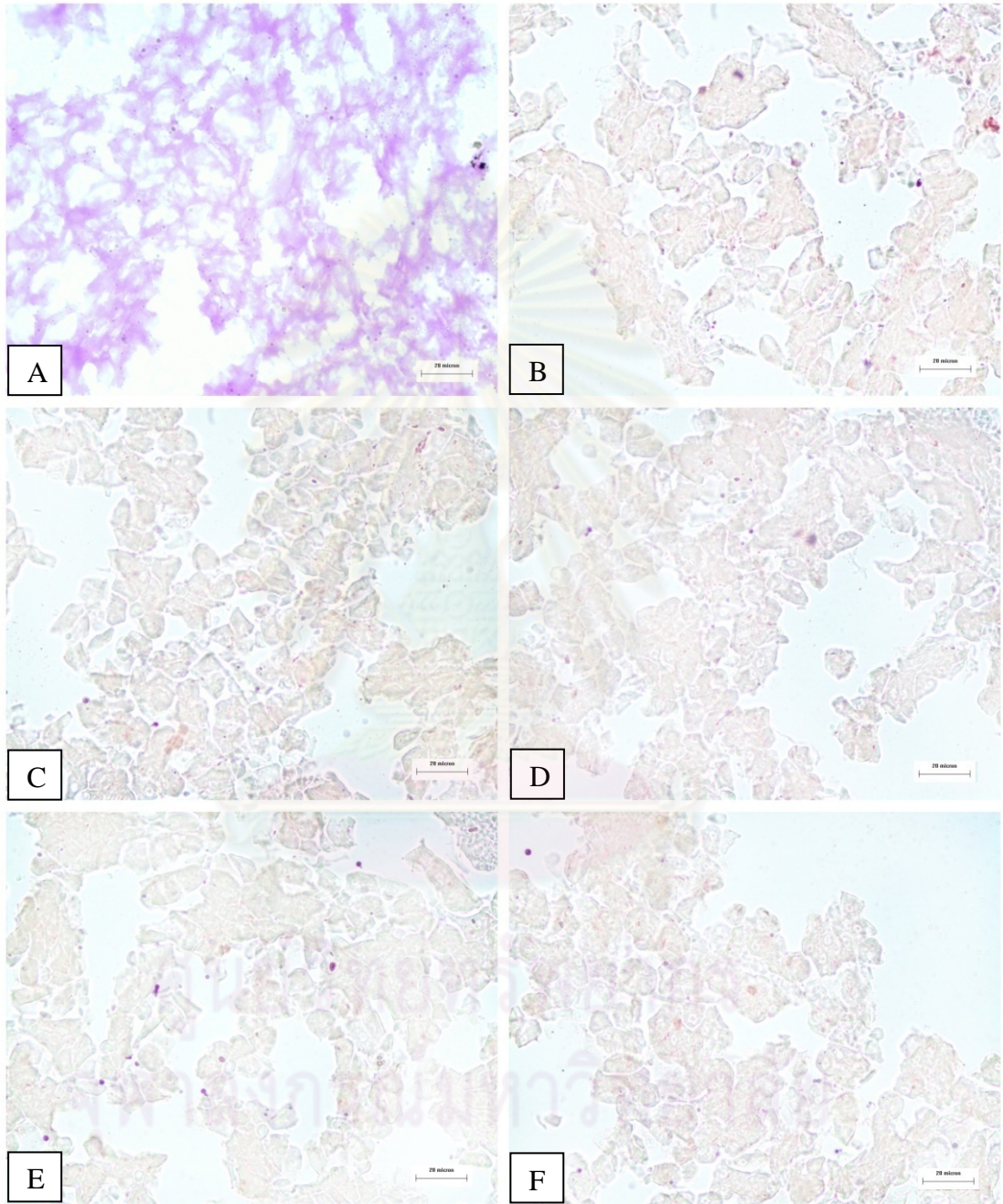
Figure 4-11

Photomicrograph of guppy *Poecilia reticulata* of recovery liver
(PAS staining)

- A Photomicrograph of control liver shows positive PAS staining with pink color. Bar: 20 μm .
- B Photomicrograph of treated liver tissue exposed to 0.005 ppm carbofuran for 96 h shows negative PAS staining with brown color. Bar: 20 μm .
- C Photomicrograph of treated liver tissue exposed to 0.010 ppm carbofuran for 96 h shows negative PAS staining with brown color. Bar: 20 μm .
- D Photomicrograph of treated liver tissue exposed to 0.025 ppm carbofuran for 96 h shows negative PAS staining with brown color. Bar: 20 μm .
- E Photomicrograph of treated liver tissue exposed to 0.040 ppm carbofuran for 96 h shows negative PAS staining with brown color. Bar: 20 μm .
- F Photomicrograph of treated liver tissue exposed to 0.050 ppm carbofuran for 96 h shows negative PAS staining with brown color. Bar: 20 μm .

ศูนย์วิจัยทรัพยากร
จุฬาลงกรณ์มหาวิทยาลัย

Figure 4-11



CHAPTER V

HISTOPATHOLOGY OF GUPPY *Poecilia reticulata* Peters AFTER LONG-TERM EXPOSURE TO SUBLETHAL CONCENTRATION OF CARBOFURAN

5.1 INTRODUCTION

Although application of carbofuran is indispensable because of its beneficial effects on agriculture, its potential threat to the environment cannot be ignored (Malins and Ostrander 1991). Even though carbofuran tends to degrade rapidly in the nature, repeated contamination into the aquatic system may result in adverse effects on non target organisms (De Silva and Samayawardhena, 2002). Histopathology is a necessary and powerful technique in toxicological studies. It performed for the purpose of risk assessment (Wester and Canton, 1991; Nielsen and Baatrup. 2006). Interruption of living processes at the cellular and subcellular levels of biological organization by carbofuran can lead to cell damages (Pacheco and Santos, 2002). The exposure of carbofuran can induce a number of lesions and injuries to different fish organs (Oliveira-Ribeiro et al., 2006). The gill, liver and kidney represent the important target organs suitable for histopathological examination in searching for damages to tissues and cells (Campbell, 1997; Melaa et al., 2007). Moreover, bioindicators of the health of individual fish included histology of gonad, which are particularly sensitive to a variety of environmental contaminants, are also included (Vos et al., 2000; Ilaria et al., 2003). The adverse effects can be reversible in some organs after short-term exposure. However, in the case of repeated or prolonged exposure, chronic morphological alterations can take place (Bender, 1969).

The majority of researches observed with carbofuran insecticides were based on their lethal effects. However, an early warning about the harmfulness of these

compounds, knowledge of the sublethal effects and their ecological implications were important. Therefore, this study was aimed to investigate the sublethal effects of carbofuran on the gill, liver, kidney and gonad of guppy *Poecilia reticulata* after long-term exposure by observing the histopathological effects continuously for 5 months.

5.2 MATERIALS AND METHODS

5.2.1 *Experimental animal*

Guppies (average total length 1.1 ± 0.1 cm) at the age of 15 days post partum were maintained under laboratory conditions (12h light: 12h dark photoperiod, water temperature $27-30^{\circ}\text{C}$). The fish were acclimatized in 12-L glass aquarium in dechlorinated tap water with aeration prior to the experiment. During the experiment, they were maintained on 12h light: 12h dark photoperiod and water temperature was $27-30^{\circ}\text{C}$. The fish were fed twice a day with commercial guppy food (See-All Aquariums Co., Ltd.).

5.2.2 *Experimental chemical*

The carbofuran (Furadan 3G) contains 3% (w/w) active ingredient used in this experiment. Carbofuran was dissolved in DMSO before diluting into water to obtain the final concentration in the experimental aquarium. The long-term concentration in this experiment was 0.04 ppm.

5.2.3 *Experimental design*

The treatment aquarium was filled with carbofuran solution at concentration of 0.04 ppm. While two control aquaria were filled with uncontaminated water and DMSO solution. Each aquarium was contained 100 fish. The exposure was carried out continuously for 5 months. The static renewal system was used throughout the experiment. During the exposure period, twenty fish of both control and treatment groups were collected every month for 5 months. The total length and body weight of each fish were measured. After that, the fish were fixed in 10% buffered formalin.

5.2.4 Histological study

For histology, the samples were prepared by standard paraffin technique. Following fixation, the tissue was dehydrated in graded alcohol solution of 70, 90, 95 and n-butanol, respectively. The tissue was cleared in xylene and embedded in paraffin. Then the sample was cut at 6 μm by rotary microtome and the sections were stained with hematoxylin and eosin (Gurr, 1969). The histological study was observed in gill, liver, kidney and gonad.

5.2.5 Histochemical study

For histochemistry, the freezing method was used for detection of fatty and glycogen degeneration in liver tissues. The tissues were embedded in the frozen medium (Tissue-Tek[®] OCT compound, Sakura). The samples were cut at 6 μm by cryostat microtome. After that, the sections were stained with PAS (Culling, 1963; Gurr, 1969). Another group of the sections were stained Oil Red O (Culling, 1963; Gurr, 1969).

5.2.6 Data analysis

5.2.6.1 Growth rate

Kruskal-Wallis One Way Analysis of Variance on Ranks followed by Dunn's Method was used to compare the differences between the mean of body weight of control, DMSO solvent control and treatment group ($P < 0.05$).

5.2.6.2 Histological analysis

Fifteen guppies were randomly selected from the treatment, control, DMSO solvent control groups in each month. Approximately ten sections were observed from each fish. Therefore, one hundred fifty sections per month in each group were observed the histopathology. All sections were analyzed by light microscope. According to Zodrow, Stegeman and Tanguay (2004) and Frias-Espericueta et al. (2008), the histopathological lesions were determined based on severity of changes compared to control sections. The degree of histological alteration observed in each group were scored according to the

percentage of the total fields with histological damage found per the total observed in the samples of each group (-, no tissues damage in any field on the slides; +, mild histological damage presented < 25% of the fields on the slides; ++, moderate histological damage presented 26%-50% of the fields on the slides; +++, strong histological damage presented 51%-75% of the fields on the slides and +++++, extreme histological damage presented 76% - 100% of the fields on the slides).

5.2.6.3 Histochemical analysis

Five guppies were selected from each treatment and control groups. Approximately ten sections were observed from each fish for analysis. The sections were divided into two groups for studying glycogen composition and lipid composition. Therefore, twenty-five sections were observed in each group. The lipid accumulation in liver tissues per 100 μm^2 was calculated by Image-Pro express version 4.5.1.3. The mean and standard error of lipid accumulation were calculated. Kruskal-Wallis One Way Analysis of Variance on Ranks followed by Dunn's Method at $P < 0.05$ was used to compare the differences between control and treatment groups.

5.3 RESULTS

5.3.1 Growth rate

The mean body weight of both control groups and treatment group in each month is shown in Table 5-1. From statistical analysis, the mean body weight between control and DMSO solvent control was not different in every month ($P < 0.05$). Besides, the mean body weight of treatment group in the 1st month was not different comparing with the control groups ($P < 0.05$). On the other hand, the mean body weight of treatment group in the 2nd, 3rd, 4th and 5th month of both male and female was significantly lower than that of the control groups ($P < 0.05$).

5.3.2 Gill

5.3.2.1 Control gill tissues

The gill arch contained several gill filaments or primary lamellae. The primary lamellar was covered by stratified squamous epithelium. This region contained the mucous cells and chloride cells. Chloride cells were identified as large epithelial cells with lightly stained cytoplasm and they presented at the base of lamellar. Two rows of secondary lamellar or respiratory lamellar ran laterally along each gill filament. The secondary lamellar was lined by a squamous epithelium. In the secondary lamellar, blood sinuses were separated by pillar cells. Generally, one or two erythrocyte were found inside each blood space of secondary lamellar (Figure 5-1).

5.3.2.2 Treated gill tissues

After 1 month of exposure, the histological changes were observed in mild degree consisting of blood congestion in primary and secondary lamellar and dilation of blood vessels. Secondary lamellar shortening and fusion, epithelium necrosis and rupture of pillar cell system were detected in mild degree. Additionally, hyperplasia and hypertrophy were found in mild degree. The moderate degree of epithelial delaminates and edema was observed. Moreover, the curling of secondary lamellar and aneurism were marked (Figure 5-1).

After 2 months of exposure, gill exhibited mild degree of blood congestion in secondary lamellar, epithelial delaminate and edema, secondary lamellar fusion and hyperplasia. Moreover, the epithelial necrosis was marked in moderate degree (Figure 5-2).

After 3 months of exposure, the treated gills showed mild degree of blood congestion in secondary lamellar and epithelial delaminate and edema. The mild degree of hyperplasia and epithelial necrosis was found (Figure 5-3).

After 4 and 5 months of exposure, the gills still exhibited mild degree of epithelial delaminates, edema and epithelial necrosis (Figure 5-4).

5.3.3 Liver

5.3.3.1 Control liver tissues

No abnormality was observed in the liver tissues of the fish in control and DMSO solvent control groups. The guppy liver was encapsulated with a thin layer of connective tissue. Two layers of polygonal hepatocytes arranged along the sinusoid in cord-like structure, arraying from the hepatic central vein. The hepatocyte contained a spherical basophilic nucleus with disperse chromatin and a single nucleolus. The cytoplasm of hepatocyte was slightly eosinophilic stained with small lipid droplets (Figure 5-5).

5.3.3.2 Treated liver tissues

After 1 month of exposure, the histological changes was observed in mild degree consisting of constriction of sinusoidal capillaries, hypertrophy and hyperplasia. Amorphous nucleus shape, foci necrosis of hepatic cells and endothelial damage were found in mild degree. Strong degree of blood congestion in sinusoid and blood vessels were noticed. The hepatic capsule lining showed normal structure (Figure 5-5).

After 2 months of exposure, the treated livers exhibited mild degree of constriction of sinusoidal capillaries, hypertrophy and hyperplasia. Mild degree of foci necrosis and endothelial damage were found. Moreover, moderate degree of blood congestion in sinusoid and central vein and amorphous nucleus shape were noticed (Figure 5-6).

After 3 months of exposure, the livers showed mild degree of constriction of sinusoidal capillaries, hypertrophy and hyperplasia. Diffuse necrosis and fibrosis in necrotic areas were noticed in mild degree. Furthermore, mild degree of macrophage infiltration and detachment of epithelial lining of blood vessels were noticed.

Inflammation in hepatic parenchyma was characterized by macrophage infiltration. Moderate degree of blood congestion, amorphous nucleus shape and foci necrosis were found. The basophilic areas, cellular debris in blood vessels and liver capsule lining rupture were noticed (Figure 5-7).

After 4 months of exposure, the livers showed hyaline deposition in cytoplasm of hepatocytes in mild degree. Constriction of sinusoidal capillaries, blood congestion, hypertrophy and hyperplasia were detected in mild degree. Diffuse necrosis, macrophage infiltration in hepatic parenchyma and detachment of epithelial lining of blood vessels were noticed. Besides, amorphous nucleus shape and fibrosis in necrotic areas were found in moderate degree. Foci necrosis was observed in strong degree. The sloughing and thickening of blood vessel endothelium, peripheral cytoplasm, cellular debris in blood vessels and liver capsule rupture were marked (Figure 5-8).

After 5 months of exposure, treated livers of guppy showed similar alterations as those observed in previous month. The alterations consisted of mild degree of hyaline deposition, hyperplasia, diffuse necrosis, macrophage infiltration and endothelium of blood vessel damage. Additionally, moderate degree of constriction of sinusoidal capillaries, hypertrophy and fibrosis were still found. Strong degree of amorphous nucleus shape was shown. Moreover, foci necrosis was detected in extreme degree. The lipid droplet accumulation dispersed throughout hepatic parenchyma. In this month, the hepatocytes became irregular, loss their polygonal shape, nuclear enlargement and perinuclear clumping were displayed (Figure 5-9).

5.3.4 Kidney

5.3.4.1 Control kidney tissues

The kidney of guppy was composed of nephron unit and glomerulus. The renal corpuscle consisted of Bowman's capsule, a double layered epithelial structure. The glomerulus composed of numerous capillaries. The renal tubules composed of proximal

tubule and distal tubule. A dense luminal brush border of microvilli increasing the surface of the apical membrane was the characteristic of the proximal tubule. Moreover, it was lined by columnar cells. The distal tubule was lined by low columnar or cuboidal cells (Figure 5-12).

5.3.4.2 Treated kidney tissues

After 1 month of exposure, the histological changes in kidney were found in mild degree consisting of hydropic swelling in tubular cells, Bowman's capsule rupture and cellular debris in lumen. Ultimately, pyknosis, karyolysis and hyaline accumulation in renal tubular cells were detected in mild degree (Figure 5-12).

After 2 months of exposure, mild degree of Bowman's capsule rupture and glomerular shrinkage was found. Pyknosis, karyolysis and hyaline accumulation in renal tubular cells were still detected in mild degree. However, hydropic swelling of tubular cells was exhibited in moderate degree. The debris resulting from necrotic degeneration of tubular epithelium was presented (Figure 5-13).

After 3 months of exposure, the treated kidney showed mild degree of cellular debris in lumen, karyolysis and hyaline droplet accumulation in cytoplasm. In addition, hydropic swelling, Bowman's capsule rupture, glomerular shrinkage and pyknosis were shown in moderate degree. Degeneration of epithelial cells in renal tubules and pyknotic nucleus in the hematopoietic tissues were shown (Figure 5-14).

After 4 months of exposure, the kidney tissues showed mild degree of hypertrophy, cellular debris in lumen, karyolysis and hyaline accumulation. Hydropic swelling, Bowman's capsule rupture and pyknosis of renal cells were noticed in moderate degree. The prominent lesion in this month was glomerular shrinkage in strong degree. The lumen contained scattered cellular debris. Tubules were separated and sloughing of tubular epithelial cell in to the lumen (Figure 5-15).

After 5 months of exposure, the alteration observed in mild degree as cellular debris in lumen. Hydropic swelling, Bowman's capsule rupture, pyknosis, karyolysis and hyaline droplet deposition were found in moderate degree. Moreover, extreme degree of glomerular degeneration was found. The important change found in this month was large empty Bowman's capsule space resulting from shrinkage of glomerulus. Dilation of glomerulus and necrosis of renal tubules were displayed in some areas. Besides, sloughing of tubular epithelial cell in to the lumen was shown (Figure 5-16).

5.3.5 Gonad

5.3.5.1 Control gonadal tissues

5.3.5.1.1 Testis

The seminiferous lobules contained the cysts with different spermatogenic stages of germ cells. The spermatogonia were located at the periphery of the testis, where they were associated with Sertoli cells. The spermatogonia transformed into primary spermatocytes. The secondary spermatocytes in the cysts transformed into spermatids which differentiated into spermatozoa. The heads of the spermatozoa became attached to the inner margin of the Sertoli cells lining the cysts. From the experiment, the 1st and 2nd month of control guppy, the testis had only spermatogonia and spermatocytes in the cysts while the 3rd to 5th month of guppy testes showed all stages of spermatogenesis including spermatogonia, spermatocytes, spermatid and spermatozoa (Figure 5-17).

5.3.5.1.2 Ovary

Growth and differentiation of the oocytes in the ovary of *Poecilia reticulata* Peters was a continuous process. The oogenesis was divided into 6 stages. **Oogonial stage**, the nucleus of the oogonium was large with one prominent nucleolus. **Chromatin nucleolar stage**, oocyte enlarged in size with large nucleolus and small volume of basophilic cytoplasm. The follicular membrane surrounding the oocyte was distinguished at this stage. **Perinucleolar stage**, oocyte increased in size with

perinucleolar nucleoli. The follicular wall made up of two layers comprising the inner granosa cells and the outer theca cells. *Cortical alveolar stage*, oocyte increased in the size and its cytoplasm contained various cortical alveoli. *Vitellogenic stage*, oocyte extensively increased in size and deposited yolk materials. *Ripe stage*, oocyte was large and filled with yolk. At the same time the nuclear membrane became irregular and indistinct. From the histological study, in the 1st and 2nd month of guppy ovaries found only oogonial stage, chromatin nucleolar stage and perinucleolar stage. In the 3rd to 5th month of guppy ovary, all stages of oogenesis comprising oogonial stage, chromatin nucleolar stage, perinucleolar stage, cortical alveolar stage, vitellogenic stage and ripe stage were found (Figure 5-19).

5.3.5.2 Treated gonadal tissues

5.3.5.2.1 Treated testis tissues

After 1 and 2 months of exposure, the seminiferous lobule had spermatogonia and spermatocytes in cysts. The histology in testis were found in mild degree of degeneration of Leydig cells and loss of supporting cells between the cysts (Figure 5-18).

After 3 months of exposure, the seminiferous lobule spermatogenesis including spermatogonia, spermatocytes, spermatids and spermatozoa. The histological changes were loss of supporting cells and degeneration of Leydig cells in moderate degree. The hypertrophy of Sertoli cells was detected in mild degree (Figure 5-18).

After 4 months of exposure, all stages of spermatogenesis were observed. Testicular tissues were frequently showed degeneration of Leydig cells, loss of supporting cells between cysts and hypertrophy of Sertoli cells. Necrosis of germ cells at different spermatogenetic stages was found in mild degree. Moreover, macrophage infiltration in necrotic areas of testicular tubules was displayed (Figure 5-18).

After 5 months of exposure, testicular tissues showed strong degree of degeneration of Leydig cells and loss of supporting cells between cysts. Moderate degree of hypertrophy of Sertoli cells and mild degree of degeneration of the cysts were detected. Moreover, macrophage infiltrations in seminiferous lobules were found. The clumping of spermatozoa in the cysts was found and the head of spermatozoa did not embedded in basement membrane of the cysts (Figure 5-18).

5.3.5.2.1 Treated ovary tissues

After 1 and 2 months of exposure, the ovary contained germ cells in oogonial stage, chromatin nucleolar stage and perinucleolar stage. The histological changes were found in mild degree of enlargement of space between oocytes or loss of connective tissues between oocytes (Figure 5-19).

After 3 months of exposure, germ cells in the ovaries were found in oogonial stage, chromatin nucleolar stage, perinucleolar stage, cortical alveolar stage and vitellogenic stage. The histopathology showed the loss of connective tissues between oocytes in moderate degree and degeneration of oocytes in mild degree. In addition, the breakdown of follicular layer and abnormality of oocyte shape were marked (Figure 5-19).

After 4 months of exposure, all stages of oocyte were found. The histological examinations of ovaries showed degeneration of connective tissues between oocytes and degenerating ovarian follicles (atretic) in mild degree. Infiltration of macrophage in necrotic areas of ovary tissues was exhibited. Moreover, loss of yolk granule in cytoplasm of oocytes in vitellogenic stage was observed (Figure 5-19).

After 5 months of exposure, the histological examinations of ovaries showed degeneration of connective tissues between oocytes and degenerating ovarian follicles

in strong degree. Infiltrations of macrophage in necrotic areas of ovary and loss of yolk granule in cytoplasm of oocytes in vitellogenic stage were observed (Figure 5-19).

5.3.6 Histochemical study

5.3.6.1 Control liver tissues

From control and DMSO solvent control livers, the Oil Red O staining showed the red droplets of lipid in cytoplasm of liver cells. The small size lipid droplets were distributed throughout the liver tissues. The mean of lipid accumulation in control liver from the 1st to 5th month were 2.661 ± 0.092 , 3.140 ± 0.047 , 3.401 ± 0.066 , 5.258 ± 0.112 and $5.480 \pm 0.110 \mu\text{m}^2$ per $100 \mu\text{m}^2$, respectively (Appendix C, Table 1-C). Moreover, the mean lipid accumulation in DMSO solvent control liver from the 1st month to 5th month were 2.648 ± 0.104 , 3.194 ± 0.052 , 3.397 ± 0.055 , 5.180 ± 0.170 and $5.510 \pm 0.121 \mu\text{m}^2$ per $100 \mu\text{m}^2$, respectively (Appendix C, Table 1-C and Figure 5-10).

The PAS staining technique for glycogen accumulation of control and DMSO solvent control groups from the 1st to 5th month showed pinkish color. It indicated that both control groups accumulated glycogen in the liver tissues (Figure 5-11).

4.3.6.2 Treated liver tissues

Histochemical study of the treated livers showed large size and more number of lipid droplets than control liver. The mean lipid accumulation in treatment groups were 2.949 ± 0.088 , 3.563 ± 0.099 , 4.134 ± 0.067 , 7.377 ± 0.090 and $7.419 \pm 0.079 \mu\text{m}^2$ per $100 \mu\text{m}^2$ in the 1st to 5th month, respectively (Appendix C, Table 1-C). The mean of lipid accumulation in treatment group of the 1st month was not different comparing with control groups ($P < 0.05$). While, the mean of lipid accumulation of treatment group from the 2nd to 5th month was significantly increased comparing with control groups ($P < 0.05$) (Figure 5-10 and Graph 5-1).

The PAS staining technique showed brownish color of hepatic plate at all concentrations. It indicated that in treatment groups did not process glycogen accumulation in the liver tissues (Figure 5-11).

5.4 DISCUSSION

Although the water was contaminated with low concentration of carbofuran, the reduction of growth rate and histopathological changes in crucial organs of the fish were observed. The growth rate of guppy in this study was significantly decreased in treatment group. These results might be related to the decrease in feeding rate or energy assimilation. It could lead to a reduction in resource for growth, reproduction and survival. Carbofuran induced the decrease of biochemical reserves such as glycogen, proteins, triglycerides and cholesterol resulting in the decrease in growth (Dutra, Fernandes and Oliveira, 2008). Moreover, the decrease in protein content might be reduced formation of lipoprotein, which used to repair damaged cells and tissues (Dutra, Fernandes and Oliveira, 2008). Furthermore, carbofuran produced oxidative stress, which led to alterations in the membrane structure and functions. These effects might associate with retarding the growth in organism (Milatovic et al., 2005; Kamboj, Kiran and Sandhir, 2006a; Dutra et al., 2009).

Although no mortality occurred during the experimental period, the histopathological lesions were observed in gill, liver kidney and gonad of guppy. The tissue damages and their severity after exposure to carbofuran were summarized in Table 5-2 to 5-6. In the present study, the gills were not significantly affected in long-term, in contrast to the numerous lesions reported in short-term experiments. According to Richmonds and Dutta (1989), they divided the gill lesions into two groups including the direct effects of the toxicants and the defence responses of the fish. The results of epithelial necrosis and blood congestion were direct responses induced by carbofuran. The defence responses were the lifting of the gill epithelium, hyperplasia, lamellar shortening and fusion. These processes retarded and diminished carbofuran uptake

(Mallatt, 1985; Alazemi, Lewis and Andrew, 1996; Lease et al., 2003; Mustafa, Belda and Seda, 2003; Aysel, Gulden and Ayhan, 2008). Several studies were reported similar results of the gill lesions after exposure to other insecticides. *Channa punctatus* after exposed to deltamethrin showed desquamation, necrosis, delaminate of the lamellar epithelium and edema (Sayeed et al. 2003; Cengiz, 2006). The delaminate of epithelial layer, necrosis, edema, the shortening of secondary lamellar and club-shaped lamellar in the gills of *L. reticulatus* exposed to cyphenothrin were reported (Erkmen, Aliskan and Yerli, 2000). *L. macrochirus* exposed to diazinon showed delaminate of the epithelial layer, hyperplasia, necrosis and shortening of secondary lamellar (Dutta, Richmonds and Zeno, 1993).

The studies in some fish exposed to pesticides under laboratory conditions showed that liver was an organ that accumulates highest pesticide concentration (Hinsen et al., 1971). Similarly in the present study, the liver displayed the highest prevalence of histological changes in more severity after exposure to carbofuran. The hypertrophy or the cellular swelling was corresponded with the increase in cell size. Different degrees of cellular swelling might show the different physiopathological situation, ranging from adaptive to pathological changes (Del Monte, 2005). Hypertrophy and vacuolation might be associated with fat accumulation or accompanied by the intracellular accumulation of stress proteins (Wester and Canton, 1987; Del Monte, 2005). In addition, cellular swelling might occur either directly by denaturation of volume-regulating ATPases or indirectly by disruption of the cellular energy transfer processes required for ionic regulation (Hinton and Lauren, 1990). The vacuolization of cells resulted in nuclear degeneration, constriction of sinusoid and hepatic cord disarray. The large vacuole in the cell forced the nucleus to the periphery and this condition was usually accompanied by nuclear atrophy.

The sinusoid damage, the endothelium of blood vessel thickening and rupture were frequently observed after exposure to carbofuran. The sinusoid was a specialized

capillary with numerous fenestrates for high permeability. Dilation of the sinusoid occurred whenever efflux of hepatic blood was impeded. A consequence of endothelial cell injury was the loss of barrier function with extensive blood accumulation in the liver. These disruptions of the sinusoid were considered the early structural features of the vascular disorder (Jaeschke, 2008; Gregus, 2008).

The necrosis with initiation of fibrosis, macrophage infiltration and hyaline accumulation in liver were found after long-term exposure. Chronic inflammation involved a diffuse accumulation of macrophages and lymphocytes at the site of injury. Ongoing chemotaxis caused macrophages to infiltrate the inflamed site, where they accumulated because of prolonged survival and immobilization (Jaeschke, 2008; Gregus, 2008). These mechanisms led to fibroblast proliferation, with subsequent scar formation that in many cases replaces the normal connective tissue (Sommer and Porth, 2006). Hyalinization or hyaline droplet degeneration was the most conspicuous histological characteristic observed in the exposed liver. The appearance of hyaline droplets was the result of disturbances of protein synthesis (Cheville, 1994; Van Dyk, Pieterse and Van Vuren, 2007).

From the histochemical study, the results showed that lipid accumulation in cytoplasm of hepatocytes was significantly increased after exposure to carbofuran. Lipid accumulation was defined biochemically as an appreciable increase in the hepatic lipid (mainly triglyceride) content. Increased lipid content of the liver could be explained by either increased deposition of lipid in excess of nutritional requirements or a failure to mobilise lipid stores during carbofuran toxicity. Moreover, lipid accumulation might be occurred by mitochondrial dysfunctions, which in turn inhibit synthesis of lipoprotein. These were the consequence of an inhibition of apolipoprotein synthesis (Shaw, Richard and Handy, 2006). In the present study, glycogen accumulation in cytoplasm of hepatocytes was not found after exposure to carbofuran. It indicated that glycogen content in liver was decreased by carbofuran. Liver is the principal organ for glycogen

storage (Ghousia, 2004). An enzyme system was presented to bring about the rapid mobilization of glycogen for energy release. Hydrolysis of glucose-6-phosphat was the key step in glycogenesis and in the conversion of liver glycogen to blood glucose (Verma, Sarita and Dalela, 1981). These processes were the production of glucose-1-phosphate from glycogen by the action of glycogen phosphorylase (Morgan and Parmeggiani, 1964). The increased phosphorylase activity in liver tissues of *C. batrachus* exposed to carbofuran confirmed the active breakdown of tissue glycogen. These processes were apparently for metabolic processes to increase energy demand imposed by carbofuran intoxication (Begum and Vijayaraghavan, 2001). Many researchers reported that glycogen deposition in the liver decreased during the insecticide exposure (Ribeiro et al., 2001; Chris et al., 2007). From the histological and histochemical results, disturbance of the homeostasis of an organism led to compensatory, physiological adaptation and finally pathological processes (Gupta, Milatovic and Dettbarn, 2001).

Several studies were reported the hepatotoxicity after long-term exposure to many pesticides. *Channa punctatus* exposed to alachlor showed degeneration of cytoplasm in hepatocytes, atrophy formation of vacuoles, rupture in blood vessels and disposition of hepatic cords (Butchiram, Tilak and Raju, 2009). *Clarias gariepinus* exposed to cypermethrin showed cloudy swelling of hepatocytes, lipid vacuoles, pyknotic nucleus and foci necrosis (Velmurugan, Mathews and Cengiz, 2009). Nile tilapia exposed to alachlor showed hydropic swelling and lipid vacuoles (Peebua et al., 2008). *Heteropneustes fossilis* exposed to cypermethrin showed vacuolization, necrosis and fibrosis of perivascular region (Joshi, Dharmalata and Sahu, 2007). *Cirrhinus mrigala* exposed to fenvalerate showed congestion, cloudy swelling of hepatocytes and foci necrosis (Velmurugan et al., 2007). Similar alterations were observed in the hepatocytes of Nile tilapia exposed to glyphosate herbicide (Jiraungkoorskul et al., 2003) and in white seabass (*Lates calcarifer*) exposed to cadmium (Thophon et al., 2003). Other fish species such as estuarine fish (*Platichthys flesus*, *Pomatoschistus minutus*, and

Zoarces viviparous) captured from contaminated sites also showed these alterations which are often associated with a degenerative-necrotic condition (Stentiford et al., 2003).

In the present study, kidney tissues displayed renal toxicity after long-term exposure to sublethal concentrations of carbofuran. Kidney is one of the major organs of toxic responses. Other studies reported the renal toxicity after exposure to the toxicants. The hyperemia and glomerulonephritis were observed after exposure to ammonia (Aysel, Gulden and Ayhan, 2008). The kidney showed large necrotic areas and phagocytic areas after exposure to methyl mercury (Melaa et al., 2007). Lesions in the kidney tissues of the fish exposed to deltamethrin showed degeneration in the epithelial cells of renal tubule, pyknosis in the hematopoietic tissue, dilation and degeneration of glomerulus (Cengiz, 2006). Hydropic swelling, hypertrophy, pyknosis and accumulation of hyaline droplets occurred after exposure to cadmium (Thophon et al., 2003). The hyaline droplets may represent protein reabsorbed from the glomerular filtrate after contaminated with glyphosate (Jiraungkoorskul et al., 2003). Other fish species exposed to natural petroleum also displayed dilation of blood capillaries in the glomerulus and inflammation (Pacheco and Santos, 2002).

Spermatogenesis took place within the seminiferous lobules of the fish testis. Sertoli cells regulated the development of germ cells by producing vital factors essential for germ cells. Moreover, they transported the nutrient to germ cells, supported and protected the germ cells in the cysts. Therefore, any agent that impaired the viability and the function of Sertoli cells might affect on spermatogenesis (Saradha and Mathur, 2006). The hypertrophy of Sertoli cells in this study might lead to dysfunction or reduction the ability of them. Consequently, it affected on survival, development, quality and quantity of germ cells. In addition, Sertoli cells were associated with spermiation. In these way spermatozoa with head pointing outward and tail in the center was formed. The Sertoli cells surrounding the mature spermatozoa fused with the wall of the efferent

duct. The head of the spermatozoa withdraw from the Sertoli cell lining, the cyst opened, and the spermatozoa passed into the lumen of the efferent duct (Grier, 1981). Hence the hypertrophy of Sertoli cells might affect on spermiation and transfer of spermatozoa into efferent duct cells. The Leydig cell involved in the secretion of androgens, notably testosterone, as well as other steroids including estrogen. The roles of gonadotropins as endocrine regulator of spermatogenesis were well documented (Sharpe and Skakkebaek, 1993). Leydig cell secreted androgens, which bound to receptors in the Sertoli cells. It activated Sertoli cells to produce activin B, which in turn acted on the spermatogonia to induce mitosis (Nagahama, 1994; Nagahama 2000). In the present work, impairment of testicular tissues in carbofuran treatment fish resulting in the reduction of the Leydig cells. It might be responsible for the reduction of steroidogenic activity in the testis as well as for the low levels of the steroid hormones (testosterone, progesterone) in blood plasma. Carbofuran caused the decrease of testosterone levels by reducing its synthesis and release (Clement, 1985; Rhouma et al., 2001; Goad et al., 2004; Srivastava, Yadav and Trivedi, 2008). The reasonably low levels of gonadotropin or androgen possibly explained the arrest in the formation of spermatogenesis as well as necrosis of the various spermatogenic cells. Furthermore, the epididymis was dependent upon androgen stimulation; therefore, any toxic insult to Leydig cell would cause androgen deprivation in blood and rete testis fluid, which would subsequently hamper the epididymal sperm maturation and fertility (Saradha and Mathur, 2006). Therefore, any factor affecting on Leydig cell function could interrupt the endocrine regulation of spermatogenesis and consequently affected the reproductive ability.

In reproductive study, the control ovary showed all stages of oogenesis at the 3rd month while in treated fish the ovary showed all stages of oogenesis at the 4th month. The results indicated that carbofuran retarded the ovarian development and disturbed of egg development. From the histopathological results, the rupture of follicle cells and loss of yolk granules were presented. The rupture of follicle cells might lead to produce and transfer of yolk substance in immature oocytes and the production of yolk with abnormal

appearance. These lesions might be the results of oocyte dysfunction, because these cells were involved in yolk formation. The effects on amount of nutrient stored in the form of vitellogenin could affect the number of offspring produced.

Other studies reported the reproductive toxicity after exposure to other insecticides. Cypermethrin affected on *Heteropneustes fossilis* by decreasing the size of gonadotrophic cells, follicular atresia and loss of ovigerous lamella of ovary (Singh and Singh, 2008). Devicyprin induced testis impairment in *Channa punctatus* (Srivastava, Yadav and Trivedi, 2008). In a previous study on the fish exposed to sub-lethal doses of various contaminants, including OPs, CBs and OC pesticides, ovarian alterations such as smaller diameter of oocytes compared to control fish were reported (Rastogi and Kulshrestha, 1990).

5.5 CONCLUSIONS

Although low concentration of contaminated carbofuran cannot kill small fish like guppy, it affected on growth rate and histopathological lesion in vital organs including gill, liver, kidney and gonad. The sub-lethal effects in important tissues related to the health of guppy. The histological and histochemical results indicated that biochemical alterations were severe enough to lead to structural changes at the tissue level. The severity of gill lesions was decreased with time while the severity of other organs such as liver, kidney and gonad were increased with time. The reproductive toxicity of gonad in the cellular levels may lead to the effect on organismal level in term of fitness and survival. If exposure to carbofuran in the environment extended into longer term, physiological impairment of the individual would increase with increasing prevalence and severity of pathologic changes. This study was thus ecologically relevant, demonstrating the potential routes and toxicological impacts of environmental contaminants to fish.

TABLES, FIGURES AND GRAPHS

Table 5-1 Mean of body weight of guppy *P. reticulata* in control, DMSO solvent control and treatment groups in various month (n=20/month)

Month		Body weight (g)		
		(Mean \pm SE)		
		Control	DMSO control	Treatment
1	-	0.0385 \pm 0.0006	0.0383 \pm 0.0005	0.0379 \pm 0.0010
2	-	0.0951 \pm 0.0033	0.0947 \pm 0.0032	0.0850 \pm 0.0036 *
3	Female	0.1238 \pm 0.0032	0.1218 \pm 0.0021	0.0975 \pm 0.0137 *
	Male	0.1101 \pm 0.0024	0.1108 \pm 0.0028	0.0966 \pm 0.0046 *
4	Female	0.2856 \pm 0.0089	0.2825 \pm 0.0062	0.2545 \pm 0.0072 *
	Male	0.2718 \pm 0.0094	0.2717 \pm 0.0083	0.2517 \pm 0.0047*
5	Female	0.3340 \pm 0.0037	0.3300 \pm 0.0026	0.2873 \pm 0.0054 *
	Male	0.3027 \pm 0.0042	0.3064 \pm 0.0038	0.2811 \pm 0.0067*

Mean with (*) within a row are significantly different ($P < 0.05$).

Table 5-2 The degree of gill histopathological lesions of *P. reticulata* in control, DMSO control and treatment group in various periods (n=150/month).

Lesion	Control	DMSO control	Treatment (Month)				
			M1	M2	M3	M4	M5
Blood congestion in primary lamellar	-	-	+	-	-	-	-
Blood congestion in secondary lamellar	-	-	+	+	+	-	-
Dilation of blood vessels	-	-	+	-	-	-	-
Epithelial delaminate and edema	-	-	++	+	+	+	+
Secondary lamellar fusion	-	-	+	+	-	-	-
Shortening of secondary lamellar	-	-	+	-	-	-	-
Epithelium necrosis	-	-	+	++	+	+	+
Hyperplasia	-	-	+	+	+	-	-
Hypertrophy	-	-	+	-	-	-	-
Rupture of pillar cell	-	-	+	-	-	-	-

- No present, + mild degree, ++ moderate degree, +++ strong degree, ++++ extreme degree

Table 5-3 The degree of liver histopathological lesions of *P. reticulata* in control, DMSO control and treatment group in various periods (n=150/month).

Lesion	Control	DMSO control	Treatment (Month)				
			M1	M2	M3	M4	M5
Hyaline droplet accumulation	-	-	-	-	-	+	+
Constriction of sinusoidal capillaries	-	-	+	+	+	+	++
Blood congestion	-	-	+++	++	++	+	-
Hypertrophy	-	-	+	+	+	+	++
Hyperplasia	-	-	+	+	+	+	+
Amorphous nucleus shape	-	-	+	++	++	++	+++
Foci necrosis	-	-	+	+	++	+++	++++
Diffuse necrosis	-	-	-	-	+	+	+
Necrosis with fibrosis	-	-	-	-	+	++	++
Macrophage infiltration	-	-	-	-	+	+	+
Endothelium of blood vessels damage	-	-	+	+	+	+	+

- No present, + mild degree, ++ moderate degree, +++ strong degree, ++++ extreme degree

Table 5-4 The degree of kidney histopathological lesions of *P. reticulata* in control, DMSO control and treatment group in various periods (n=150/month).

Lesion	Control	DMSO control	Treatment (Month)				
			M1	M2	M3	M4	M5
Hydropic swelling	-	-	+	++	++	++	++
Bowman's capsule rupture	-	-	+	+	++	++	++
Glomerular degeneration	-	-	-	+	++	+++	++++
Cellular debris in lumen	-	-	+	+	+	+	+
Pyknosis	-	-	+	+	++	++	++
Karyolysis	-	-	+	+	+	+	++
Hyaline droplet accumulation	-	-	+	+	+	+	++

- No present, + mild degree, ++ moderate degree, +++ strong degree, ++++ extreme degree

Table 5-5 The degree of testis histopathological lesions of *P. reticulata* in control, DMSO control and treatment group in various periods (n=150/month).

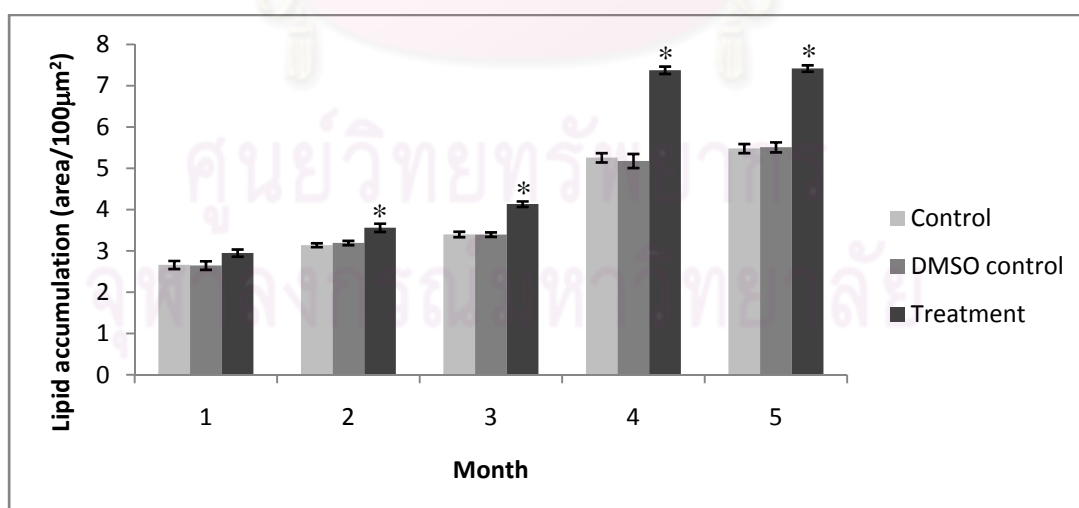
Lesion	Control	DMSO control	Treatment (Month)				
			M1	M2	M3	M4	M5
Degeneration of Leydig cells	-	-	+	+	++	++	+++
Degeneration of cysts	-	-	-	-	-	+	+
Loss of supporting cells	-	-	+	+	++	++	+++
Hypertrophy of Sertoli cells	-	-	-	-	+	++	++

- No present, + mild degree, ++ moderate degree, +++ strong degree, ++++ extreme degree

Table 5-6 The degree of ovary histopathological lesions of *P. reticulata* in control, DMSO control and treatment group in various periods (n=150/month).

Lesion	Control	DMSO control	Treatment (Month)				
			M1	M2	M3	M4	M5
Degeneration of oocytes	-	-	-	-	+	++	+++
Loss of supporting cell	-	-	+	+	++	++	+++

- No present, + mild degree, ++ moderate degree, +++ strong degree, ++++ extreme degree



Graph 5-1 Means of lipid accumulation in hepatocytes of *P. reticulata* in control, DMSO control and treatment groups after exposure of 0.04 ppm carbofuran in various exposure periods (n=20 / month). Mean with (*) is significantly different ($P < 0.05$)

Figure 5-1

Photomicrograph of treated gill of guppy *Poecilia reticulata* at 1 month post-exposure
(H&E staining)

- A Photomicrograph of control gill shows the normal gill structure comprising numerous gill filaments or primary lamellae (*) and secondary lamellae or respiratory lamellae (arrow). Bar: 20 μm
- B Photomicrograph of treated gill tissue shows epithelial delaminate and edema (arrow), epithelium necrosis (circle), hyperplasia (dark triangle) and pillar cell system rupture (gray arrowhead). Bar: 40 μm .
- C Photomicrograph of treated gill tissue shows epithelial delaminate and edema (arrow), epithelium necrosis (circle) and hypertrophy (triangle). Bar: 20 μm .
- D Photomicrograph of treated gill tissue shows secondary lamellar shortening and fusion (black arrowhead), epithelium necrosis (circle) and hyperplasia (dark triangle). Bar: 20 μm .
- E Photomicrograph of treated gill tissue shows secondary lamellar shortening and fusion (black arrowhead), hypertrophy (triangle), hyperplasia (dark triangle) and epithelium necrosis (circle). Bar: 20 μm .
- F Photomicrograph of treated gill tissue shows secondary lamellar shortening and fusion (black arrowhead), hypertrophy (triangle), hyperplasia (dark triangle), epithelium necrosis (circle) and pillar cell system rupture (gray arrowhead). Bar: 20 μm .

Figure 5-1

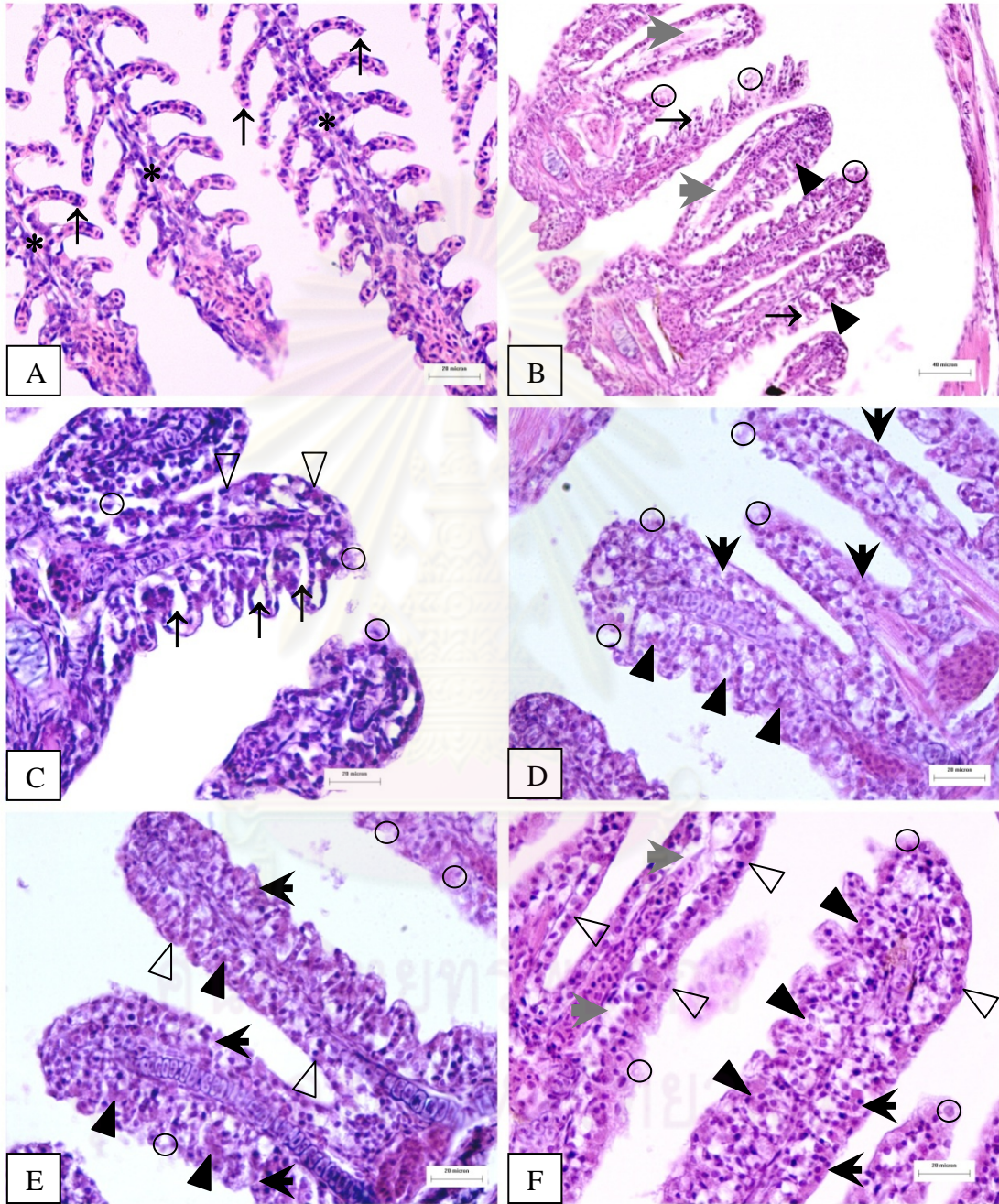


Figure 5-2

Photomicrograph of treated gill of guppy *Poecilia reticulata* at 2 month post-exposure
(H&E staining)

- A Photomicrograph of control gill shows the normal gill histological structures. Bar: 20 μm
- B Photomicrograph of treated gill tissue shows blood congestion in secondary lamellar (*). Bar: 20 μm .
- C Photomicrograph of treated gill tissue shows epithelium necrosis (circle), secondary lamellar shortening and fusion (black arrowhead), hyperplasia (dark triangle), epithelial delaminate and edema (arrow). Bar: 40 μm .
- D Photomicrograph of treated gill tissue shows blood congestion in secondary lamellar (*). Bar: 20 μm .
- E Photomicrograph of treated gill tissue shows blood congestion in secondary lamellar (*), epithelium necrosis (circle), epithelial delaminate and edema (arrow). Bar: 20 μm .
- F Photomicrograph of treated gill tissue shows blood congestion (*), epithelium necrosis (circle) and hyperplasia (dark triangle). Bar: 20 μm .

Figure 5-2

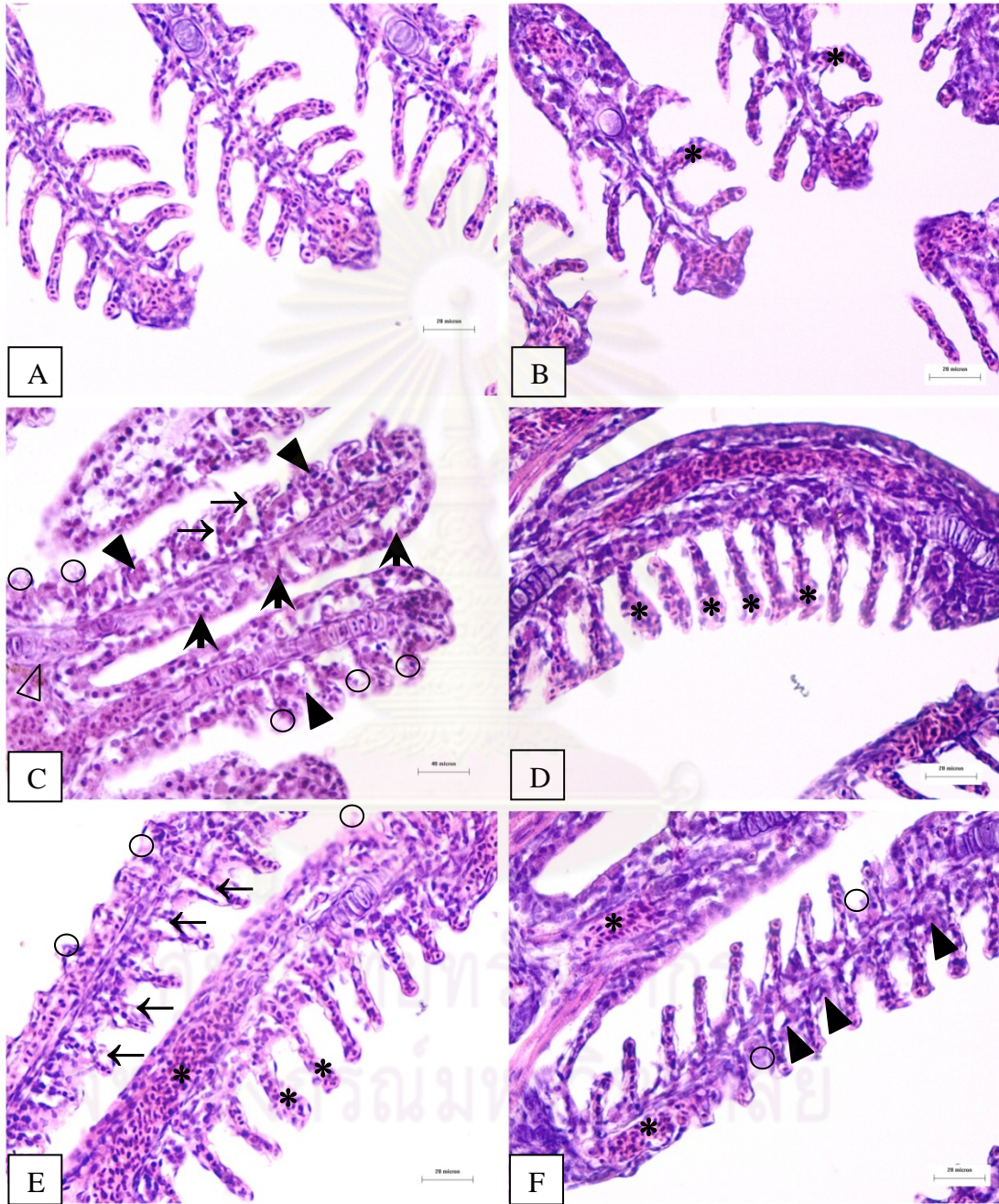


Figure 5-3

Photomicrograph of treated gill of guppy *Poecilia reticulata* at 3 month post-exposure
(H&E staining)

- A Photomicrograph of control gill shows the normal gill histological structures. Bar: 20 μm
- B Photomicrograph of treated gill tissue shows blood congestion in secondary lamellar (*) and hyperplasia (dark triangle). Bar: 40 μm .
- C Photomicrograph of treated gill tissue shows hyperplasia (dark triangle), blood congestion (*) and epithelium necrosis (circle). Bar: 20 μm .
- D Photomicrograph of treated gill tissue shows blood congestion in secondary lamellar (*), hyperplasia (dark triangle) and epithelium necrosis (circle). Bar: 20 μm .
- E Photomicrograph of treated gill tissue shows hyperplasia (dark triangle) and blood congestion (*). Bar: 20 μm .
- F Photomicrograph of treated gill tissue shows blood congestion (*), hyperplasia (dark triangle), secondary lamellar shortening (black arrowhead) and epithelium necrosis (circle). Bar: 20 μm .

Figure 5-3

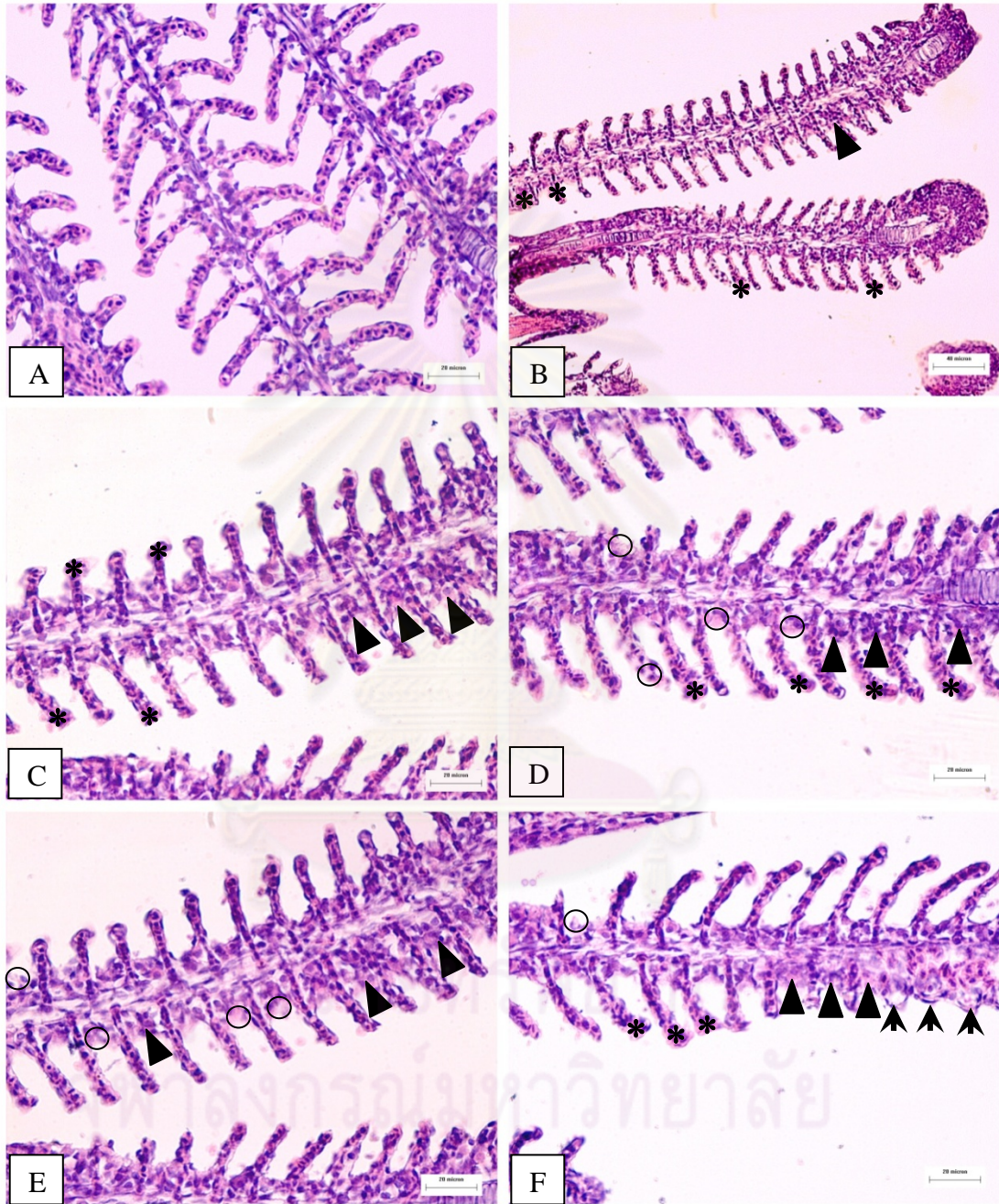


Figure 5-4

Photomicrograph of treated gill of guppy *Poecilia reticulata*
at 4 and 5 month post-exposure (H&E staining)

- A Photomicrograph of control gill shows the normal gill histological structures. Bar: 20 μm
- B Photomicrograph of treated gill tissue at 4 month shows normal gill structures. Bar: 20 μm .
- C Photomicrograph of treated gill tissue at 4 month shows normal gill structures. Bar: 20 μm .
- D Photomicrograph of treated gill tissue at 5 month shows normal gill structures. Bar: 20 μm .
- E Photomicrograph of treated gill tissue at 5 month shows normal gill structures. Bar: 20 μm .
- F Photomicrograph of treated gill tissue at 5 month shows normal gill structures. Bar: 20 μm .

Figure 5-4

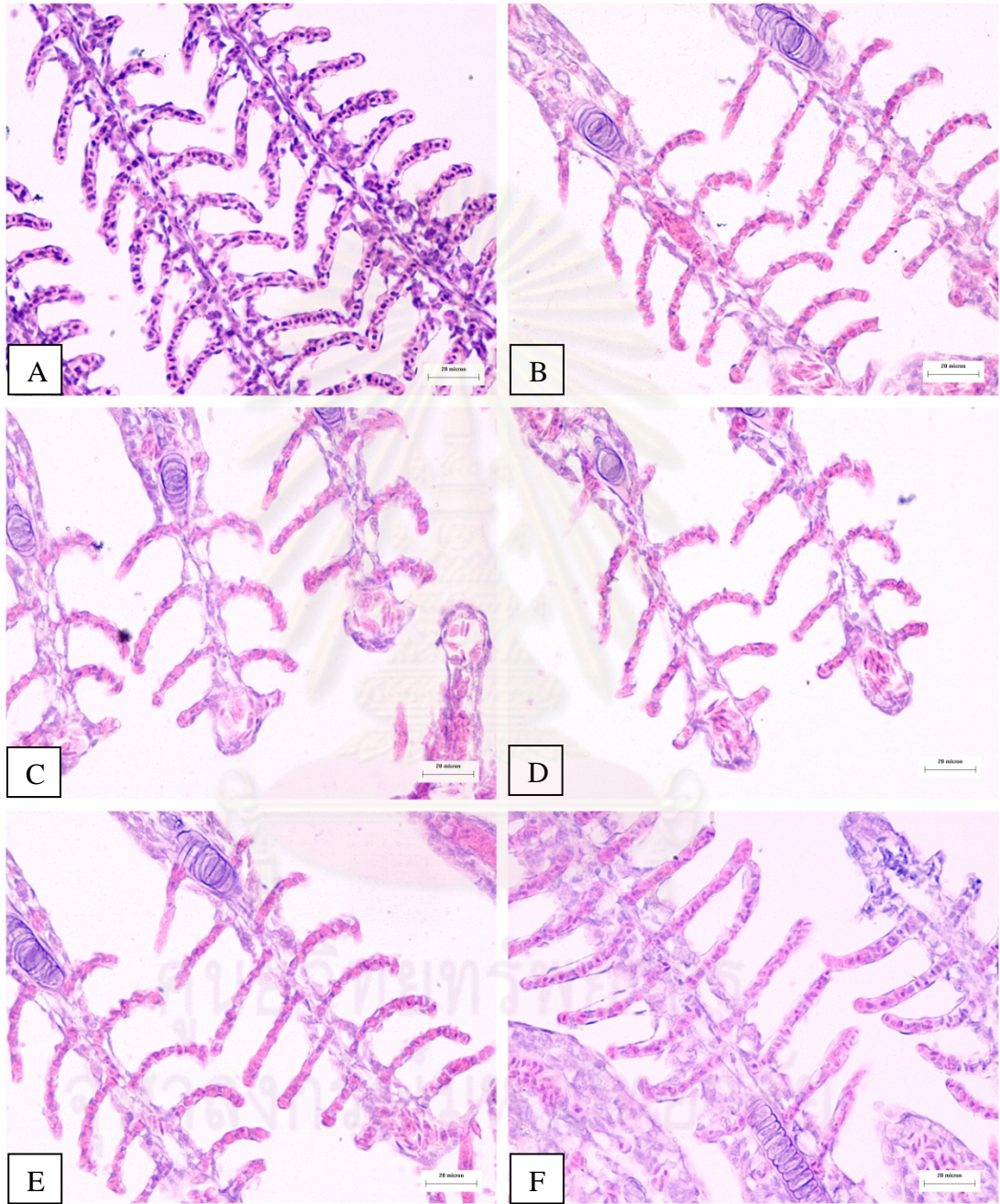


Figure 5-5

Photomicrograph of treated liver of guppy *Poecilia reticulata* at 1 month post-exposure
(H&E staining)

- A Photomicrograph of control liver shows that hepatocytes are located between sinusoid (S). The polygonal hepatic cell (H) has round concentric nucleus with a single nucleolus (arrow). Bar: 20 μm
- B Photomicrograph of treated liver tissue shows hypertrophy (gray arrowhead), pyknotic nucleus (>), endothelium of blood vessel damage (black arrowhead) and necrosis areas (circle). Bar: 40 μm .
- C Photomicrograph of treated liver tissue shows blood congestion (*), hypertrophy (gray arrowhead) and cellular necrosis (circle). Bar: 40 μm .
- D Photomicrograph of treated liver tissue shows hypertrophy (gray arrowhead), amorphous nucleus shape (triangle), cellular necrosis (circle) and lipid accumulation (dark triangle). Bar: 20 μm .
- E Photomicrograph of treated liver tissue shows hypertrophy (gray arrowhead), cellular necrosis (circle), endothelium of blood vessel damage (black arrowhead) and karyolysis (>>). Bar: 20 μm .
- F Photomicrograph of treated liver tissue shows hypertrophy (gray arrowhead) and cellular necrosis (circle). Bar: 20 μm .

Figure 5-5

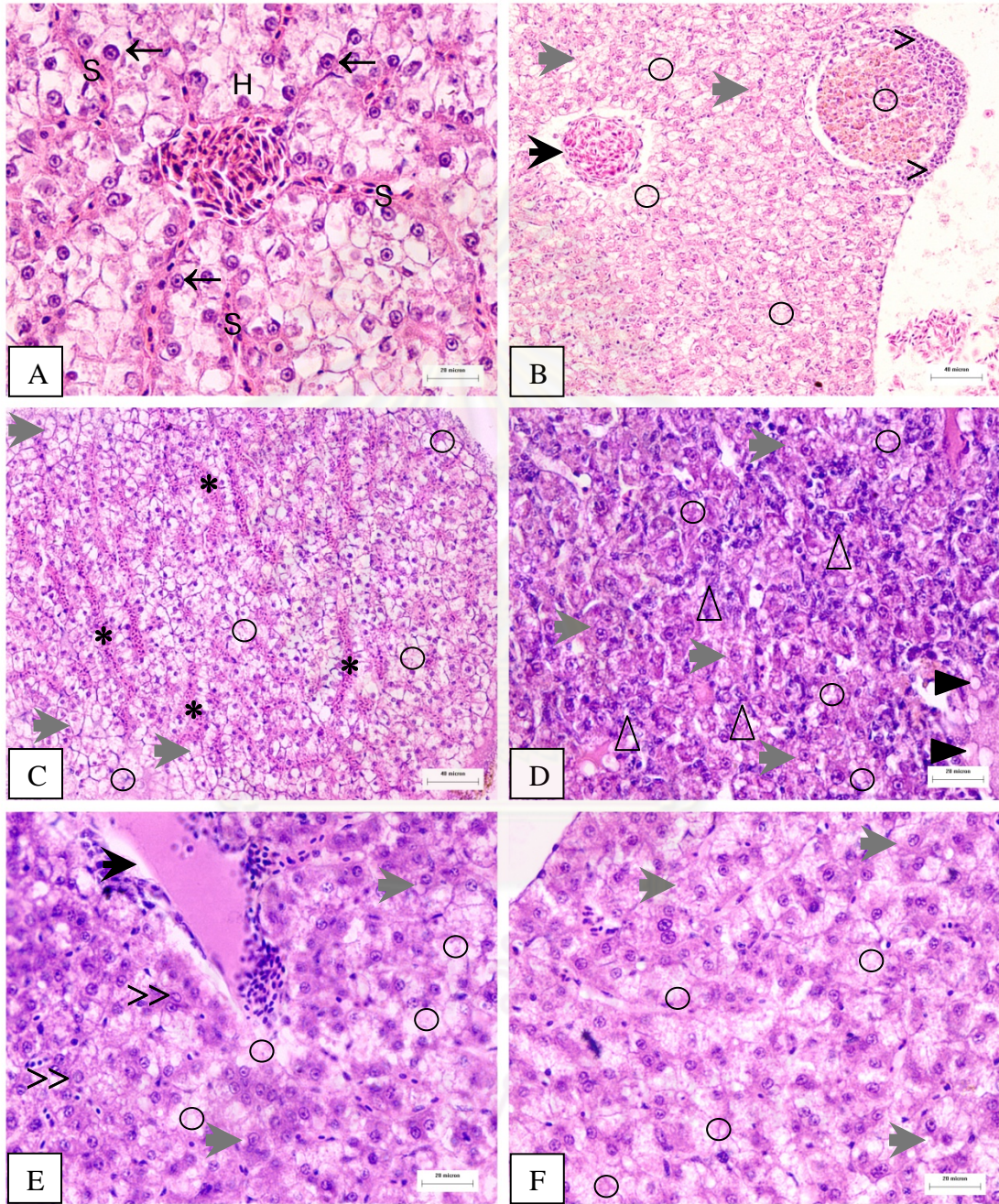


Figure 5-6

Photomicrograph of treated liver of guppy *Poecilia reticulata* at 2 month post-exposure
(H&E staining)

- A Photomicrograph of control liver shows normal histological structures. Bar: 40 μm
- B Photomicrograph of treated liver tissue shows hepatic capsule rupture (star). Bar: 20 μm .
- C Photomicrograph of treated liver tissue shows hypertrophy (gray arrowhead), fat accumulation with cellular necrosis (circle) and pyknotic nucleus (>). Bar: 20 μm .
- D Photomicrograph of treated liver tissue shows hypertrophy (gray arrowhead), amorphous nucleus shape (triangle) and cellular necrosis (circle). Bar: 20 μm .
- E Photomicrograph of treated liver tissue shows constriction of sinusoidal capillaries (arrow), hypertrophy (gray arrowhead) and fat accumulation with cellular necrosis (circle). Bar: 20 μm .
- F Photomicrograph of treated liver tissue shows hypertrophy (gray arrowhead), fat accumulation with cellular necrosis (circle) and karyolysis (>>). Bar: 20 μm .

Figure 5-6

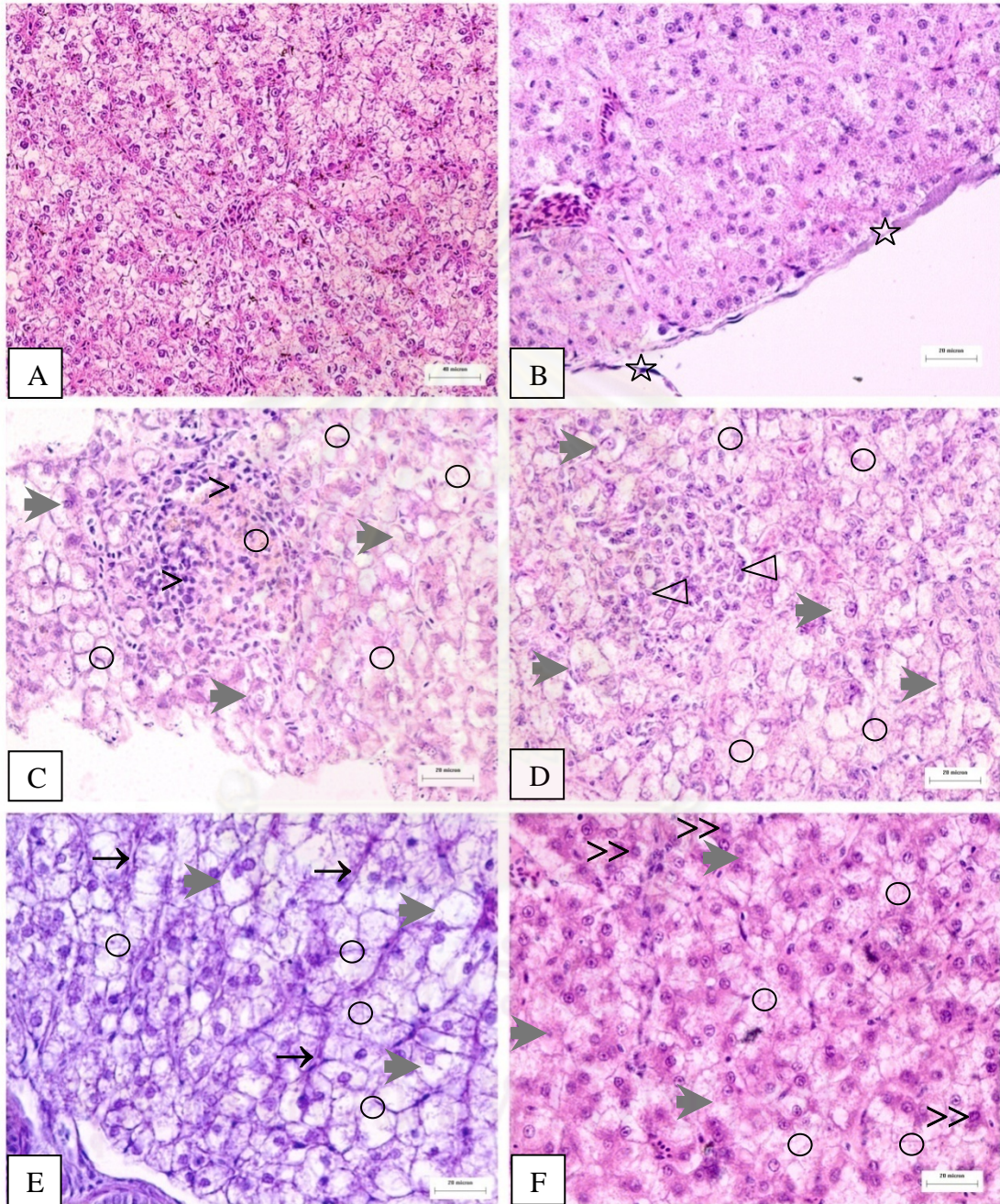


Figure 5-7

Photomicrograph of treated liver of guppy *Poecilia reticulata* at 3 month post-exposure
(H&E staining)

- A Photomicrograph of control liver shows normal histological structures. Bar: 20 μm
- B Photomicrograph of treated liver tissue shows hypertrophy (gray arrowhead), cellular necrosis (circle), endothelium of blood vessel damage (black arrowhead) and macrophage infiltration (>>>). Bar: 20 μm .
- C Photomicrograph of treated liver tissue shows cellular necrosis (circle) and necrosis with fibrosis (star). Bar: 40 μm .
- D Photomicrograph of treated liver tissue shows cellular necrosis (circle), leukocytes infiltration (>>>) and lipid accumulation (dark triangle). Bar: 20 μm .
- E Photomicrograph of treated liver tissue shows hypertrophy (gray arrowhead), amorphous nucleus shape (triangle) and cellular necrosis (circle). Bar: 20 μm .
- F Photomicrograph of treated liver tissue shows amorphous nucleus shape (triangle), cellular necrosis (circle) and karyolysis (>>). Bar: 20 μm .

Figure 5-7

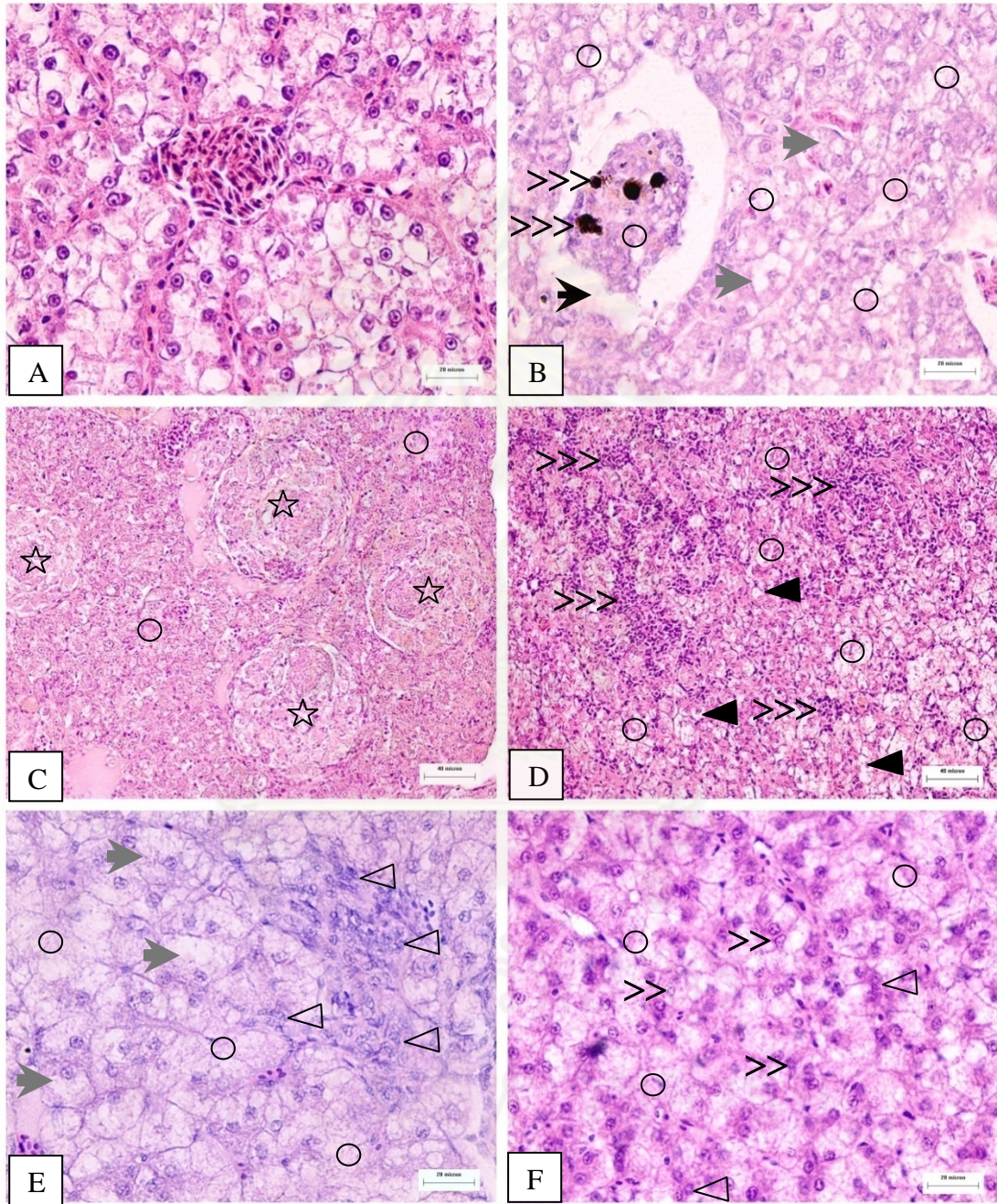


Figure 5.8

Photomicrograph of treated liver of guppy *Poecilia reticulata* at 4 month post-exposure
(H&E staining)

- A Photomicrograph of control liver shows normal histological structures. Bar: 40 μm
- B Photomicrograph of treated liver tissue shows cellular necrosis (circle), necrosis with fibrosis (star) and endothelium of blood vessel damage (black arrowhead). Bar: 100 μm .
- C Photomicrograph of treated liver tissue shows amorphous nucleus shape (triangle) and lipid accumulation (dark triangle). Bar: 20 μm .
- D Photomicrograph of treated liver tissue shows amorphous nucleus shape (triangle), cellular necrosis (circle) and lipid accumulation (dark triangle). Bar: 20 μm .
- E Photomicrograph of treated liver tissue shows necrosis (circle), lipid accumulation (dark triangle) and macrophage infiltration (>>>). Bar: 20 μm .
- F Photomicrograph of treated liver tissue shows hyperplasia (square) and cellular necrosis (circle). Bar: 20 μm .

Figure 5.8

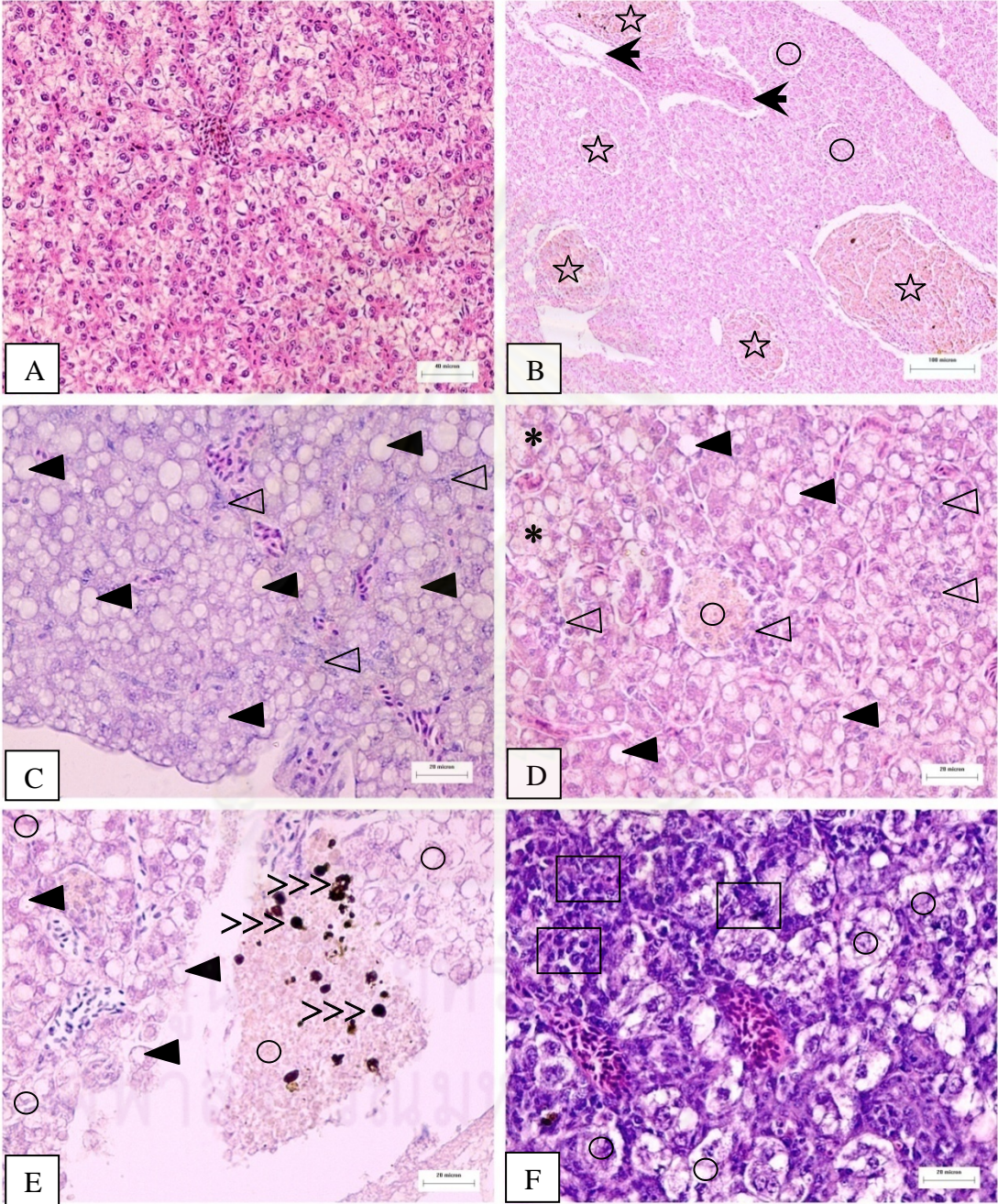


Figure 5-9

Photomicrograph of treated liver of guppy *Poecilia reticulata* at 5 month post-exposure
(H&E staining)

- A Photomicrograph of control liver shows normal histological structures. Bar: 40 μm
- B Photomicrograph of treated liver tissue shows amorphous nucleus shape (triangle), cellular necrosis (circle) and lipid accumulation (dark triangle). Bar: 20 μm .
- C Photomicrograph of treated liver tissue shows hypertrophy (gray arrowhead), cellular necrosis (circle) and macrophage infiltration (>>>). Bar: 20 μm .
- D Photomicrograph of treated liver tissue shows amorphous nucleus shape (triangle) and cellular necrosis (circle). Bar: 20 μm .
- E Photomicrograph of treated liver tissue shows cellular necrosis (circle) and pyknosis (>). Bar: 20 μm .
- F Photomicrograph of treated liver tissue shows hyaline droplets accumulation in hepatic cytoplasm (white triangle). Bar: 20 μm .

Figure 5-9

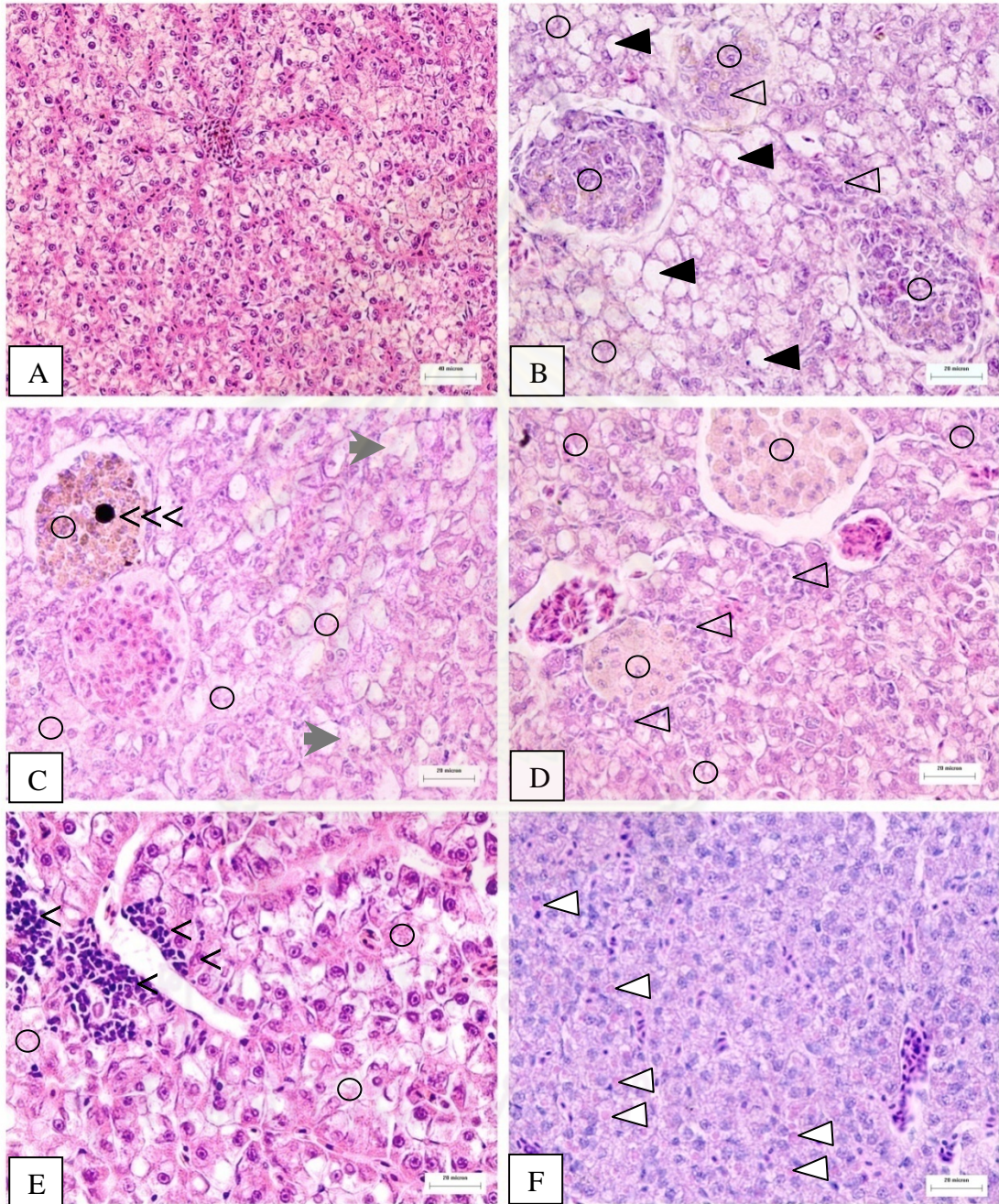


Figure 5-10

Photomicrograph of treated liver of guppy *Poecilia reticulata*
(Oil Red O staining)

- A Photomicrograph of control liver shows mostly small size of lipid droplets in hepatocyte. Bar: 20 μm .
- B Photomicrograph of treated liver tissue at 1 month shows small size of lipid droplets in hepatocyte. Bar: 20 μm .
- C Photomicrograph of treated liver tissue at 2 months shows moderate size of lipid droplets in hepatocyte. Bar: 20 μm .
- D Photomicrograph of treated liver tissue at 3 months shows mostly large size of lipid droplets in hepatocyte. Bar: 20 μm .
- E Photomicrograph of treated liver tissue at 4 months shows mostly large size of lipid droplets in hepatocyte. Bar: 20 μm .
- F Photomicrograph of treated liver tissue at 5 months shows mostly large size of lipid droplets in hepatocyte. Bar: 20 μm .

ศูนย์วิทยทรัพยากร
จุฬาลงกรณ์มหาวิทยาลัย

Figure 5-10

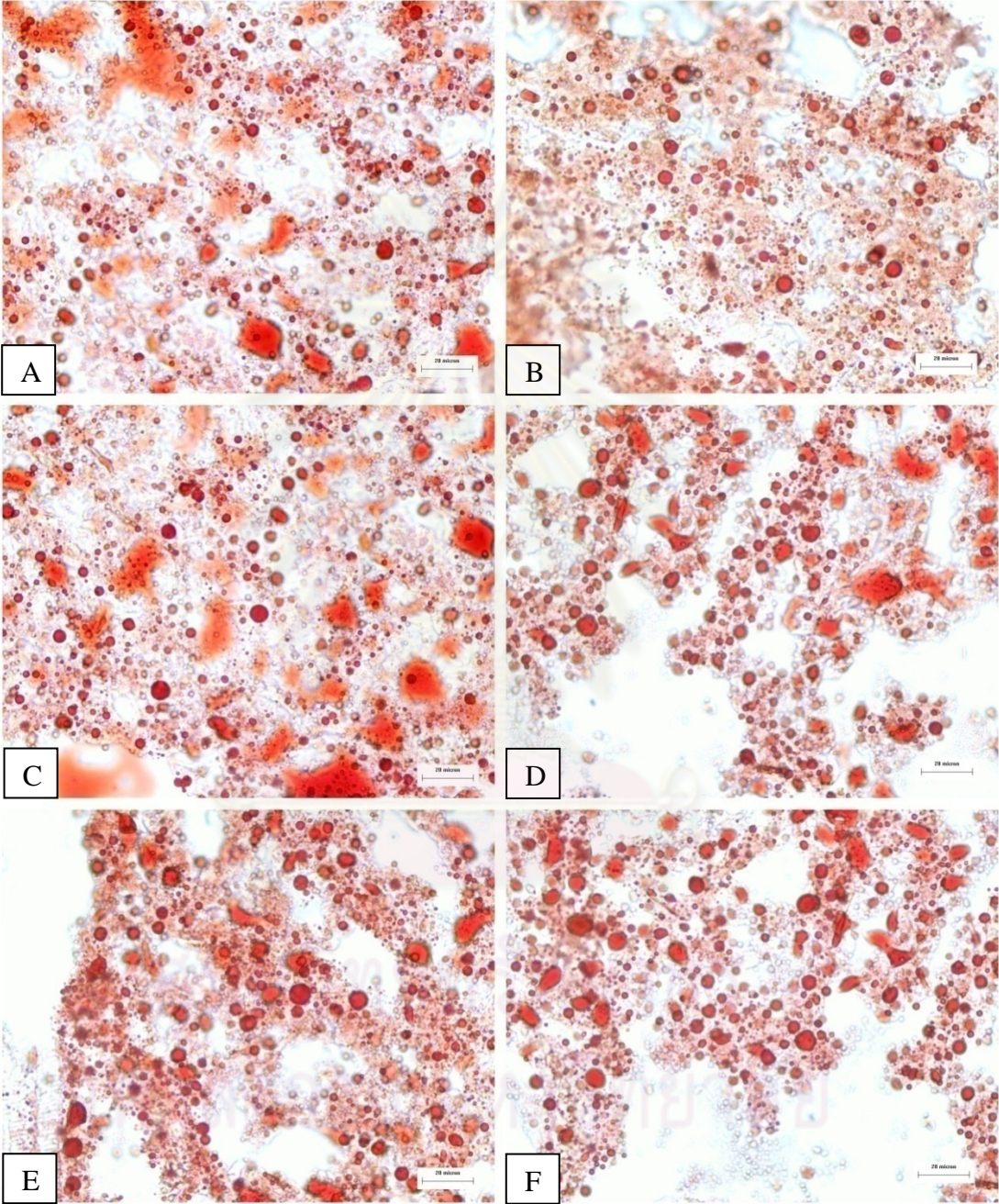


Figure 5-11

Photomicrograph of treated liver of guppy *Poecilia reticulata*
(PAS staining)

- A Photomicrograph of control liver shows positive PAS staining with pink color. Bar: 20 μm .
- B Photomicrograph of treated liver tissue at 1 month shows negative staining. Bar: 20 μm .
- C Photomicrograph of treated liver tissue at 2 months shows negative staining. Bar: 20 μm .
- D Photomicrograph of treated liver tissue at 3 months shows negative staining. Bar: 20 μm .
- E Photomicrograph of treated liver tissue at 4 months shows negative staining. Bar: 20 μm .
- F Photomicrograph of treated liver tissue at 5 months shows negative staining. Bar: 20 μm .

ศูนย์วิทยทรัพยากร
จุฬาลงกรณ์มหาวิทยาลัย

Figure 5-11

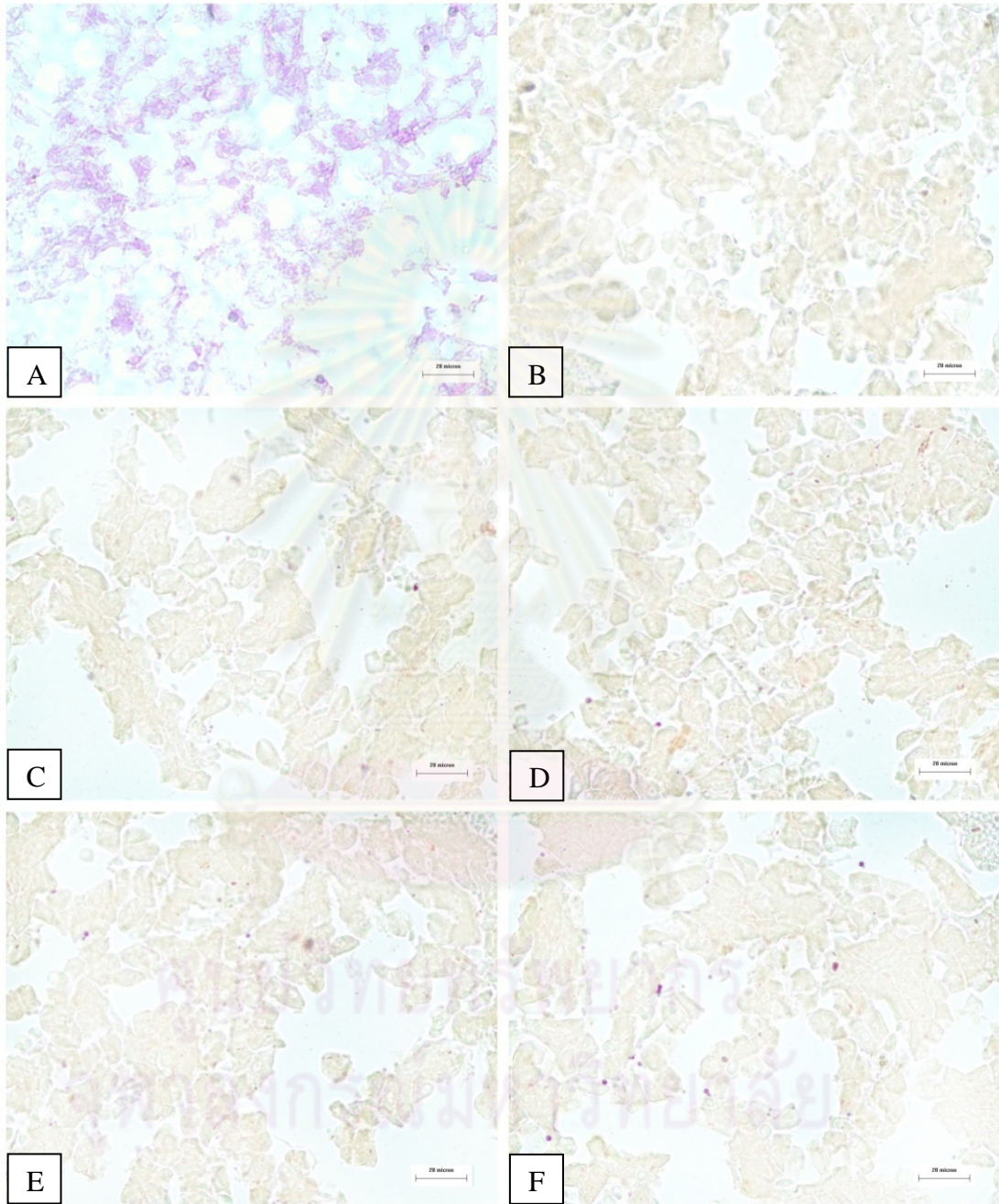


Figure 5-12

Photomicrograph of treated kidney of guppy *Poecilia reticulata*

at 1 month post-exposure (H&E staining)

- A Photomicrograph of control kidney shows normal histological structure. Bar: 20 μm .
- B Photomicrograph of treated kidney tissue shows cellular debris in lumen (star), pyknotic nucleus (arrow), karyolysis (triangle) and renal tubular cell necrosis (square). Bar: 20 μm .
- C Photomicrograph of treated kidney tissue shows cellular debris in lumen (star), endothelium of blood vessel rupture (>>) and renal tubular shrinkage (white triangle). Bar: 40 μm .
- D Photomicrograph of treated kidney tissue shows Bowman's capsule rupture (gray arrowhead) and dilation of glomerular capillaries (black arrowhead). Bar: 20 μm .
- E Photomicrograph of treated kidney tissue shows cellular debris in lumen (star), pyknotic nucleus (arrow) and renal tubular cell necrosis (square). Bar: 20 μm .
- F Photomicrograph of treated kidney tissue shows hydropic swelling (*), debris in renal tubular lumen (star), glomerular degeneration (black arrowhead) and pyknotic nucleus (arrow). Bar: 20 μm .

Figure 5-12

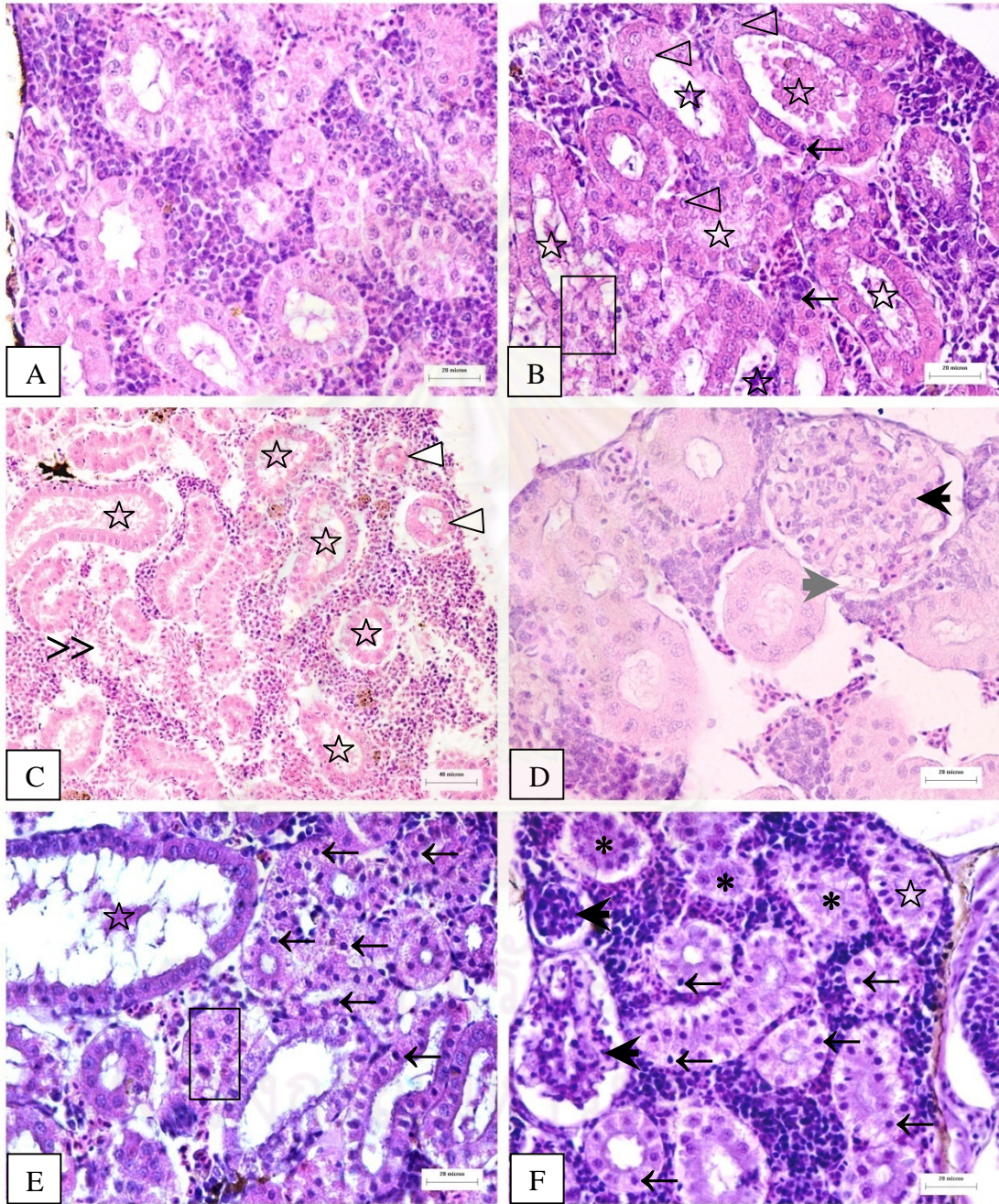


Figure 5-13

Photomicrograph of treated kidney of guppy *Poecilia reticulata*

at 2 month post-exposure (H&E staining)

- A Photomicrograph of control kidney shows normal histological structure. Bar: 20 μm .
- B Photomicrograph of treated kidney tissue shows glomerular enlargement (black arrowhead), cellular debris in lumen (star), karyolysis (triangle) and loss of hematopoietic tissue (circle). Bar: 20 μm .
- C Photomicrograph of treated kidney tissue shows dilation of glomerular capillaries (black arrowhead), cellular debris in lumen (star) and karyolysis (triangle). Bar: 20 μm .
- D Photomicrograph of treated kidney tissue shows cellular debris in lumen (star), renal tubular cell necrosis (square) and pyknotic nucleus (arrow). Bar: 20 μm .
- E Photomicrograph of treated kidney tissue shows pyknotic nucleus (arrow) and renal tubular cell necrosis (square). Bar: 20 μm .
- F Photomicrograph of treated kidney tissue shows pyknotic nucleus (arrow) and renal tubular cell necrosis (square). Bar: 20 μm .

Figure 5-13

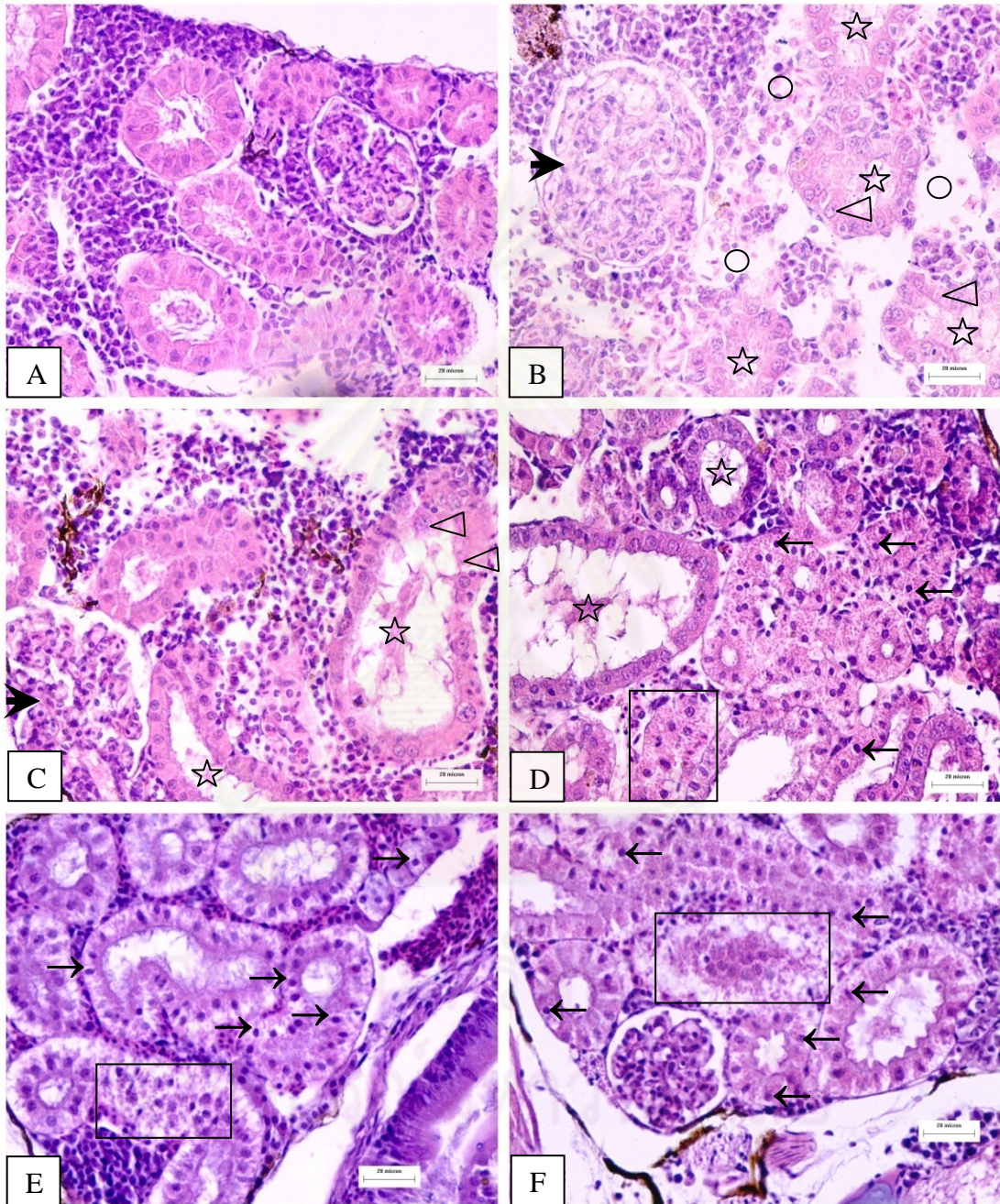


Figure 5-14

Photomicrograph of treated kidney of guppy *Poecilia reticulata*
at 3 month post-exposure (H&E staining)

- A Photomicrograph of control kidney shows normal histological structure. Bar: 20 μm .
- B Photomicrograph of treated kidney tissue shows pyknotic nucleus (arrow) and tubular necrosis (square). Bar: 40 μm .
- C Photomicrograph of treated kidney tissue shows cellular debris in lumen (star), karyolysis (triangle) and macrophage infiltration (>). Bar: 20 μm .
- D Photomicrograph of treated kidney tissue shows glomerular degeneration (black arrowhead) and renal tubular necrosis (square). Bar: 20 μm .
- E Photomicrograph of treated kidney tissue shows cellular debris in lumen (star), karyolysis (triangle) and renal tubular cell necrosis (square). Bar: 40 μm .
- F Photomicrograph of treated kidney tissue shows hydropic swelling (*), cellular debris in lumen (star) and karyolysis (triangle). Bar: 20 μm .

Figure 5-14

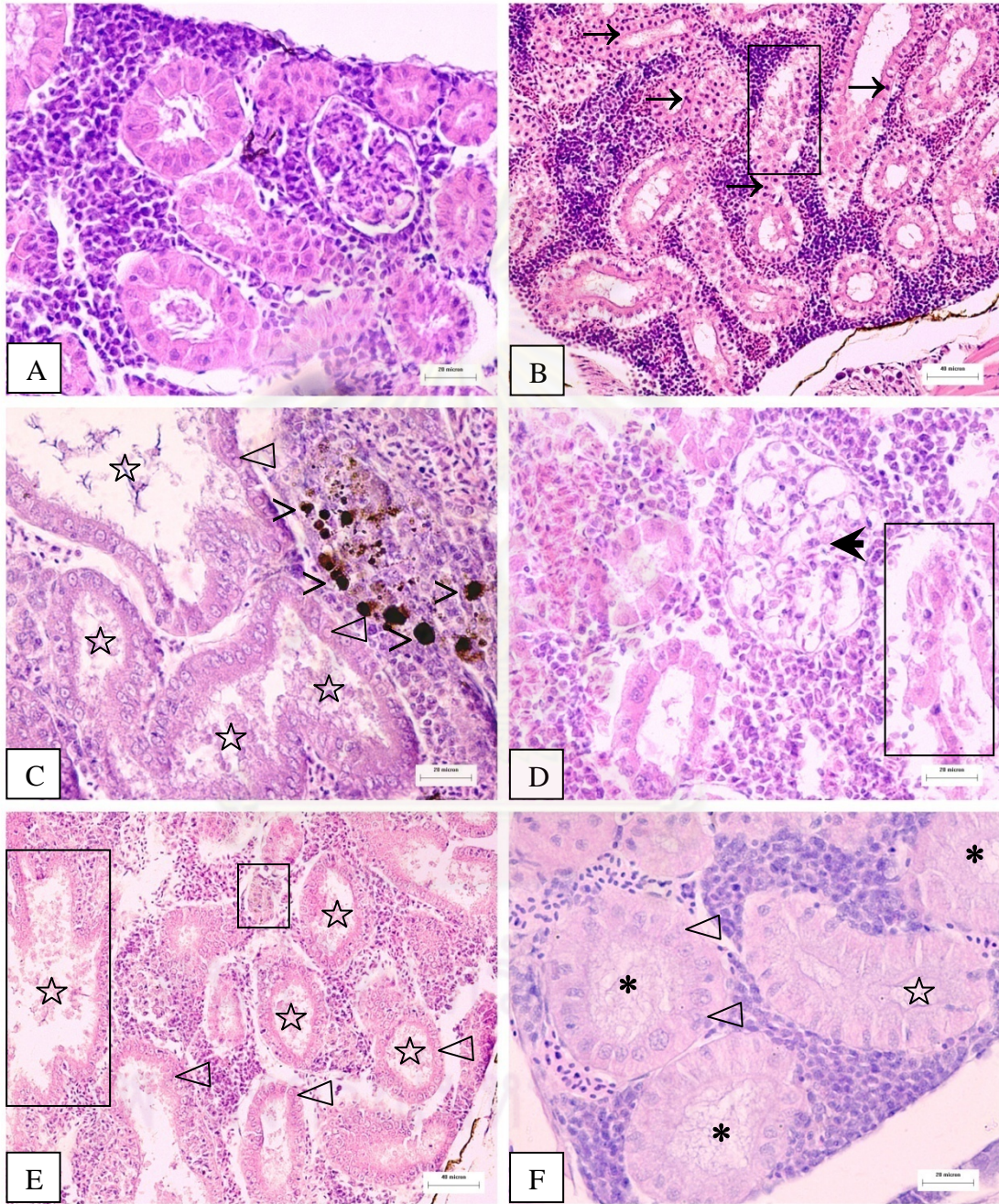


Figure 5-15

Photomicrograph of treated kidney of guppy *Poecilia reticulata*
at 4 month post-exposure (H&E staining)

- A Photomicrograph of control kidney shows normal histological structure. Bar: 20 μm .
- B Photomicrograph of treated kidney tissue shows cellular debris in lumen (star), karyolysis (triangle) and loss of hematopoietic tissue (circle). Bar: 20 μm .
- C Photomicrograph of treated kidney tissue shows glomerular degeneration (black arrowhead), cellular debris in lumen (star) and macrophage infiltration (>). Bar: 40 μm .
- D Photomicrograph of treated kidney tissue shows glomerular degeneration (black arrowhead), cellular debris in lumen (star), karyolysis (triangle), renal tubular necrosis (square) and loss of hematopoietic tissue (circle). Bar: 20 μm .
- E Photomicrograph of treated kidney tissue shows glomerular degeneration (black arrowhead) and renal tubular necrosis (square). Bar: 40 μm .
- F Photomicrograph of treated kidney tissue shows cellular debris in renal tubular lumen (star) and granulocytes infiltration (>). Bar: 20 μm .

Figure 5-15

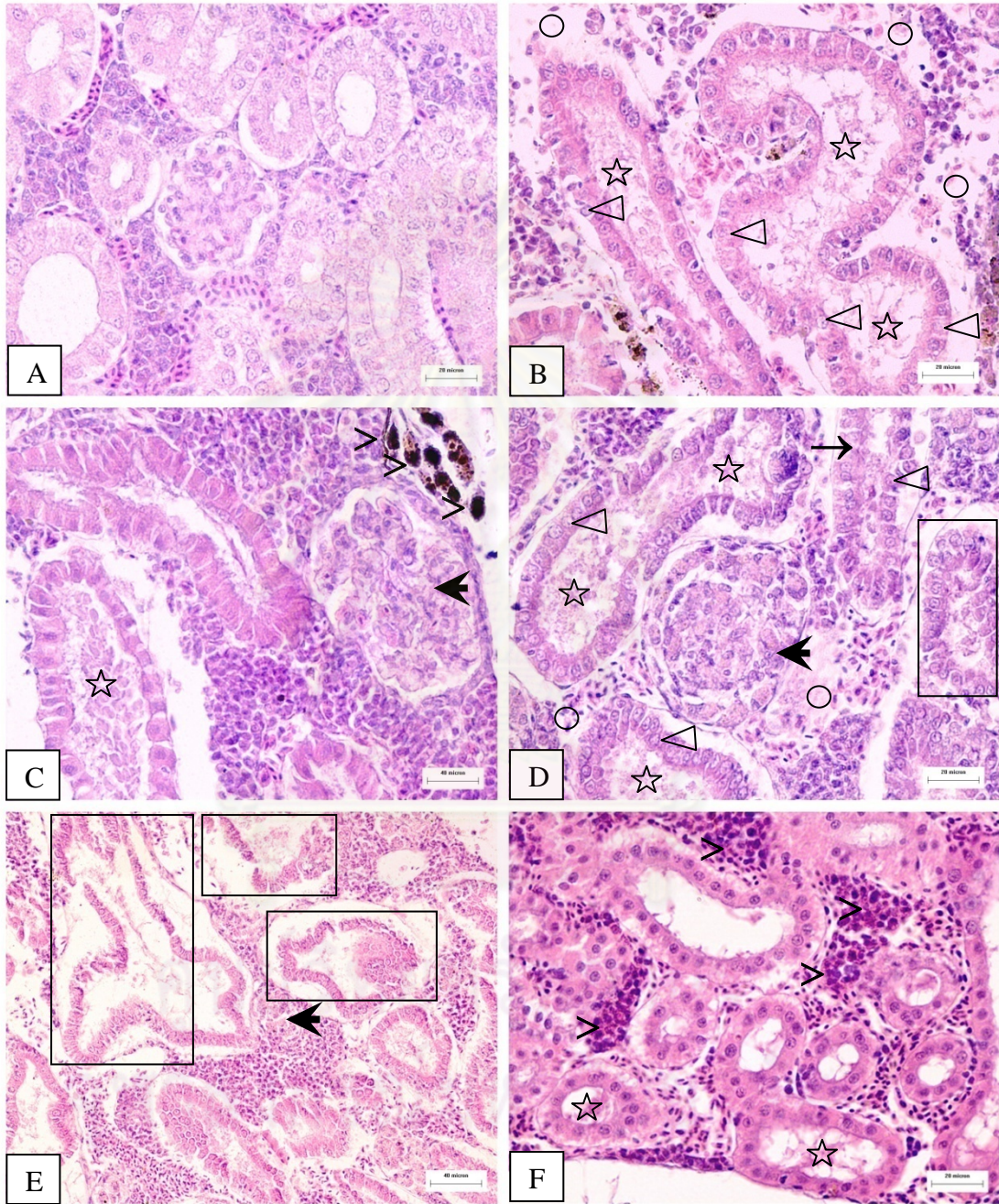


Figure 5-16

Photomicrograph of treated kidney of guppy *Poecilia reticulata*
at 5 month post-exposure (H&E staining)

- A Photomicrograph of control kidney shows normal histological structure. Bar: 20 μm .
- B Photomicrograph of treated kidney tissue shows pyknotic nucleus (arrow) and renal tubular cell necrosis (square). Bar: 20 μm .
- C Photomicrograph of treated kidney tissue shows glomerular degeneration (black arrowhead) and hyaline droplets accumulation (dark triangle). Bar: 20 μm .
- D Photomicrograph of treated kidney tissue shows renal tubular necrosis (square). Bar: 20 μm .
- E Photomicrograph of treated kidney tissue shows cellular debris in renal tubular lumen (star) and karyolysis (triangle). Bar: 20 μm .
- F Photomicrograph of treated kidney tissue shows glomerular degeneration (black arrowhead), cellular debris in renal tubular lumen (star) and macrophage infiltration (>). Bar: 20 μm .

Figure 5-16

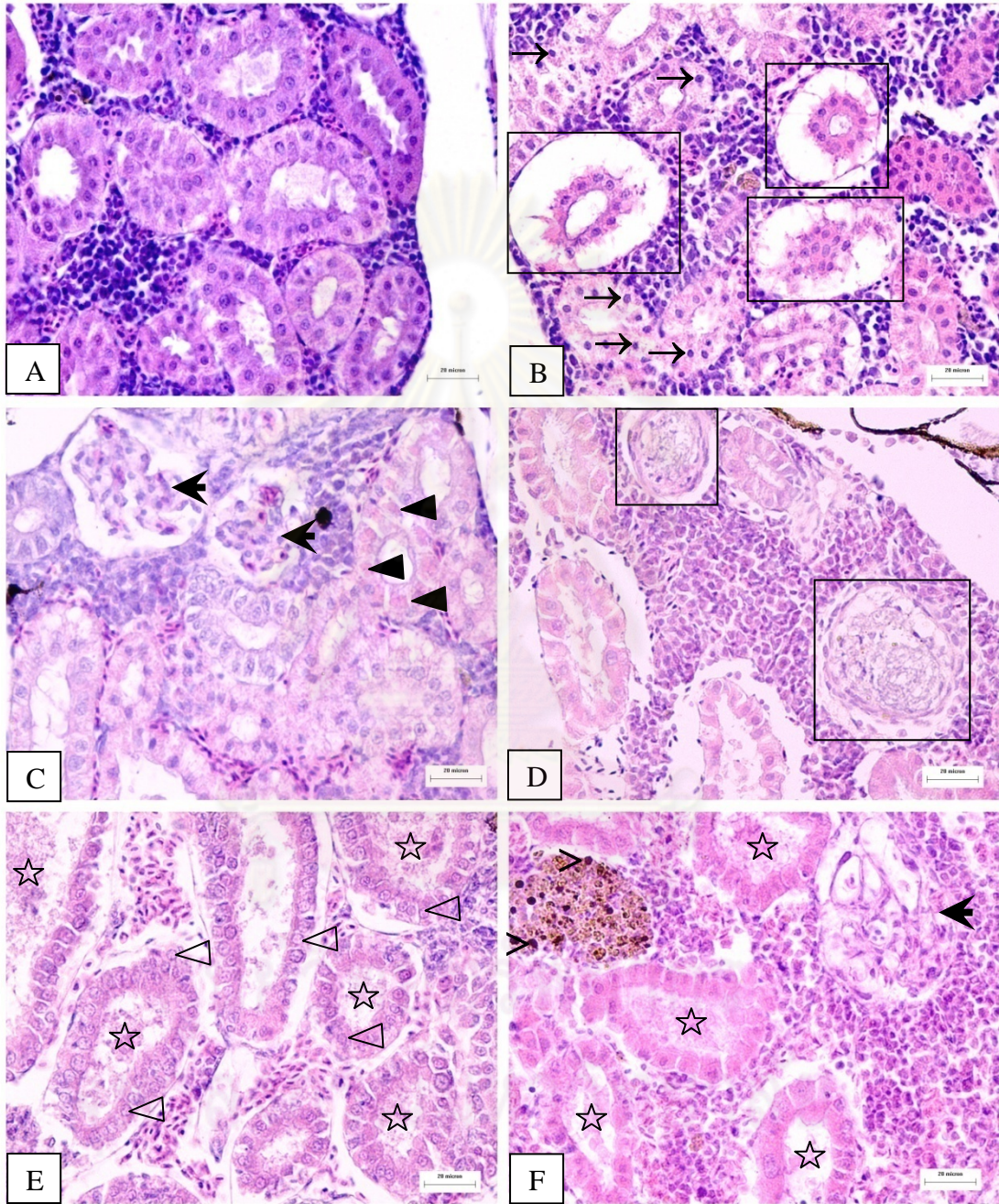


Figure 5-17

Photomicrograph of testis of guppy *Poecilia reticulata* in control groups
(H&E staining)

- A Photomicrograph of control testis at 1 month shows spermatogonia (*). Bar: 20 μm .
- B Photomicrograph of control testis at 2 month shows spermatogonia (*), spermatocyte (star) and Leydic cell (triangle). Bar: 20 μm .
- C Photomicrograph of control testis at 3 month shows and spermatid (arrow), spermatozoa (black arrowhead) and Leydic cell (triangle). Bar: 40 μm .
- D Photomicrograph of control testis at 3 month shows spermatocyte (star), spermatid (arrow), spermatozoa (black arrowhead) and Leydic cell (triangle). Bar: 100 μm .
- E Photomicrograph of control testis at 4 month shows spermatid (arrow) and Sertoli cell (dark triangle). Bar: 20 μm .
- F Photomicrograph of control testis at 5 month shows the heads of the spermatozoa (black arrowhead) attaching to the inner margin of the Sertoli cells lining (dark triangle). Bar: 20 μm .

Figure 5-17

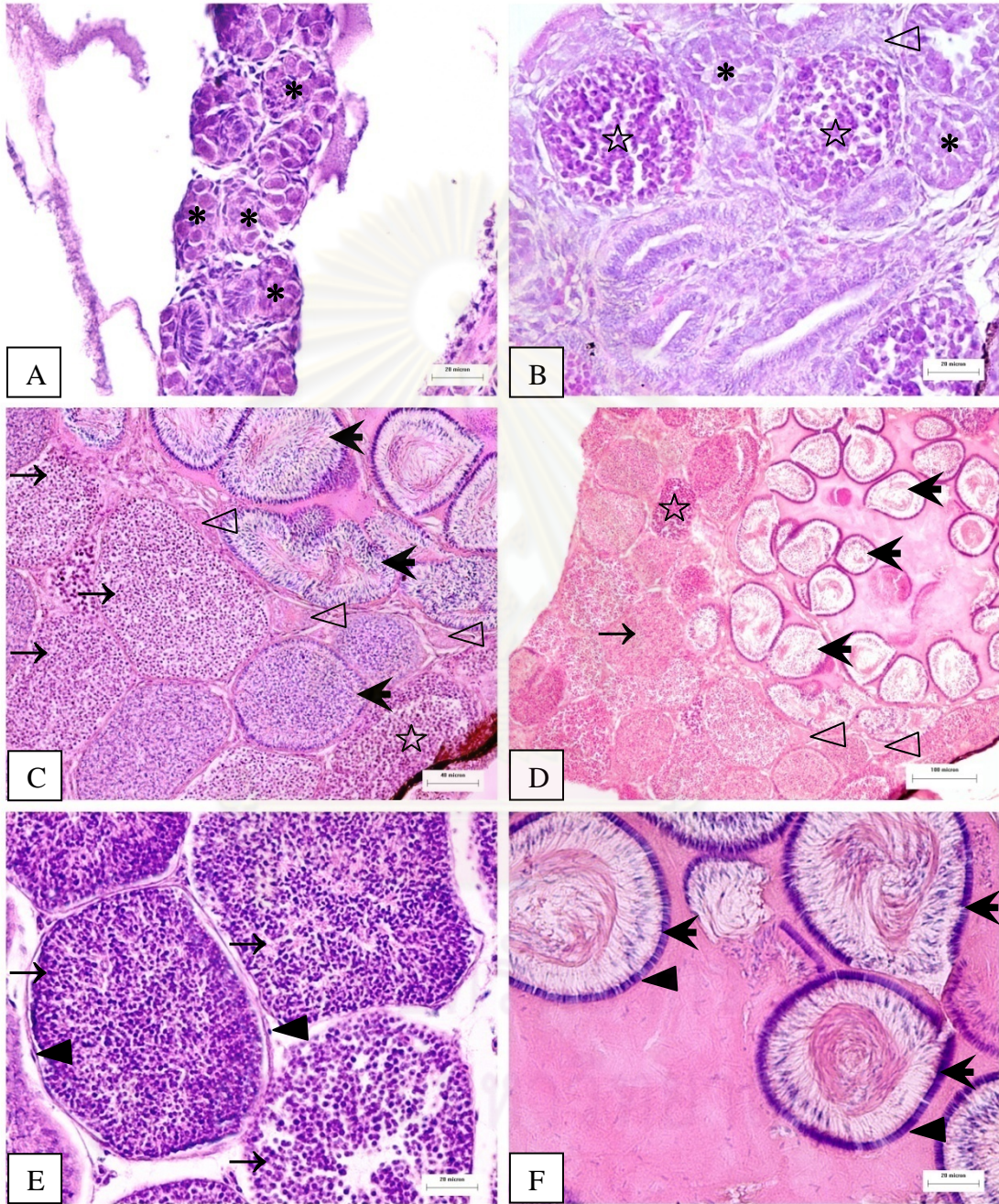


Figure 5-18

Photomicrograph of testis of guppy *Poecilia reticulata* at 1 to 5 month post-exposure
(H&E staining)

- A Photomicrograph of treated testis tissue at 3 month shows loss of supporting cell between the cytes (arrow) and necrosis of cytes (*). Bar: 100 μm .
- B Photomicrograph of treated testis tissue at 4 month shows hypertrophy of Sertoli cell (triangle), necrosis of germ in the cytes (black arrowhead) and necrosis of leydic cells (gray arrowhead). Bar: 40 μm .
- C Photomicrograph of treated testis tissue at 4 month shows hypertrophy of Sertoli cells (triangle), necrosis of germ in the cytes (black arrowhead), necrosis of leydic cells (gray arrowhead) and lipid accumulation in cytes (dark triangle). Bar: 50 μm .
- D Photomicrograph of treated testis tissue at 4 month shows less number of germ cells in the cytes (star) and loss of supporting cells between the cytes (arrow). Bar: 20 μm .
- E Photomicrograph of treated testis tissue at 5 month shows clumping of spermatozoa in the cyte and the head of spermatozoa did not attach to the Sertoli cell (circle). Bar: 20 μm .
- F Photomicrograph of treated testis tissue at 5 month shows necrosis of germ cells and the cytes (black arrowhead). Bar: 40 μm .

Figure 5-18

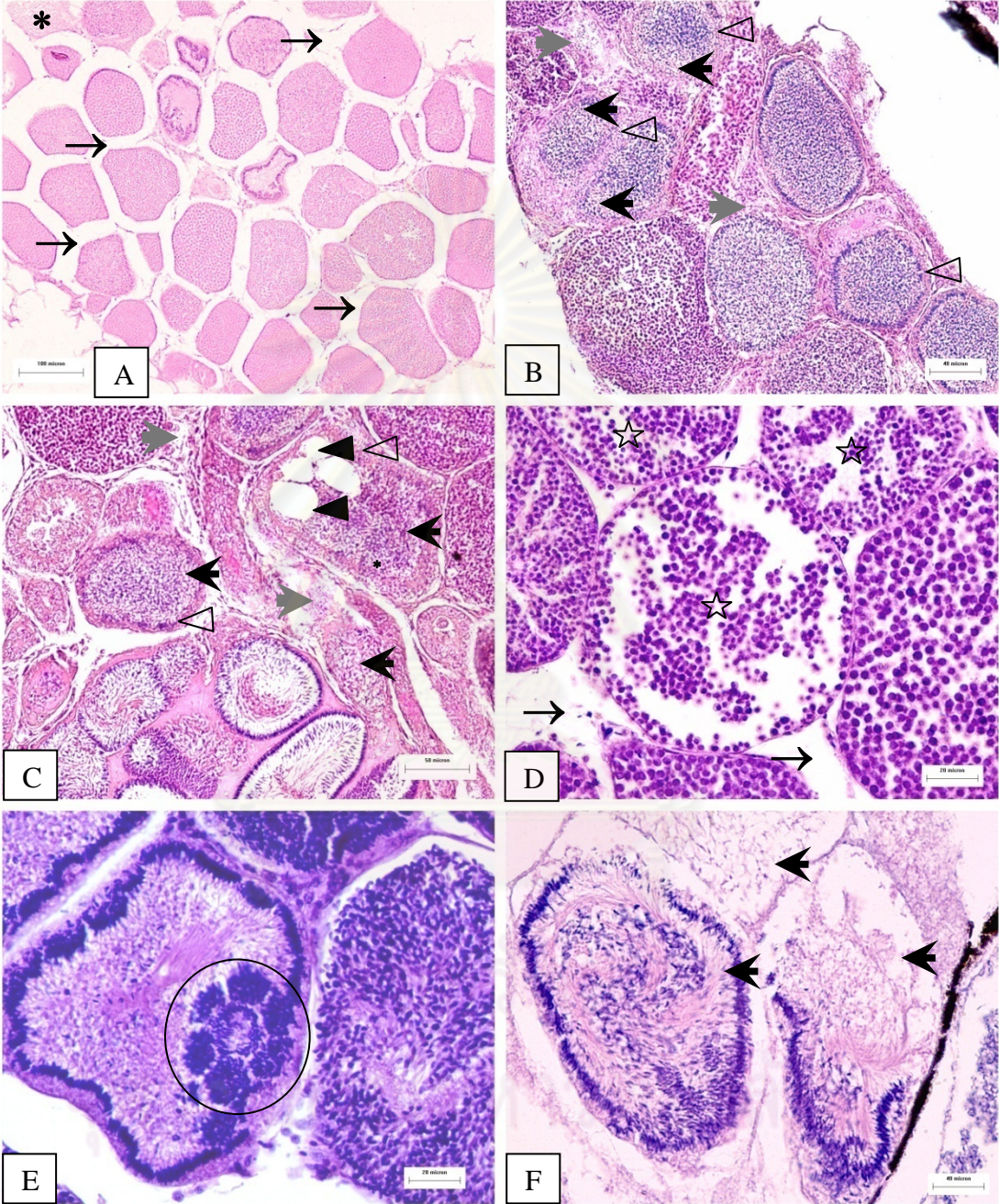


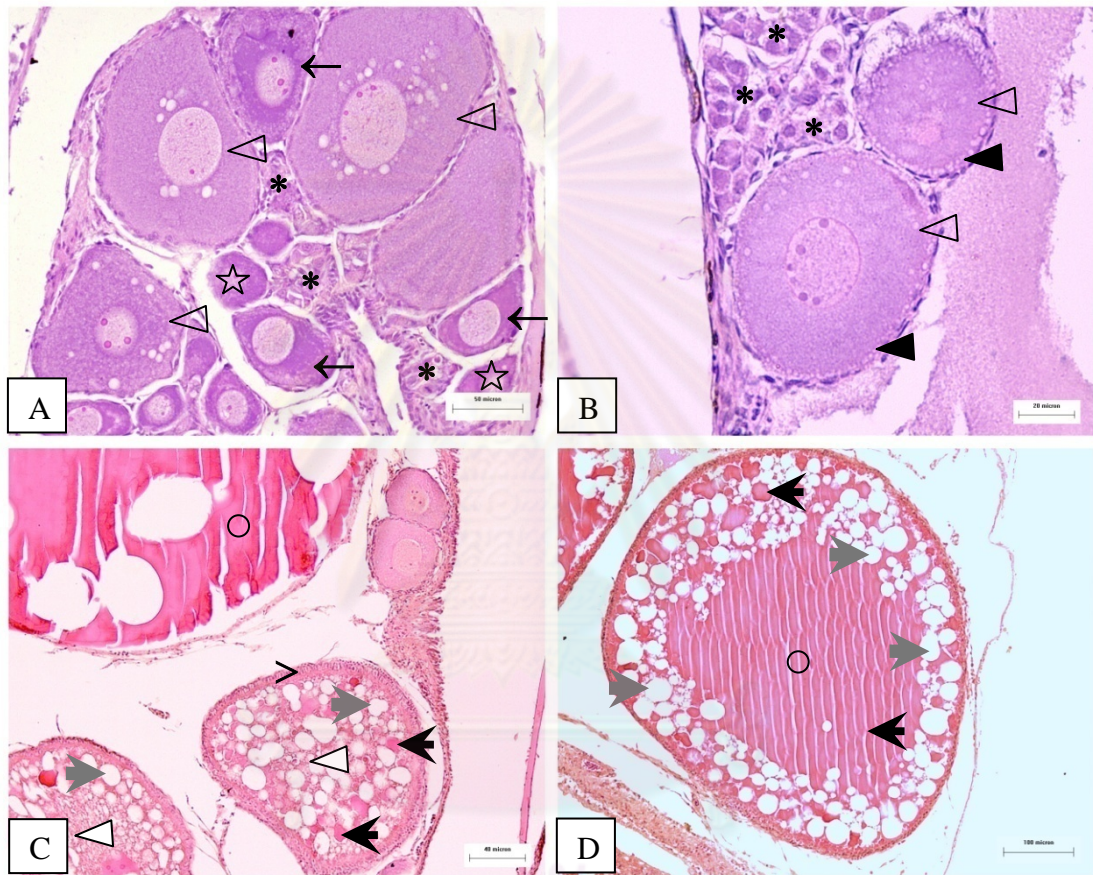
Figure 5-19

Photomicrograph of ovary of guppy *Poecilia reticulata* in control group
(H&E staining)

- A Photomicrograph of control ovary at 2 month shows the oogonium (*), chromatin nucleolar oocyte (star), perinucleolar oocyte (arrow) and cortical alveolar oocyte (triangle). Bar: 50 μm .
- B Photomicrograph of control ovary at 2 month shows the oogonium (*), and cortical alveolar oocyte (triangle) containing cortical alveoli (dark triangle). Bar: 20 μm
- C Photomicrograph of control ovary at 3 month shows the vitellogenic oocyte (white triangle) containing yolk granule (black arrowhead) and lipid granule (gray arrowhead). The follicular layer becomes thicker (>). Bar: 100 μm .
- D Photomicrograph of control ovary at 4 month shows the ripe oocyte (circle) containing lipid granule (gray arrowhead) and large yolk granule (black arrowhead). Bar: 40 μm .

ศูนย์วิทยทรัพยากร
จุฬาลงกรณ์มหาวิทยาลัย

Figure 5-19



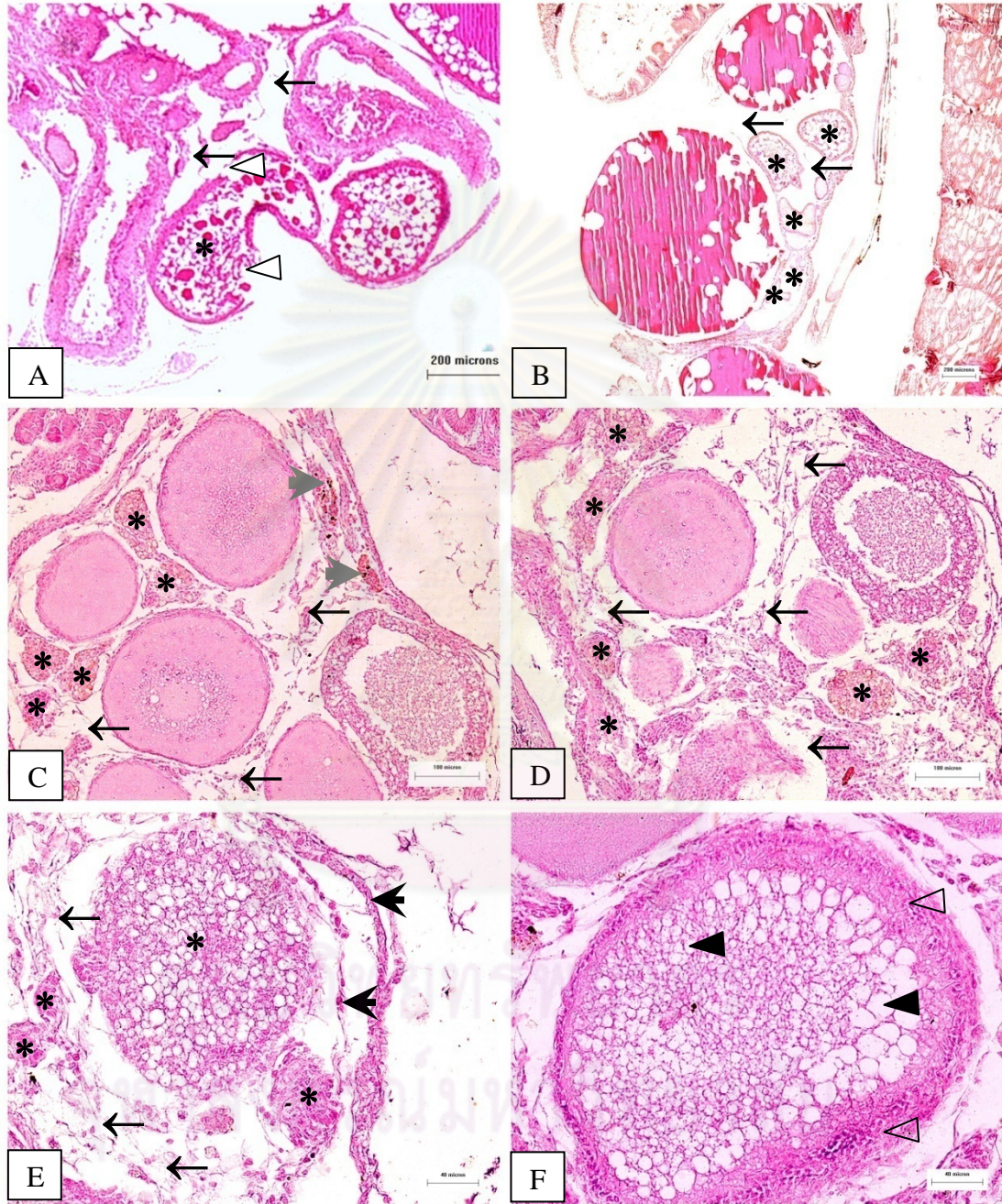
ศูนย์วิทยาศาสตร์การ
จุฬาลงกรณ์มหาวิทยาลัย

Figure 5-20

Photomicrograph of ovary of guppy *Poecilia reticulata* at 1 to 5 month post-exposure
(H&E staining)

- A Photomicrograph of treated ovary tissue at 4 month shows atretic oocyte (*), loss of supporting cells (arrow), breakdown and detachment of follicular layer (white triangle). Bar: 200 μm
- B Photomicrograph of treated ovary tissue at 4 month shows atretic oocyte (*) at different stage of ovarian development and necrosis of connective tissue between oocyte (arrow). Bar: 200 μm .
- C Photomicrograph of treated ovary tissue at 3 month shows atretic oocyte (*), loss of connective tissue between oocytes (arrow) and macrophage infiltration (gray arrowhead). Bar: 100 μm .
- D Photomicrograph of treated ovary at 4 month shows atretic oocyte (*) and loss of connective tissue (arrow). Bar: 100 μm .
- E Photomicrograph of treated ovary tissue at 5 month shows atretic oocyte (*), loss of supporting cells (arrow), breakdown and detachment of follicular layer (black arrowhead). Bar: 40 μm .
- F Photomicrograph of treated ovary tissue at 5 month shows hypertrophy of follicular layer (triangle), lipid accumulation (dark triangle) and oocyte loss of yolk granule in ooplasm in vitellogenic stage. Bar: 40 μm .

Figure 5-20



CHAPTER VI

REPRODUCTIVE TOXICITY EFFECTS OF CARBOFURAN EXPOSURE ON PREGNANT GUPPY *Poecilia reticulata*

7.1 INTRODUCTION

Carbofuran is not only toxic to animal and human nervous system but also associates with reproductive toxicity (PHG, 2000). The reproductive toxicity of insecticide is expressed as alterations in reproductive ability, fertility, reproductive cycle, offspring viability, hormone secretion and structure of reproductive organ (Colborn, Vom Saal, Soto, 1993; Sharpe and Skakkebaek, 1993; Kelce et al., 1994; Kumar, 2004). Reproduction is a key parameter used to investigate the effects of carbofuran. In reproductive toxicity study, results of exposure of the Charles River CD rats to carbofuran, at concentration of 0, 20 and 100 mg/kg, showed the reduction in body weight in the parental generation and the reduction in growth and survival of pup generations in 100 mg/kg treatment group (WHO, 2004). Another similar study, 40 pregnant female Charles River CD rats were fed with 0, 20, 60 and 160 ppm carbofuran in the diet during gestation day 6th through 19th and result revealed that one-half of the fetus were found with visceral and skeletal abnormalities on gestation day 20th (IRDC, 1981). In other report, carbofuran was administered to 10 to 12 CD rats by forced feeding from day 7th to 19th of gestation. The result showed that carbofuran was maternally toxic at the dose of 1, 3, and 5 mg/kg. Fetal toxicity was significant at 5 mg/kg exhibited as a reducing number of live fetuses per litter or increase in fetal mortality, and decrease in fetal body weight (Courtney et al., 1989). Reproductive toxicity of carbofuran in male rat was also reported. After carbofuran exposure, reduction in weight of epididymides, seminal vesicles, ventral prostate and coagulating glands were noted. Decrease sperm motility, reduced epididymal sperm count and increased morphological abnormalities in the head, neck and tail regions of

spermatozoa were also observed (Pant et al., 1995). Testicular and spermatotoxic effects in rat were also noted at the carbofuran level higher than 0.2 mg/kg *in utero* or via lactation (Pant et al., 1997). A study in rat reported from Sri Lanka concluded that carbofuran administered orally at the dose of 0.2, 0.4 and 0.8 mg/kg during early gestation was detrimental to pregnancy (enhanced preimplantation losses) and possibly harmful to neonatal development (Jayatunga, Dangalle and Ratnasooriya, 1998a). Similarly, post-implantation losses were noted after exposure to carbofuran during mid-gestation (Jayatunga, Dangalle and Ratnasooriya, 1998b).

Disruptions of fish reproductive process with alterations in gonad structure by insecticide were well documented (Sibonani et al., 2009; Jo et al., 2007; Dutta and Meijerb, 2003a; Chatterjeea, Kumar and Ghosha, 2001 and Houde, 1997). Whereas studies on monitoring health status of fish including biochemical, physiological and histopathological biomarkers were undergoing, parallel investigation of ecological endpoints such as abundance, growth of fry, litter size and survival ability should be monitored as well. Even though the reproductive toxicity of carbofuran on small mammals was well documented, few studies were carried out on fish which was more susceptible to the insecticide effects due to exposure via aquatic environment. Reports about reproductive disorders of fish including altered fertility, viability and survival of offspring were rare. Report on similar issues in a viviparous fish, an important model for pregnancy, is even rarer. Therefore, the objectives of this study were to investigate the effects of carbofuran exposure on reproductive capability, live birth index and offspring survival of pregnant guppy *Poecilia reticulata*.

7.2 MATERIALS AND METHODS

7.2.1 *Experimental animal*

One year old guppies were used in this experiment. The mean length of the females was 2.8 ± 1.0 cm. The fish were acclimatized in 12-L glass aquarium in dechlorinated tap water with aeration prior to the experiment. During the experiment,

they were maintained in 27-30°C water, on 12h light: 12h dark photoperiod, and were fed twice daily with commercial guppy food (See-All Aquariums Co., Ltd.).

7.2.2 Experimental chemical

The carbofuran (Furadan 3G) was used in this experiment. Carbofuran was dissolved in dimethylsulphoxide (DMSO) before diluting into water to obtain the final concentration at 0.01 and 0.05 ppm. The solvent control group was contained DMSO at a concentration of 5 ppb.

7.2.2 Experimental design

Female guppies were isolated into 2-L glass aquarium and monitored for 6 to 8 weeks until they were given birth to offspring due to earlier fertilization in stock aquarium. The final concentrations of carbofuran were prepared at 0.01 and 0.05 ppm. These concentrations were sublethal concentration that calculated from the LC₅₀ at 96 hours for guppy (unpublished data). A pair of male and female guppy was transferred to a glass aquarium for breeding. After five-day, male guppy was removed and the female was kept in the test solutions until they produced their brood. Twenty female guppies were used in each concentration. The static renewal system was used throughout the experiment. After offspring was born, total number of offspring, number of death offspring and number of viable offspring were observed and recorded. Then the offspring of each female was separated into glass aquarium contained the same concentration of carbofuran as mother tank for survival study. After offspring was born, the morphology of newborn in each individual was observed. The survival of offspring in each aquarium was monitored every 24 hours for 15 days.

7.2.3 Statistical analysis

The reproductive capability (the litter size of guppy), live birth index and survival percentage and pregnant period (Donald, 1992) were calculated. The reproductive capability was done by determining average number of offspring per female for each

concentration and the control, the live birth index by multiplying number of viable offspring per a total number of offspring by 100, and the survival percentage by multiplying number of viable offspring on a given day per a total number of offspring by 100, respectively. The data were statistically analyzed with Kruskal-Wallis One Way Analysis of Variance on Ranks followed by Dunn's Method. $P < 0.05$ was considered to be significant.

7.3 RESULTS

7.3.1 Reproductive capability

The result of mean reproductive capability is shown in Table 6-1. The maximum value of reproductive capability was found in control group (13 individuals/female) whereas the lowest litter size was found in the treatment group exposed to 0.05 ppm carbofuran (6 individuals/female). The mean litter size was not different (10.0 ± 0.1 individuals/female) between both control groups and the 0.01 ppm treatment group. On the other hand, the reproductive capability was significantly decreased to 9.0 ± 0.3 individuals per female in the 0.05 ppm treatment group ($P < 0.05$).

7.3.2 Live birth index

The live birth index in control and solvent control groups were found at the highest percentage. The mean live birth index in control, solvent control, 0.01 ppm and 0.05 ppm treatment groups were $99.22 \pm 0.33\%$, $99.69 \pm 0.21\%$, $92.46 \pm 0.66\%$ and $77.58 \pm 2.54\%$, respectively. The mean live birth index in both treatment groups was significantly different from both control groups ($P < 0.05$). The result of mean live birth index is shown in Table 6-2.

7.3.3 Survival index

The survivals of offspring in control and solvent control groups were recorded for 15 days post partum. The survival percentages were high at $99.22 \pm 0.33\%$ and $99.69 \pm 0.21\%$, respectively. The survival of offspring in treatment group at concentration

of 0.01 ppm was reduced from $91.68 \pm 0.83\%$ to $90.68 \pm 0.83\%$ during 15 days. In 0.05 ppm treatment group, the survival of offspring was decreased from $73.32 \pm 2.48\%$ to $68.18 \pm 2.42\%$ during 15 days. The survival percentages of offspring in treatment groups at concentration of 0.01 ppm and 0.05 ppm carbofuran were significantly lower than control and solvent control groups ($P < 0.05$). The result of mean survival index of offspring is shown in Graph 6-1.

7.3.4 Pregnant Period

The mean pregnant period of female guppies in control and solvent control groups was 29.0 ± 0.2 days. On the other hand, the pregnant period of female guppies in treatment group was significantly increased from 29 ± 0.2 day in control groups to 32.0 ± 0.2 days at concentration 0.01 ppm and 33.0 ± 1.0 days at concentration 0.05 ppm of carbofuran (table 6-3). Additionally, the female guppies could produce up to 3-6 batches of offspring per a time of fertilization. In this study, female guppies produced 3 batches of offspring. The mean of pregnant period of female guppies is shown in Table 6-3 and 6-4. The pregnant period in treatment group at all batches was significantly increased comparing with control groups ($P < 0.05$).

7.3.5 Morphological abnormality of offspring

After offspring born, the morphology of newborn in each individual was observed. The morphology of offspring in control, solvent control and 0.01 ppm treatment group showed normal character. On the other hand, the morphological abnormality of offspring was found only in treatment group at 0.05 ppm of carbofuran. It is of importance to note that the newborn guppy had two heads in one body. Ten individuals of offspring or approximately 2% of total offspring in 0.05 ppm treatment group were found with this morphological abnormality (Table 6-5 and Figure 6-1).

7.4 DISCUSSIONS

Although the degradation of carbofuran was rapid in environment, its extensive use probably caused adverse effects on fish reproduction (Colborn, Vom Saal and Soto, 1993). The viviparity of the guppy and its short reproductive cycle made this fish to be an excellent model for the assessment of effects of carbofuran on female fertility and viability of offspring. Results from our study suggested that even at a low concentration, carbofuran could cause reproductive disorders in exposed guppies including reduced viability of offspring, litter size and survival of offspring.

The reproductive capability, determined by the litter size, was significantly decreased. It explained that the changes of eggs quality and quantity could reduce female fertility which might result in decrease of offspring number (Kime, 1999). Many studies reported that carbofuran reduced the quality and quantity of eggs resulting in low number of offspring or reduced reproductive capability of female by disrupting egg development or by reducing vitellogenin production (Chatterjee and Ghosh, 1995; Chatterjee, 1996; Tyler and Sumpter, 1996; Chatterjee, Dutta and Ghosh, 1997; Adhikari et al., 2008). Other laboratories reported that decreasing number of offspring was found in various insecticides (Hose, Cross and Diehl, 1989; Yasuno, Hatakeyama and Miyashita, 1990).

The live birth indices and the survival of offspring in treatment groups at concentration of 0.01 ppm and 0.05 ppm carbofuran were significantly reduced compared with the control groups ($P < 0.05$). Although the female guppies exposed to the low concentration of carbofuran (0.01 ppm) were capable of producing quite similar number of offspring with the controls (10 individuals per female), their survival was significantly lower. The decrease of percentage live birth index might be a result of the possibility that carbofuran could pass from mother to offspring during the embryonic development. Carbofuran exposure throughout this embryonic development could result in weaker offspring making them struggle to survive. Contaminated yolk from mothers

who exposed to high carbofuran burden could result in liver alterations and this might affect to the nutrition content and quality of the eggs, which were the possible causes for weak offspring production.

In other studies, the guppy exposed to chlorpyrifos concentrations reduced live birth index and survival of offspring of guppy (De Silva and Samayawardhena, 2005). The hatching percentage of fresh water fish *Labio rohita* were reduced after exposed to sublethal concentration of carbofuran (Adhikari et al., 2008). The methyl parathion exposed on pregnant female *Girardinichthys multiradiatus* reduced the survival offspring (Arellano-Aguilar and Macias, 2009). The sublethal concentration of benomyl on zebrafish showed decreased survival and hatching of embryos (Kim et al., 2009). Moreover, medaka (*Oryzias latipes*) exposed to TPT for 5 weeks decreased the spawning frequency, spawned egg number, egg quality and gonad development (Zhang et al., 2008).

In the present study, the survival of offspring in 0.05 ppm treatment group at day 15 was less than 68.18 %. This might imply that carbofuran could pass from mother during pregnancy and result in infirmity of offspring and affected its survival. Furthermore, the low survival percentage in the treatment groups may be a result of carbofuran acute toxic effect after newborn guppies were directly exposed to carbofuran after birth.

The female guppies could produce up to 3-4 batches of offspring per a time of fertilization because they had the sperm storage (Constantz, 1989). In this study, the female guppies produced 3 batches of offspring and the pregnant period of control guppy was 29 days. On the other hand, the pregnant period in treatment group was significantly increased comparing ($P < 0.05$). The pregnant period was increased with increasing concentration of carbofuran and exposure period. It might cause carbofuran direct destroy ovarian structure. Furthermore, carbofuran was listed as a potential

endocrine disrupter by the German Federal Environment Agency (ENDS, 1999). Therefore, the longer pregnant period might occur because of carbofuran disruption on the growth and ovarian maturity (Chandra, Ram and Singh, 2004; Chatterjee, Dutta, and Ghosh, 1997 and Mani and Saxena, 1985). In addition, carbofuran affected on hormone release by disrupting hypothalamo-neurohypophyseal complex and pituitary-gonad axis in fish (Chatterjee, Kumar and Ghosh, 200; Ram, Singh and Singh, 2001).

The morphological abnormality of offspring was found in 0.05 ppm treatment group with approximately 2% of the newborn guppies found with two heads in one body. The abnormality of morphology of offspring might be involved with vertical transfer of carbofuran from mother to offspring during the embryonic development. These results indicated potential teratogenic effects of carbofuran firstly described in a non-mammalian species. The adverse effects of carbofuran were known to interact with the endocrine system in fish (Lawrence and Elliott, 2003). It affected on steroid hormone dysfunction and might lead to embryonic malformation.

Of important to this study, few studies reported on the adverse reproductive effects of carbofuran. Forty-five percent of urban African-American women who live and work on farm showed detectable levels of carbofuran in maternal plasma and umbilical cord blood (Whyatt et al., 2003). In male worker exposed to carbofuran, seminal analysis revealed a total concentration of 42 million spermatozoa/mL with 17% motility and 20% normal shape. The second patient presented a total concentration of 5 million spermatozoa/mL with 6% motility and 2% normal shape. The patients presented a similar percentage of binucleated spermatozoa (28 and 26%) and of multinucleated spermatids (10 and 6%) (Avila, et al., 2010).

The results from this study suggested that carbofuran could decrease responses to stress conditions and further decrease growth and metabolism, and could ultimately affect the survival of offspring. In the environment, newborn guppies would be highly

struggle to survive since they were vulnerable to a variety of stress conditions including effects from insecticide residues. The adverse effects might cause the decrease in population size of the newborn fish by reducing its survival.

7.5 CONCLUSIONS

In conclusion, the present study exhibited that the low concentration of carbofuran could potentially impaired reproductive capabilities of female guppy, reduce the live birth index, reduce survival of F_1 generation of guppy and disruption the embryo development. This suggested that maternal carbofuran exposure throughout the embryonic development could result in weak offspring as well as their survival and abnormality. Overall, these experiments showed adverse effects on small fish in organism level (litter size, live birth index and survival percentage). The cautionary adverse effects of this compound suggested the need for further investigation of carbofuran effects on some other parameters significant in evaluating the risk to humans and animals in the environment.



ศูนย์วิทยทรัพยากร
จุฬาลงกรณ์มหาวิทยาลัย

TABLES, FIGURES AND GRAPHS

Table 6-1 Mean number of offspring per female with different concentration

	Control (Mean \pm SE)	DMSO control (Mean \pm SE)	Treatment (Mean \pm SE)	
			0.01 ppm	0.05 ppm
Reproductive capability	10.0 \pm 0.1	10.0 \pm 0.1	10.0 \pm 0.1	9.0 \pm 0.3 ^a

Mean with different letters (a) within a row are significantly different ($P < 0.05$).

Table 6-2 Mean live birth index of offspring with different concentration

	Control (Mean \pm SE)	DMSO control (Mean \pm SE)	Treatment (Mean \pm SE)	
			0.01 ppm	0.05 ppm
Live birth index (%)	99.22 \pm 0.33	99.69 \pm 0.21	92.46 \pm 0.66 ^a	77.58 \pm 2.54 ^b

Mean with different letters (a, b) within a row are significantly different ($P < 0.05$).

Table 6-3 Mean pregnant period of offspring with different concentration

	Control (Mean \pm SE)	DMSO control (Mean \pm SE)	Treatment (Mean \pm SE)	
			0.01 ppm	0.05 ppm
Pregnant period (Day)	29.0 \pm 0.2	29.1 \pm 0.2	32.0 \pm 0.2 ^a	33.0 \pm 1.0 ^a

Mean with different letters (a) within a row are significantly different ($P < 0.05$).

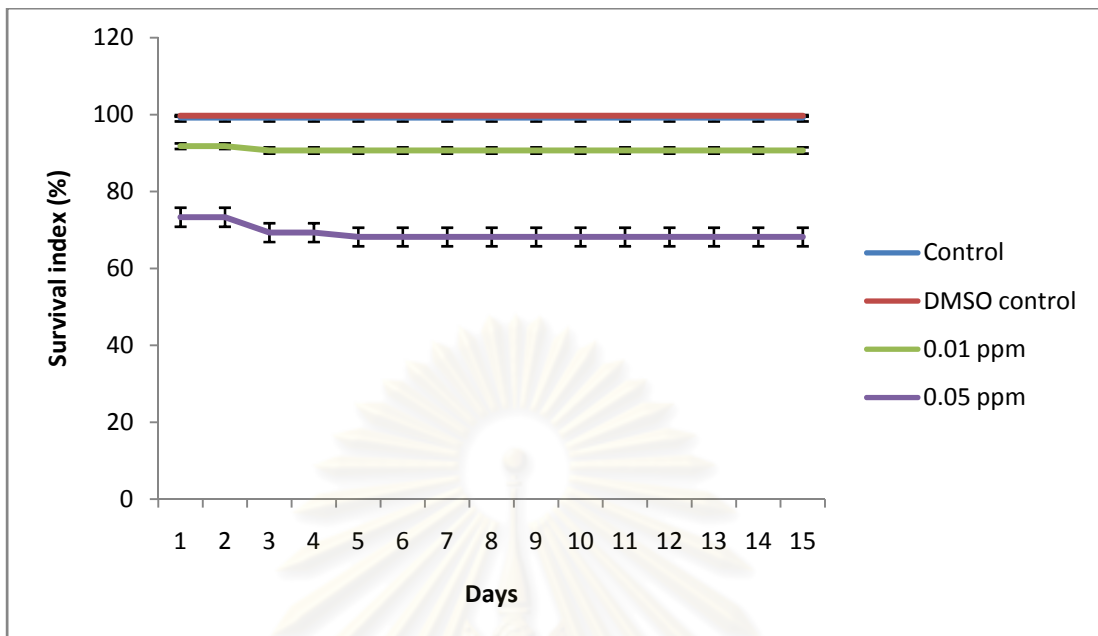
Table 6-4 Mean pregnant period in each batch of offspring with different concentration

Batch	Control	DMSO	Treatment (Mean \pm SE)	
			0.01	0.05
1 st	29 \pm 0.3	29 \pm 0.2	31 \pm 0.3 ^a	31 \pm 0.3 ^a
2 nd	29 \pm 0.3	29 \pm 0.3	32 \pm 0.3 ^a	35 \pm 0.3 ^b
3 rd	29 \pm 0.3	29 \pm 0.3	33 \pm 0.2 ^a	36 \pm 0.3 ^b

Mean with different letters (a, b) within a row are significantly different ($P < 0.05$).



Figure 6-1 The morphological abnormality of newborn guppy in treatment group at 0.05 ppm of carbofuran. Two percent of newborn guppy in this treatment group showed two heads (arrows) in one body.



Graph 6-1 Means of survival index of *P. reticulata* in control, DMSO and treatment groups after exposure of 0.01 and 0.05 ppm carbofuran, a and b indicate significant difference ($P < 0.05$)

ศูนย์วิทยทรัพยากร
จุฬาลงกรณ์มหาวิทยาลัย

CHAPTER VII

GENERAL DISCUSSIONS AND CONCLUSIONS

An understanding of individual fish health (pathology) interpreted simultaneously with organism level measurements (survival) could provide a more complete assessment of the effects of carbofuran residues (De Silva and Samayawardhena, 2002; Adams, 2002; Rabitto et al., 2005; Oliveira-Ribeiro et al., 2006). Evaluations the health (histopathology), survival and growth of guppy *Poecilia reticulata* were studied. The endpoints of the effects on gill, liver, kidney and gonad were determined by histological and histochemical biomarker. Moreover, the endpoints for reproductive toxicity were determined by some reproductive indices on female guppies and their offspring.

Acute toxicity test of the 15 days post partum guppy showed the LC_{50} at 0.10 ppm indicating its high toxicity to guppy. The lethal effects were possible from nerve poison or gill impairment. Histological results supported the gill damage may be the cause of mortality. Acute toxicity of carbofuran depended on the exposure period, intensity of exposure and the susceptibility of target organism, which was influenced by age, sex and state of health. Carbofuran affected on behavior of guppy by less general activity, lost of equilibrium, spiral movement, increased respiration and death. The evidence changed in swimming behavior with acute toxicity because carbofuran caused neurologic effects.

In aquatic environment, organisms did not usually exposed to high concentration of insecticides or acute toxic. Unless they were restricted to the vicinity of a chemical release site or spill areas (Rand and Peteroceli, 1985). Beyond the initial impact site dilution and dispersion occurred decreasing these acute concentrations to lower concentration. Consequently, a greater biomass was exposed to sublethal concentrations of insecticides than to lethal concentrations. Many sublethal effects did

not persist as long-term exposure, therefore, it was commonly a return to normal conditions. The exposure to sublethal concentration of carbofuran in short-term period of natural and tap water showed the histopathology in gill, liver and kidney. The severity of lesions increased with concentration and time. The gill tissues showed more sensitivity and severity compared with liver and kidney after short-term exposure. However, the lesions in the gill tissues could be reversible whereas the lesions in liver and kidney could not be reversible after recovery period. The histological and histochemical results in target organs of guppy after exposed to carbofuran in both natural and tap water showed the same lesions and severity. These might be caused by the experiment period which was only 4 days. It was shorter than the half-life of carbofuran. Moreover, carbofuran can be degraded in water by hydrolysis and photolysis with or without microbial degradation. The results of short-term exposure indicated that carbofuran exposure, even in a short-term period, could induce histopathological alterations.

The exposure to sublethal concentration of carbofuran in long-term period for 5 months was studied. The growth rate of guppy and the histological changes in gill, liver, kidney and gonad were observed. The mean body weight of the treatment group in the 2nd, 3rd, 4th and 5th month of guppy was significantly lower than control groups ($P < 0.05$). Carbofuran induced a reduction in feeding rate, which is important because it could be related to reductions in an organism's energy assimilation that could lead to a reduction in resource allocation to growth, reproduction and survival.

The main target organs after long-term exposure to carbofuran were liver, kidney and gonad, whereas in short-term exposure it was the gill. It might occur because the gill is the important organ for survival. The lack of changes in gill in long-term exposure on guppy supported that the surviving fish were able to adapt physiologically or behaviourally to chronic exposure (Lease et al., 2003; Liber, Weber and Levesque, 2005). The short-term exposure of carbofuran could have long-term effects on the life cycles of fish, even though this compound did not persist for long in the water.

Histological changes were mainly observed in fish exposed over the short-term exposure periods while regenerative responses were noted in fish exposed over the long-term period and recovery period. Chronic inflammation was an infiltration by macrophages, instead of the influx of leukocytes commonly displayed in acute inflammation. Ongoing chemotaxis caused macrophages to infiltrate the inflamed site. These mechanisms led to fibroblast proliferation replace the normal connective tissue (Sommer and Porth, 2006). The lipid accumulation, a marker of imbalance lipid metabolism in liver cell, after exposed to carbofuran in short-term and long-term were significantly increased ($P<0.05$). Vacuolation of hepatocytes were associated with the inhibition of protein synthesis, energy depletion or shifts in substrate utilization (Hinton and Lauren, 1990). The vacuolation possibly resulted in nuclear degeneration, constriction of sinusoid and hepatic cord disarray. These responses indicated that biochemical alterations were severe enough to lead to structural changes at the tissue level. The negative PAS staining after short-term and long-term exposure period indicated that in treatment liver was not found glycogen accumulation. The depletion of glycogen might result from direct utilization of this compound to generate energy resulting in a rapid decrease in this energy reserve (Ribeiro et al., 2001; Dutra et al., 2009).

The histological results of gonad showed the damage of testis and ovarian structure. This result might lead to decrease the quality and quantity of offspring. The reproductive capability, live birth index, survival index and pregnant period were studied. The results showed that reproductive capability exposed to 0.05 ppm carbofuran was significantly reduced ($P<0.05$). Similarly, live birth index and survival index of offspring significantly decreased in treatment groups ($P<0.05$). Pregnant period in treatment groups were significantly increased ($P<0.05$). Significant findings on morphological abnormality of the offspring revealed that 2% of the newborn in 0.05 ppm treatment had two heads in one body, indicating teratogenic effects of carbofuran firstly described in a non-mammalian species. The results from this study suggested that

carbofuran could impair reproductive capability and reduce live birth index and the first generation (F_1) survival.

Overall, these experiments show adverse effects on small fish in cellular level and organism level (litter size, live birth index and survival percentage). The cautionary adverse effects of this compound suggests the need for further investigation of carbofuran effects on some other parameters significant in evaluating the risk to humans and animals in the environment.



ศูนย์วิทยทรัพยากร
จุฬาลงกรณ์มหาวิทยาลัย

REFERENCES

- Adams, S.M. 2002. Biological indicators of aquatic ecosystem stress. American Fisheries Society 3: 104-112.
- Adhikari, S., Sarkar, B., Chatterjee, A., Mahapatra, C.T., and Ayyappan, S. 2004. Effects of cypermethrin and carbofuran on certain hematological parameters and prediction of their recovery in a freshwater teleost, *Labeo rohita* (Hamilton). Ecotoxicology and Environmental Safety 58: 220-226.
- Adhikari, S., Sarkar, B., Chattopadhyay, A., Chattopadhyay, D.N., Sarkar, S.K., and Ayyappan, S. 2008. Carbofuran induced changes in breeding of a freshwater fish, *Labeo rohita* (Hamilton). Toxicological and Environmental Chemistry 20: 457-465.
- Ahdaya, S.M., Monroe, R.J., and Guthrie, F.E. 1981. Absorption and distribution of intubated insecticides in fasted mice. Pesticide Biochemistry and Physiology 16: 38-46.
- Ahdaya, S.M., and Guthrie, F.E. 1982. Stomach absorption of insecticides in fasted mice. Toxicology 22: 311-317.
- Alazemi, B.M., Lewis, J.W., and Andrews, E.B. 1996. Gill damage in the freshwater fish *Gnathonemus petersii* (family: Mormyridae) exposed to selected pollutants: an ultrastructural study. Environmental Technology 17(3): 225-238.
- American Society for Testing and Materials. 1980. Standard practice for conducting toxicity tests with fishes, macro-invertebrates and amphibians. ASTM E 729-780, Philadelphia: ASTM.
- Anat, T., and Paul, F.H. 2000. Pesticide use and residual occurrence Thailand. Environmental Monitoring and Assessment 60: 103-104.
- Andreotti, G., et al. 2010. Body mass index, agricultural pesticide use, and cancer incidence in the Agricultural Health Study cohort. Cancer Causes Control 21:1759-1775.

- Anton, F.A., Laborda, E., Laborda, P., and Ramos, E. 1993. Carbofuran acute toxicity to freshwater algae and fish. Environmental Contamination and Toxicology 50: 400-406.
- Araujo, C.V., et al. 2006. *In situ* and laboratory bioassays using *Poecilia reticulata* Peters in the biomonitoring of an acidic lake at Camacari, BA, Brazil. Chemosphere 65: 599-603.
- Areechon, N., and Plumb, J.A. 1990. Sublethal effects of carbamate and organophosphates on channel catfish, *Ictalurus punctatus*. Bulletin of Environmental Contamination and Toxicology 31: 155-159.
- Arellano-Aguilar, O., and Macias, G.C. 2009. Effects of methyl parathion exposure on development and reproduction in the viviparous fish *Girardinichthys multiradiatus*. Environmental Toxicology 24(2):178-86.
- Arthington, A.H., and Lloyd, L.L. 1989. Introduced poeciliids in Australia and New Zealand: Ecology and evolution of livebearing fishes (Poeciliidae). New Jersey: Prentice Hall.
- Athikesavan, S., Vincent, S., Ambrose, T., and Velmurugan, B. 2006. Nickel induced histopathological changes in the different tissues of freshwater fish, *Hypophthalmichthys molitrix* (Valenciennes). Journal of Environmental Biology 27(2): 391-395.
- Avila, G.G., Rodriguez, J.A., Garcia, A.N., Martinez, M.O., and Rangel, G.J. 2010. Multinucleation of spermatozoa and spermatids in infertile men chronically exposed to carbofuran. Review of Toxicology 29: 458-460.
- Aysel, C.K.B., Gulten, K., and Ayhan, O. 2008. Sublethal ammonia exposure of Nile tilapia (*Oreochromis niloticus* L.): Effects on gill, liver and kidney histology. Chemosphere 72: 1355-1358.
- Bailey, H.C., Digiorgio, C., Kroll, K., Miller, J., Hinton, D.E., and Starrett, G. 1996. Development of procedures for identifying pesticide toxicity in ambient waters: carbofuran, diazinon, chlorpyrifos. Environmental Toxicology and Chemistry 15(6): 837-845.

- Bakthavathsalam, R., and Reddy, Y.S. 1982. Toxicity and behavioural responses of *Anabas testudineus* (Bloch) exposed to pesticides. Indian Journal of Environmental Health 24(1): 65-68.
- Baligar, P.N., and Kaliwal, B.B. 2004. Carbofuran induced block of compensatory ovarian growth in hemicastrated albino mice. Toxicology 204(2-3): 87-95.
- Ballesteros, M.L., Bianchi, G.E., Carranza, M., and Bistoni, M.A. 2007. Endosulfan acute toxicity and histomorphological alterations in *Jenynsia multidentata* (Anablepidae, Cyprinodontiformes). Journal of Environmental Science and Health B42(4): 351-357.
- Banerjee, S., and Bhattacharya, S. 1994. Histopathology of kidney of *Channa punctatus* exposed to chronic nonlethal level of Elsan, mercury, and ammonia. Ecotoxicology and Environmental Safety 29(3): 265-275.
- Baron, R. L. 1991. Carbamate insecticides. In W.J., Jr. Hayes, and E.R., Jr. Laws (eds), Handbook of Pesticide Toxicology, pp. 3-6. New York: Academic Press.
- Barr, D.B., et al. 2010. Pesticide concentrations in maternal and umbilical cord sera and their relation to birth outcomes in a population of pregnant women and newborns in New Jersey. Science of the Total Environment 408: 790-795.
- Baser, S., Erkoc, F., Selvi, M., and Kocak, O. 2003. Investigation of acute toxicity of permethrin on guppy *Poecilia reticulata*. Cemosphere 51: 469-474.
- Beauvais, S.L., Jones, S.B., Parris, J.T., Brewer, S.K., and Little, E.E. 2001. Cholinergic and behavioral neurotoxicity of carbaryl and cadmium to larval rainbow trout (*Oncorhynchus mykiss*). Ecotoxicology and Environmental Safety 49: 84-90.
- Begum, G. 2004. Carbofuran insecticide induced biochemical alterations in liver and muscle tissues of the fish *Clarias batrachus* (Linn.) and recovery response. Aquatic Toxicology 66(1): 83-92.
- Begum, G., and Vijayaraghavan, S. 2001. Carbofuran toxicity on total lipids and free fatty acids in air breathing fish during exposure and cessation of exposure in vivo. Environmental Monitoring and Assessment 70: 233-239.

- Bender, M.E. 1969. Uptake and retention of malathion and carbamates by the carp. Fishery and Culture 31: 155-159.
- Brahmaprakash, G.P., Panda, S., and Sethunathan, N. 1987. Relative persistence of hexachlorocyclohexane, methyl parathion, and carbofuran in an alluvial soil under flooded and non-flooded conditions. Agricultural Ecosystems and the Environment 19: 29-39.
- Brethead, S., Saglio, P., Saligaut, C., and Auperin, B. 2002. Biochemical and behavioral effects of carbofuran in goldfish (*Carassius auratus*). Environmental Toxicology and Chemistry 21(1): 175-181.
- Brethead, S., Toutant, J.P., and Saglio, P. 2000. Effects of carbofuran, diuron, and nicosulfuron on acetylcholinesterase activity in goldfish (*Carassius auratus*). Ecotoxicology and Environmental Safety 47(2):117-124.
- Brewer, S.K., Little, E.E., Delonay, A.J., Beauvais, S.L., Jones, S.B., and Ellersieck, M.R. 2001. Behavioral dysfunctions correlated to altered physiology in rainbow trout (*Oncorhynchus mykiss*) exposed to cholinesterase-inhibiting chemicals. Environmental Contamination and Toxicology 40: 70-76.
- Butchiram, M.S., Tilak, K.S., and Raju, P.W. 2009. Studies on histopathological changes in the gill, liver and kidney of *Channa punctatus* (Bloch) exposed to alachlor. Journal of Environmental Biology 30(2): 303-306.
- Camilo, B.G., Wualberto, T., Socorro, S., and Laura, P. 2008. Contribution to vital statistic of guppy *Poecilia reticulata* Peters (Pisces: Cyprinodontiformes: Poecillidae) pond population Santa Marta, Colombia. Pan-American Journal of Aquatic Science 3: 335-339.
- Campbell, D. 1997. Technical evaluation of histopathology as an environmental monitoring tool for the mining industry in Canada literature review and comments. Ottawa: Globaltox international consultants.
- Capel, P.D., Larson, S.J., and Winterstein, T.A. 2001. The behavior of 39 pesticides in surface waters as a function of scale. Hydrological Processes 15: 1251-1269.

- Castro, B.B., Sobral, O., Guilhermino, L., and Ribeiro, R. 2004. An in situ bioassay integrating individual and biochemical responses using small fish species. Ecotoxicology 13: 667–681.
- Cengiz, E.I. 2006. Gill and kidney histopathology in the freshwater fish *Cyprinus carpio* after acute exposure to deltamethrin. Environmental Toxicology and Pharmacology 22: 200-204.
- Cengiz, E.I., Unlu, E., and Balci, K. 2001. The histopathological effects of Thiodan on the liver and gut of mosquitofish, *Gambusia affinis*. Journal of Environmental Science and Health B36 (1): 75-85.
- Cengiz, E.I., and Unlu, E. 2003. Histopathology of gills in mosquitofish, *Gambusia affinis* after long-term exposure to sublethal concentrations of malathion. Journal of Environmental Science and Health B38(5): 581-589.
- Cengiz, E.I., and Unlü, E. 2006. Sublethal effects of commercial deltamethrin on the structure of the gill, liver and gut tissues of mosquitofish, *Gambusia affinis*: A microscopic study. Environmental toxicology and pharmacology 21: 246-253.
- Chandra, S., Ram, R.N., and Singh, I.J. 2004. First ovarian maturity and recovery response in common carp, *Cyprinus carpio* after exposure to carbofuran. Journal of Environmental Biology 25(3): 239-249.
- Chatterjee, S. 1996. Studies on the effect of pesticide on reproduction of female catfish, *Heteropneustes fossilis* (Bloch). Ph. D. Thesis, Calcutta University, Calcutta, West Bengal, India.
- Chatterjee, S., and Ghosh, R. 1995. Toxicity of carbamate pesticide, carbofuran technical 75DB to the fertilization of eggs of catfish, *Heteropneustes fossilis* (Bloch). Bulletin of Environmental Contamination and Toxicology 55: 111-115.
- Chatterjee, S., Dutta, A.B., and Ghosh, R. 1997. Impact of carbofuran technical in the oocyte maturation of *Heteropneustes fossilis* (Bloch). Archives of Environmental Contamination and Toxicology 32: 426-430.

- Chatterjee, S., Kumar, D.A., and Ghosh, R. 2001. Disruption of pituitary-ovarian axis by carbofuran in catfish *Heteropneustes fossilis* (Bloch). Comparative Biochemistry and Physiology Part C: Toxicology and Pharmacology 129(3): 265-273.
- Cheville, N.F. 1994. Pathology: An Introduction to Interpretation. Ames: Iowa State University Press.
- Chris, N.G., Dietrich, P., Knut-Erik, T., and Nanne, J. 2007. Assessing the sensitivity of Atlantic salmon (*Salmo salar*) to dietary endosulfan exposure using tissue biochemistry and histology. Aquatic Toxicology 84: 346–355.
- Chiron, S., Torres, J.A., Fernandez-Alba, A., Alpendurada, M.F., and Barcelo, D. 1996. Identification of carbofuran and methiocarb and their transformation products in estuarine waters by On-Line Solid Phase Extraction Liquid Chromatography-Mass Spectrometry. Journal of Environmental Analytical Chemistry 65: 37-52.
- Chumraskul, P., Srirama, B., and Lertveerasirikul, S. 1995. Pesticide residue levels in fresh water and soil in central agricultural areas. Toxic substances news and reports 22(2): 66-76.
- Clement, J.G. 1985. Hormonal Consequences of Organophosphate Poisoning. Toxicological Science 5: 61-77.
- Colborn, T., Vom Saal, E.S., and Soto, A.M. 1993. Developmental effects of endocrine-disrupting chemicals in wildlife and humans. Environmental Health Perspective 110: 378-384.
- Collective of Authors SPA (State Phytosanitary Administration). 2002. Concentration effects of selected insecticides on brain acetylcholinesterase in the common carp *Cyprinus carpio*. Ecotoxicology and Environmental Safety 45: 49-54.
- Constanz, G.D. 1989. Reproductive biology of poeciliid fishes. Ecology and evolution of livebearing fishes Poeciliidae. New Jersey: Prentice Hall.
- Courtney, K.D., Andrew, J.E., Springer, J., and Dailey, L. 1989. Teratogenic evaluation of the pesticides. Journal of Environmental Science Health B22(1): 214-230.

- Crepeau, K.L., and Kuivila, K.M. 2000. Rice pesticide concentration in the Colusa Basin Drain and the Sarramento River, California 1990-1993. Journal of Environmental Quality 29: 926-935.
- Culling, C.F.A. 1963. Handbook of Histopathological Technique, 2nd ed. London: Butterworth.
- Dass, B.K., and Mukherjee, S.C. 2000. A histopathological study of carp (*Labeo rohita*) exposed to hexachlorocyclohexane. Veterinarski Archives 70: 169-180.
- Del Monte, U. 2005. Swelling of hepatocytes injured by oxidative stress suggests pathological changes related to macromolecular crowding. Medical Hypotheses 64: 818–825.
- Dembele, K., Haubruge, E., and Gaspar, G. 2000. Concentration effects of selected insecticides on brain acetylcholinesterase in the common carp (*Cyprinus carpio* L.). Ecotoxicology and Environmental Safety 45(1):49-54.
- Department of agriculture (DOA). 2002. A policy and master plan of agricultural pesticide 2002-2006. Bangkok: Ministry of Agricultural and Cooperatives.
- Department of agriculture (DOA). 2004. Pesticide residues in Chiangmai Province: Ministry of Agricultural and Cooperatives.
- Department of agriculture (DOA). 2007. Statistics of imported pesticides to Thailand. Bangkok: Ministry of Agricultural and Cooperatives.
- De Silva, P.M.C.S., and Samayawardhena, L.A. 2002. Low concentrations of lorsban in water result in far reaching behavioral and histological effects in early life stages in guppy. Ecotoxicology and Environmental Safety 53; 248-254.
- De Silva, P.M.C.S., and Samayawardhena, L.A. 2005. Effects of chlorpyrifos on reproductive performances of guppy (*Poecilia reticulata*). Chemosphere 58: 1293–1299.
- Deuel, L.E. Jr., Price, J.D., Turner, F.T., and Brown, K.W. 1979. Persistence of carbofuran and its metabolites, 3-Keto and 3-Hydroxy Carbofuran, under flooded rice culture. Journal of Environmental Quality 8(1): 23-26.

- Dietrich, D.R., and Krieger, H.O. 2009. Histological analysis of endocrine disruptive effects in small laboratory fish. New Jersey: John Wiley and Sons.
- Donald, J.E. 1992. The basic of toxicity testing. London: CRC.
- Dorough, H.W. 1968. Metabolism of furadan (NIA-10242) in rats and houseflies. Journal of Agricultural and Food Chemistry 16: 319-325.
- Dorough, H.W. 1983. Toxicological significance of pesticide conjugates. Journal of Toxicology and Clinical Toxicology 19: 637-659.
- Dutra, B.K., Fernandes, F.A., and Oliveira, G.T. 2008. Carbofuran-induced alterations in biochemical composition, lipoperoxidation, and Na⁺/K⁺ATPase activity of *Hyalella pleoacuta* and *Hyalella curvispina* in bioassays. Comparative Biochemistry and Physiology C147: 179–188.
- Dutra, B.K., Fernandes, F.A., Lauffer, A.L., and Oliveira, G.T. 2009. Carbofuran-induced alterations in the energy metabolism and reproductive behaviors of *Hyalella castroi* (Crustacea, Amphipoda). Comparative Biochemistry and Physiology Part C: Toxicology and Pharmacology 149(4): 640-646.
- Dutta, H.M., Richmonds, C., and Zeno, T. 1993. Effects of diazinon on the gills of bluegill sunfish *Lepomis macrochirus*. Journal of Environmental Pathology, Toxicology and Oncology 12(4): 219-227.
- Dutta, H.M., and Meijer, H.J. 2003a. Sublethal effects of diazinon on the structure of the testis of bluegill *Lepomis macrochirus*: a microscopic analysis. Environmental Pollution 125(3): 355-360.
- Dutta, H.M., and Meijer, H.J. 2003b. Histological examination of sublethal effects of diazinon on ovary of bluegill, *Lepomis macrochirus*. Environmental Pollution 121(1): 95-102.
- Eaton, D.L., and Gilbert, S.G. 2008. Principle of toxicology. In C.D. Klaassen (ed.), Casarett and Doull's: Toxicology the basic science of poisons, 7th ed., pp. 11-44. New York: McGraw-Hill.
- Eisler, R. 1985. Carbofuran hazards to fish, wildlife, and invertebrates: A Synoptic

- Review. Washington, DC., U.S. Fish and Wildlife Service. Biological Report No 85 (1.3), pp. 36.
- Eldredge, L.G. 2000. Numbers of Hawaiian species, Supplement 5. Bishop Museum Occasional papers 63: 3-8.
- ENDS. 1999. Industry glimpses new challenges as endocrine science advances. ENDS Report 290: 26-30.
- Environmental Protection Agent (EPA). 1991. Handbook of Environmental Fate and Exposure Data. Office of Environmental Health Hazard Assessment.
- Environmental Protection Agent (EPA). 2002. Public Health Goal for carbofuran in drinking water. Office of Environmental Health Hazard Assessment.
- Environmental Protection Agent (EPA). 2006. Interim Reregistration Eligibility Decision (IRED) Document for Carbofuran. Office of Environmental Health Hazard Assessment.
- Erkmen, B., Aliskan, M., and Yerli, S.V. 2000. Histopathological effects of cyphenothrin on the gills of *Lebistes reticulatus*. Veterinary and Human Toxicology 42(1): 5-7.
- Evans, D.H., Piermarini, P.M., and Choe, K.P. 2005. The multifunctional fish gill: dominant site of gas exchange, osmoregulation, acid-base regulation, and excretion of nitrogenous waste. Physiological Reviews 85: 97-177.
- Fanta, E., Flavia, S.A.R., Silvia, R., Ana, C.C.V., and Sandra, F. 2003. Histopathology of the fish *Corydoras paleatus* contaminated with sublethal levels of organophosphorus in water and food. Ecotoxicology and Environmental Safety 54: 119-130.
- FAO. 1982. Manual of methods in environment research part 6: Toxicity Test. Fisheries Technical paper No. 185, FAO.
- Finney, D. J. 1971. Probit Analysis. London: Cambridge University Press.
- Fisher, S.J., Galinat, G.F., and Brown, M.L. 1999. Acute toxicity of carbofuran to adult and juvenile flathead chubs. Environmental Contamination and Toxicology 63: 385-391.

- Frias-Espericueta, M.G., et al. 2008. Histological effects of a combination of heavy metals on Pacific White Shrimp *Litopenaeus vannamei* juveniles. Aquatic Toxicology 89(3): 152-157.
- Giari, L., Manera, M., Simoni, E., and Dezfuli, B.S. 2007. Cellular alterations in different organs of European sea bass *Dicentrarchus labrax* exposed to cadmium. Chemosphere 67(6): 1171-1181.
- Ghousia, B. 2004. Carbofuran insecticide induced biochemical alterations in liver and muscle tissues of the fish *Clarias batrachus* (Linn.) and recovery response. Aquatic Toxicology 66: 83-92.
- Gill, S.T., Pande, J., and Tewari, H. 1990. Hepatopathotoxicity of three pesticides in a freshwater fish, *Puntius conchoni* Ham. Journal of Environmental Science and Health A25(6): 653-663.
- Gopal, K., and Ram, M. 1995. Alteration in the Neurotransmitter levels in the brain of the Freshwater Snakehead fish (*Channa punctata*) exposed to carbofuran. Ecotoxicology 4: 1-4.
- Gregus, Z. 2008. Mechanisms of Toxicity. In C.D. Klaassen (ed.), Casarett and Doull's Toxicology the basic science of poisons, 7th ed., pp. 1-128. New York: McGraw-Hill.
- Grier, H.J. 1981. Cellular organization of the testis and spermatogenesis in fishes. American Zoology 21: 345-357.
- Goad, R.T., Goad, J.T., Atieh, B.H., and Gupta, R. C. 2004. Carbofuran-induced endocrine disruption in adult male rats. Toxicology Mechanisms and Methods 14(4): 233-239.
- Gupta, RC. 1994. Carbofuran toxicity. Journal of Toxicology and Environmental Health 43: 383-418.
- Gupta, R.C., Milatovic, D., and Dettbarn, W.D. 2001. Nitric oxide modulates high energy phosphates in brain regions of rats intoxicated with diisopropylphosphorofluoridate or carbofuran: prevention by N-tert-butyl-alpha-

- phenylnitron or vitamin. Archives of Environmental Contamination and Toxicology 75: 346–356.
- Gupta, R.C., Milatovic, S., Dettbarn, W.D., Aschner, M., and Milatovic, D. 2007. Neuronal oxidative injury and dendritic damage induced by carbofuran: protection by memantine. Toxicology and Applied Pharmacology 219(2-3): 97-105.
- Gurr, G. T. 1969. Biological staining Method. In C.P. Hickman, and P.F Trum (eds.), Fish physiology: The kidney, Vol. 1, 7th ed. New York: Academic Press.
- Hill, E.F., and Camardes, M.B. 1986. Lethal Dietary Toxicities of Environmental Contaminants and Pesticides to Coturnix. U.S. Department of the Interior, Fisheries and Wildlife Service, Washington, D.C., pp. 3-35.
- Hinsen, D.J., Parrish, P.R., Loser, J.I., Wilson, A.J. Jr., and Wilson, P.D. 1971. Chronic toxicity uptake and retention of Arochlor 1254 in two estuarine fishes. Bulletin of Environmental Contamination and Toxicology 6: 113-117.
- Hinton, D.E., and Lauren, D.J. 1990. Integrative histopathological effects of environmental stressors on fishes. American Fisheries Society Symposium 8: 51–66.
- Hinton, D.E., Segner, H., and Braunback, T. 2001. Toxic response of liver. In D. Shlenk and W.H. Benson (eds.), Target organ toxicity in marine and fresh water teleosts, pp. 224-268. London: Taylor and Francis.
- Hodgson, E. 2010. Toxicity testing. In E. Hodgson (ed.), Modern toxicology, 4nd ed., pp 409-456. New Jersey: John Wiley and Sons.
- Hoogduijn, M.J., Rakonczay, Z., and Genever, P.G. 2006. The effects of anticholinergic insecticides on human mesenchymal stem cells. Toxicological Sciences 94(2): 342-50.
- Hose, J. E., Cross, S.G., and Diehl, D. 1989. Reproductive impairment in a fish inhabiting a contaminated coastal environment off southern California. Environmental Pollution 57: 139-148.

- Houde, A. E. 1997. Sex, colour, and mate choice in Guppies. New Jersey: Princeton University Press.
- Howard, P. H. 1991. Handbook of Environmental Fate and Exposure Data for Organic Chemicals: Pesticides. Michigan: Lewis, pp. 3-15.
- Humason, G.L. 1979. Animal Tissue Techniques, 4th ed. San Francisco: Freeman.
- Hunn, J.B., Multer, E.P., and DeFelice, M.S. 1993. Fish and agricultural chemicals: safeguarding your pond. University of Missouri Extension. U.S.A.
- Ilaria, C., Michela, M., Cristiana, S., Lucia, L., and Silvano, F. 2003. Fish as bioindicators of brackish ecosystem health: integrating biomarker responses and target pollutant concentrations. Oceanologica Acta 26: 129–138.
- IRDC. 1981. Teratology and post natal study in the rat with carbofuran dietary administration. IRDC conducted for FMC Corporation.
- Jaeschke, H. 2008. Toxic Responses of the Liver. In C.D. Klaassen (ed.), Casarett and Doull's Toxicology the basic science of poisons, 7th ed., pp. 557-582. New York: McGraw-Hill.
- Jaffe, J. 1991. Pesticides Book. Philadelphia: W. B. Saunders.
- Jarrad, H.E., Delaney, K.R., and Kennedy, C.J. 2004. Impact of carbamate insecticides on olfactory neurophysiology and cholinesterase activity in coho salmon (*Oncorhynchus kisutch*). Aquatic Toxicology 69: 133-148.
- Jayatunga, Y.N.A., Dangalle, C.D., and Ratnasooriya. 1998a. Hazardous effects of carbofuran on pregnancy outcome of rats. Medical Science Research 26: 33-37.
- Jayatunga, Y.N.A., Dangalle, C.D., and Ratnasooriya. 1998b. Effects of midterm exposure to carbofuran on pregnancy outcome of rats. Medical Science Research 26: 679-683.
- Jiraungkoorskul, W., Upatham, E.S., Kruatrachue, M., Sahaphong, S., Vichasri-Grams, S., and Pokethitiyook, P. 2003. Biochemical and histopathological effects of glyphosate herbicide on Nile tilapia (*Oreochromis niloticus*). Environmental Toxicology 18: 260-267.

- Jo, E.H., et al. 2007. Chemical contaminants, health indicators, and reproductive biomarker responses in fish from the Colorado River and its tributaries. Science of the Total Environment 378: 376–402.
- John, K.R., Jayabalan, N., and George, M.R. 1993. Impact of sublethal concentrations of endosulfan on the histology of Cyprinus carpio liver and kidney. In: Proceedings of the National Seminar on Aquaculture Development in India – Problems and Prospects. 27-29 November 1990. pp. 179–182.
- Johnson, W.W., and Finley, M.T. 1980. Handbook of acute toxicity of chemicals to fish and aquatic invertebrates. Washington, D.C., Department of the Interior fish and wildlife services.
- Joshi, N., Dharmalata, M., and Sahu, A.P. 2007. Histopathological changes in liver of *Heteropneustes fossilis* exposed to cypermethrin. Journal of Environmental Biology 28(1): 35-37.
- Kamboj, A., Kiran, R., and Sandhir, R. 2006a. N-acetylcysteine ameliorates carbofuran-induced alterations in lipid composition and activity of membrane bound enzymes. Molecular and Cellular Biochemistry 286(1-2): 107-1014.
- Kamboj, A., Kiran, R., and Sandhir, R. 2006b. Carbofuran-induced neurochemical and neurobehavioral alterations in rats: attenuation by N-acetylcysteine. Experimental Brain Research 170(4): 567-575.
- Kamboj, A., and Sandhir, R. 2007. Perturbed synaptosomal calcium homeostasis and behavioral deficits following carbofuran exposure: neuroprotection by N-acetylcysteine. Neurochemical Research 32(3): 507-516.
- Kelce, W. R., Monosson, E., Gamcsik, M. P., Laws, S. C., and Gray, L. E., Jr. 1994. Environmental hormone disruptors: evidence that vinclozolin developmental toxicity is mediated by antiandrogenic metabolites. Toxicology and Applied Pharmacology 126: 276-285.
- Kidd, H., and James, D.R. 1991. The Agrochemicals Handbook. 3rd ed. Cambridge: Royal Society of Chemistry Information Services, pp 208.

- Kim, D.J., et al. 2009. Benomyl induction of brain aromatase and toxic effects in the zebrafish embryo. Journal of Applied Toxicology 2009 29(4): 289-294.
- Kime, D. E. 1999. Endocrine disrupting chemicals. Environmental Science and Technology 12: 27-48.
- Khan, D.A., Hashmi, I., Mahjabeen, W., and Naqvi, T.A. 2010. Monitoring health implications of pesticide exposure in factory workers in Pakistan. Environmental Monitoring and Assessment 168:231-240
- Kulshrestha, S.K., Arora, N., and Sharma, S. 1986. Toxicity of four pesticides on the fingerlings of Indian major carps *Labeo rohita*, *Catla catla* and *Cirrhinus mrigala*. Ecotoxicology and Environmental Safety 12: 114-119.
- Kumar, S. 2004. Occupational exposure associated with reproductive dysfunction. Journal of Occupational Health 46: 1-19.
- Klys, M., Kosun, J., Pach, J., and Kamenczak, A. 1989. Carbofuran poisoning of pregnant woman and fetus per ingestion. Journal of Forensic Sciences 34: 1413-1416.
- Lawrence, A.J., and Elliott, M. 2003. Introduction and Conceptual Model. In A.J. Lawrence and K. Hemingway (eds.), Effects of pollution on fish: Molecular effect and population responses, pp 1-12. Oxford: Blackwell Science.
- Larsen, B.K., and Perkins, E.J. 2001. Target organ toxicity in the kidney. In D. Shlenk and W.H. Benson (eds.), Target organ toxicity in marine and fresh water teleosts, pp. 90-150. London: Taylor and Francis.
- Lease, H.M., Hansen, J.A., Bergman, H.L., and Meyer, J.S. 2003. Structural changes in gills of Lost River suckers exposed to elevated pH and ammonia concentrations. Comparative Biochemistry and Physiology C 134): 491-500.
- Leblanc, G.A., and Buchwalter, DB. 2010. Basics of environmental toxicology. In E. Hodgson (ed.), Modern toxicology, 4nd ed., pp. 531-548. New Jersey: John Wiley and Sons.

- Liber, K., Weber, L., and Levesque, C. 2005. Sublethal toxicity of two wastewater treatment polymers to lake trout fry (*Salvelinus namaycush*). Chemosphere 61: 1123–1133.
- Luis Pedro, M.P., Paraiba, L.C., Folini, L.L., and Trevizan, L.R.P. 2005. Kinetic of carbosulfan hydrolysis to carbofuran and the subsequent degradation of the last compound in irrigated rice fields. Chemosphere 60: 149-156.
- Malins, D.C., and Ostrander, G.K. 1991. Perspectives in Aquatic Toxicology. Annual Review of Pharmacology and Toxicology 31: 371-399
- Mallatt, J. 1985. Fish gill structural changes induced by toxicants and other irritants, a statistical review. Canadian Journal of Fisheries and Aquatic Sciences 42: 63-648.
- Mani, K., and Saxena, P.K. 1985. Effect of safe concentrations of some pesticides on ovarian recrudescence in the freshwater murrel, *Channa punctatus* (Bl.): a quantitative study. Ecotoxicology and Environmental Safety 9(3): 241-249.
- McDonald, D.G. 1983. The effects of H ion upon the gill of fresh water fish. Canadian Journal of Zoology 61: 691–703.
- Mehmet, Y., Ali, G., and Kazim, E. 2004. Acute toxicity of alpha-cypermethrin to guppy *Poecilia reticulata*. Chemosphere 56: 381-385.
- Melaa, M., et al. 2007. Effects of dietary methyl mercury on liver and kidney histology in the neotropical fish *Hoplias malabaricus*. Ecotoxicology and Environmental Safety 68: 426–435.
- Metcalfe, R.L., et al. 1968. Metabolism of 2, 2-dimethy 2, 3-dihydrobenzofuranyl-7 N-methylcarbamate (Furadan) in plants, insects, and mammals. Journal of Agricultural and Food Chemistry 16: 300-311.
- Milatovic, D., Gupta, R.C., Dekundy, A., Montine, T.J., and Dettbarn, W.D. 2005. Carbofuran-induced oxidative stress in slow and fast skeletal muscles: prevention by memantine and atropine. Toxicology 208: 13–24.
- Miles, J.R.W., Tu, C.M., and Harris, C.R. 1981. A laboratory study of the persistence of carbofuran and its 3-hydroxy- and 3-keto-metabolites in sterile and natural

- mineral and organic Soils. Journal of Environmental Science and Health B16(4): 409-417.
- Moreno, H.D., Soler, F., Miguez, M.P., and Perez-Lopez, M. 2010. Brain acetylcholinesterase, malondialdehyde and reduced glutathione as biomarkers of continuous exposure of tench, *Tinca tinca*, to carbofuran or deltamethrin. Science of the Total Environment 408(21):4976-4983
- Morgan, M.E., and Parmeggiani, B. 1964. Regulation of glycogenolysis in muscle. Journal of Biological Chemistry 239: 2435–2439.
- Mustafa, C., Belda, E., and Sedat, V.Y. 2003. The effects of zeta cypermethrin on the gills of common guppy *Lebistes reticulates*. Environmental Toxicology and Pharmacology 14: 117-120.
- Nagahama, Y. 1994. Endocrine regulation of gametogenesis in fish. International Journal of Developmental Biology 38: 217–229.
- Nagahama, Y. 2000. Gonadal steroid hormones: major regulators of gonadal sex differentiation and gametogenesis in fish. In: Proceedings of the Sixth International Symposium on the Reproductive Physiology of Fish, Bergen, Norway, 4–9 July, 1999, pp. 211–222.
- Naravaneni, R., and Jamil, K. 2005. Cytogenetic biomarkers of carbofuran toxicity utilizing human lymphocyte cultures *in Vitro*. Drug and Chemical Toxicology 28: 359–372.
- Nielsen, L., and Baatrup, E. 2006. Quantitative studies on the effects of environmental estrogens on the testis of the guppy, *Poecilia reticulata*. Aquatic Toxicology 80: 140–148
- Nimmo, H. 1985. Environmental biological processes and ecotoxicology. London: CRC.
- Oliveira-Ribeiro, M., et al. 2006. Endometrial histology, microvascular density and caliber, and matrix metalloproteinase-3 in users of the Nestorone-releasing contraceptive implant with and without endometrial breakthrough bleeding. Contraception 73(6):634-40.

- Ortiz, J.B., De Canales, M.L.G., and Sarasquete, C. 2003. Histopathological changes induced by lindane (gamma-HCH) in various organs of fishes. Journal of Marine Science 67(1): 53–61.
- Pacheco, M., and Santos, M.A. 2002. Biotransformation, genotoxic, and histopathological effect of environmental contaminants in European eel (*Anguilla anguilla* L.). Ecotoxicology and Environmental Safety 53: 331-47.
- Palmer, A.K. 1997. Reproductive toxicity studies and their evaluation. In B. Ballantyne (ed.), Current approaches in toxicology, pp. 54-67. Dorchester: John Wright and Sons.
- Pant, N., Prasad, A.K., Srivastava, S.C., Shankar, R., and Srivastava, S.P. 1995. Effect of oral administration of carbofuran on male reproductive system of rat. Human and Experimental Toxicology 14: 889-894.
- Pant, N., Prasad, A.K., Srivastava, S.C., Shankar, R., and Srivastava, S.P. 1997. Effect of oral administration of carbofuran on male reproductive system of rat. Human and Experimental Toxicology 14: 889-894.
- Parrish, P.R. 1985. Acute toxicity test. In G.M. Rand and S.R. Petrocelli, (eds.), Fundamental of aquatic toxicology, pp. 1-57. Washington: Hemisphere.
- Pawar, K.R. 1994. Toxic and teratogenic effects of fenitrothion, BHC and carbofuran on the embryonic development of cyprinus *Carpio communis*. Environment and Ecology 12: 284-287.
- Peebua, P., Kruatrachue, M., Pokethitiyook, P., and Singhakaew, S. 2008. Histopathological alterations of Nile tilapia, *Oreochromis niloticus* in acute and subchronic alachlor exposure. Journal of Environmental Biology 29(3):325-331.
- Petrocelli, S.R. 1985. Chronic toxicity test. In G.M. Rand and S.R. Petrocelli (eds.), Fundamental of aquatic toxicology, pp. 96-109. Washington: Hemisphere.
- Perry, S.F., Roid, S.G., Wankiewicz, E., Tyer, V., and Gilmour, K.M. 1996. Physiological responses of rainbow trout *Concorhynchus mykiss* to prolonged exposure to soft water. Physiological Zoology 69: 1419-1441.

- Pollution Control Department (PCD). 1997. Pollution in Thailand. Ministry of Science, Technology and Environment.
- Pumchae, S. 2004. Histopathology of Nile Tilapia *Oreochromis niloticus* liver and kidney after long-term low level exposure to distilled liquors 30 degree. Thesis, Graduate school Chulalongkorn University, Thailand.
- Public Health Goal (PHG). 2000. Carbofuran. Prepared by Office of Environmental Health Hazard Assessment California Environmental Protection Agency Pesticide and Environmental Toxicology.
- Rabitto, I.S., et al. 2005. Effects of dietary Pb(II) tributyltin on neotropical fish, *Hoplias malabaricus*: histopathological and biochemical findings. Ecotoxicology and Environmental Safety 60: 147-1
- Radka, D. 2003. Acute toxicity of carbofuran to selected species of aquatic and terrestrial organisms. Plant Protection Science 39: 103-108.
- Ram, R.N., Singh, I.J., and Singh, D.V. 2001. Carbofuran induced impairment in the hypothalamo- neurohypophyseal-gonadal complex in the teleost, *Channa punctatus* (Bloch). Journal of Environmental Biology (3): 193-200.
- Rand, G.M., and Petrocelli, S.R. 1985. Introduction. In G.M. Rand and S.R. Petrocelli (eds.), Fundamental of aquatic toxicology, pp. 1-28. Washington: Hemisphere.
- Rastogi, A., and Kulshrestha, S.K. 1990. Effect of sublethal doses of three pesticides on the ovary of a carp minnow *Rasbora daniconius*. Bulletin of Environmental Contamination and Toxicology 45: 742-740.
- Rawat, D.K., Bais, V.S., and Agrawal, N.C. 2002. A correlative study on liver glycogen and endosulfan toxicity in *Heteropneustes fossilis* (Bloch.). Journal of Environmental Biology 23: 205-207.
- Recena, M.C.P., Pires, D.X., and Caldas, E.D. 2006. Acute poisoning with pesticides in the state of Mato Grosso do Sul, Brazil. Science of the Total Environment 357: 88-95.
- Ribeiro, S., Sousa, J.P., Nogueira, A.J.A., and Soares, A.M.V.M. 2001. Effect of endosulfan and parathion on energy reserves and physiological parameters of

- the terrestrial isopod *Porcellio dilatatus*. Ecotoxicology and Environmental Safety 49: 131–138.
- Richmonds, C., and Dutta, H.M. 1989. Histopathological changes induced by malathion in the gills of Bluegill *Lepomis macrochirus*. Bulletin of Environmental Contamination and Toxicology 43: 123–130.
- Riehl, R., and Baensch, H. A. 1994. Aquarium Atlas, 4th ed. Melle: Buensch (West Germany) 992 pp.
- Rhouma, K.B., Tebourbi, O., Krichah, R., and Sakly, M. 2001. Reproductive toxicity of DDT in adult male rats. Human and Experimental Toxicology 20: 393-397.
- Rukiya, V., Figen, U.E., Hilal, P., and Oner, K. 2003. Investigation of acute toxicity of deltamethrin on guppy *Poecilia reticulata*. Ecotoxicology and Environmental Safety 55: 82-85.
- Saglio, P., Trijasse, S., and Azam, D. 1996. Behavior effects of waterborne carbofuran in goldfish. Archives of Environmental Contamination and Toxicology 31: 232-238.
- Sakthivel, V., and Gaiwad, S. A. 2002. Tissue histopathology of *Gambusia affinis* under dimecron toxicity. Ecological and Environmental Conservation 8: 27-31.
- Saldana, T.M., et al. 2007. Pesticide exposure and self reported geatational diabetes mellitus in the agricultural health study. Diabetes Care 30: 529-534.
- Santhakumar, M., Balaji, M., and Ramudu, K. 2001. Gill lesions in the perch, *Anabas testudineus*, exposed to monocrotophos. Journal of Environmental Biology. 22(2): 87-90.
- Saradha, B., and Mathur, P.P. 2006. Effect of environmental contaminants on male reproduction. Environmental Toxicology and Pharmacology 21: 34-41.
- Sarkar, B., Chatterjee, A., Adhikari, S., and Ayyappan, S. 2005. Carbofuran and cypermethrin-induced histopathological alterations in the liver of *Labeo rohita* (Hamilton) and its recovery. Journal of Applied Ichthyology 21: 131-135.
- Satar, S., Satar, S., Sebe, A., and Yesilagac, H. 2005. Carbofuran poisoning among farm workers. Mount Sinai Journal of Medicine 72(6):389-392.

- Sayeed, I., Parvez, S., Pandey, S., Bin-Hafeez, B., Haque, R., and Raisuddin, S. 2003. Oxidative stress biomarkers of exposure to deltamethrin in freshwater fish, *Channa punctatus* Bloch. Ecotoxicology and Environmental Safety [Online]. Available from: <http://www.elsevier.com/locate/econenv>. [2009, May 21].
- Schlenk, D., and Benson, W.H. 2001. Target organ toxicity in Marine and Freshwater Teleosts. London: Taylor and Francis.
- Scholz, N.L., Truelove, N.K., Labenia, J.S., Baldwin, D.H., and Collier, T.K. 2006. Dose-additive inhibition of chinook salmon acetylcholinesterase activity by mixtures of organophosphate and carbamate insecticides. Environmental Toxicology and Chemistry 25(5):1200-1207.
- Scott, G.R., and Sloman, K.A. 2004. The effects of environmental pollutants on complex fish behavior: integrating behavioral and physiological indicators of toxicity. Aquatic Toxicology 68: 369-392.
- Seiber, J.N., Catahan, M.P., and Barril, C.R. 1978. Loss of carbofuran from rice paddy Water: chemical and physical factors. Journal of Environmental Science and Health B13(2): 131-148.
- Shah, P.V., Monroe, R.J., and Guthrie, F.E. 1981. Comparative rates of dermal penetration of insecticides in mice. Toxicology and Applied Pharmacology 59: 414-423.
- Sharpe, R.M., and Skakkebaek, N.E. 1993. Are oestrogens involved in falling sperm counts and disorders of the male reproductive tract. Lancet 29: 1392-1395.
- Shaw, B.J., Richard D., and Handy. 2006. Dietary copper exposure and recovery in Nile tilapia, *Oreochromis niloticus*. Aquatic Toxicology 76: 111-121.
- Sibonani, S.M., Johan Van Vurena, H.J., Irene, E.J., Barnhoornb, M., and Bornman, S. 2009. Histopathological changes in the reproductive system (ovaries and testes) of *Oreochromis mossambicus* following exposure to DDT. Environmental Toxicology and Pharmacology 28: 133-139.
- Singh, P.B., and Singh, V. 2008. Cypermethrin induced histological changes in gonadotrophic cells, liver, gonads, plasma levels of estradiol-17 β and 11-

- ketotestosterone, and sperm motility in *Heteropneustes fossilis* (Bloch). Chemosphere 72: 422-431.
- Srijunngam, J. 1998. Subchronic effects of neem *Azadirachta indica* A. Juss. seed extract on female reproductive system of tilapia *Oreochromis niloticus* Linn. Thesis, Graduate school Chulalongkorn University, Thailand.
- Smith, G.J. 1992. Toxicology and Pesticide Use in Relation to Wildlife: Organophosphorus and carbamate compounds. Florida: C.K. Smoley, pp 3-18.
- Sommer, C.V., and Porth, C.M. 2006. Inflammation, tissue repair, and fever. In C.M. Porth (ed.), Essential of pathophysiology, 2nd ed., pp. 150-167. Philadelphia: Lippincott Williams and Wilkins.
- Sprague, J.B., Schreck, C.B., and Moyle, P.B. 1990. Aquatic toxicity: Method for fish biology. American Fisheries Society. pp. 491-528.
- Srivastava, R.K., Yadav, K.K., and Trivedi, S.P. 2008. Devicyprin induced gonadal impairment in a freshwater food fish, *Channa punctatus* (Bloch). Journal of Environmental Biology 29(2):187-191.
- Stentiford, G.D., et al. 2003. Histopathological biomarkers in estuarine fish species for the assessment of biological effects of contaminants. Marine Environmental Research 55: 137-159.
- Talebi, K., and Walker, C.H. 1993. A comparative study of carbofuran metabolism in treated and untreated soils. Pesticide Science 39: 65-69.
- Thophon, S., et al. 2003. Histopathological alterations of white seabass, *Lates calcarifer*, in acute and subchronic cadmium exposure. Environmental Pollution. 121(3): 307-320.
- Tilak, K.S., and Yacobu, K. 2002. Toxicity and effect of fenvalerate on fish *Ctenopharyngodon idellus*. Journal of Ecotoxicological Environment Monitoting 12: 9-15.
- Titlic, M., Josipovic-Jelic, Z., and Punda, A. 2008. Headache caused by pesticides--a review of the literature. Acta medica Croatica 62(2): 233-236.

- Trotter, D., Kent, R., and Wong, M. 1991. Aquatic Fate and effect of carbofuran. Critical Reviews in Environmental Control 21(2): 137-176.
- Tucker, J.W., and Thomson, C.Q. 1987. Danger of using Organophosphorus pesticides and diesel oil in fish ponds. Aquaculture and Fisheries Management 13: 62-63.
- Tyler, C.R., and Sumpter, J.P. 1996. Oocyte growth and development in teleosts. Reviews in Fish Biology and Fisheries 6: 287.
- U.S.EPA. 1990. Drinking water criteria document on carbofuran. Washington, DC, U.S. Environmental Protection Agency, Office of water.
- U.S.EPA. 1991. Environmental Fact Sheet for Carbofuran. Washington, DC, US Environmental Protection Agency, Office of Pesticides and Toxic Substances.
- U.S.EPA. 1995. National primary drinking water regulations: Carbofuran. Washington, DC, U.S. Environmental Protection Agency, Office of water. EPA 811-F-95-003-f-T.
- Van Dyk, J.C., Pieterse, G.M., and Van Vuren, J.H.J. 2007. Histological changes in the liver of *Oreochromis mossambicus* (Cichlidae) after exposure to cadmium and zinc. Ecotoxicology and Environmental Safety 66: 432–440.
- Vassanthi, R.P., Baskaran, E., and Palanichamy, S. 1990. Influence of carbofuran on growth and protein conversion efficiency in some freshwater fishes. Journal of Ecological Biology 2: 58-88.
- Verma, S.R., Sarita, R., and Dalela, R.C. 1981. Pesticide induced physiological alterations in certain tissues of a fish. Toxicology Letters 9: 327-332
- Velmurugan, B., Mathews, T., and Cengiz, E.I. 2009. Histopathological effects of cypermethrin on gill, liver and kidney of fresh water fish *Clarias gariepinus* (Burchell, 1822), and recovery after exposure. Environmental Technology 30(13): 1453-1460.
- Velmurugan, B., Selvanayagam, M., Cengiz, E.I., and Unlu, E. 2007. The effects of fenvalerate on different tissues of freshwater fish *Cirrhinus mrigala*. Journal of Environmental Science and Health B42(2): 157-163.

- Vittozzi, L., and Anglis, G.D. 1991. A critical review of comparative acute toxicity data on freshwater fish. Aquatic toxicology 19: 167-204.
- Vos, J.G., et al. 2000. Health effects of endocrine-disrupting chemicals on wildlife, with special reference to the European situation. Critical Reviews in Toxicology 30: 71-133.
- Wattanasirmkit, K., and Thirakhupt. 2006. Effects of methyl parathion on gill, liver and kidney of Nile Tilapia *oreochromis niloticus* Linn. Journal of Science Research of Chulalongkorn University 131: 95-111.
- Wester, P.W., and Canton, J.H. 1987. Histopathological study of *Poecilia reticulata* after long term exposure to bis (trin-n-butyltin) oxide (TBTO) and di-n-butyltindichloride (DBTC). Aquatic Toxicology 10: 143-165.
- Wester, P.W., and Canton, J.H. 1991. The usefulness of histopathology toxicity studies in aquatic toxicity studies. Comparative Biochemistry and Physiology 100: 115-117
- Wester, P.W., Van der Ven, L.T.M., Vethaak, A.D., Grinwis, G.C.M., and Vos, J.G. 2002. Aquatic toxicology: opportunities for enhancement through histopathology. Environmental Toxicology and Pharmacology 11: 289-295.
- Whyatt, R.M., et al. 2003. Contemporary use pesticides in personal air samples during pregnancy and blood samples at delivery among urban minority mothers and newborns. Environmental Health Perspectives 111: 749-56.
- Wijeyaratne, W.M., and Pathiratne, A. 2006. Acetylcholinesterase inhibition and gill lesions in *Rasbora caverii*, an indigenous fish inhabiting rice field associated waterbodies in Sri Lanka. Ecotoxicology 15(7): 609-619.
- Willis, G.H., and McDowell, L.L. 1982. Review: pesticides in agricultural runoff and their effects on downstream water quality. Environmental Toxicology and Chemistry 1: 267-279.
- Winston, H.H., and Joan, E.D. 2000. Carbofuran: Public health goals for chemicals in drinking water. Office of Environmental Health Hazard Assessment.

- Wood, M.C. 2001. Toxic responses of the gill. In D. Schlenk, and W.H. Benson (eds.), Target organ toxicity in marine and freshwater teleosts Vol.1 - Organ, pp. 1-89. London: Taylor and Francis
- World Health Organization (WHO). 1999. The recommended classification of pesticides by hazards and guidelines to classification. World Health Organization, Geneva, World Health Organization, International Program on Chemical Safety (WHO/PCS/96.3).
- World Health Organization (WHO). 2004. Carbofuran in drinking-water. Geneva, World Health Organization, International Program on Chemical Safety. (WHO/SDE/WSH/03.04/81).
- World Health Organization (WHO). 2009. The WHO recommended classification of pesticides by hazards and guidelines to classification. Geneva, World Health Organization, International Program on Chemical Safety. (WHO/WA 240).
- Yasuno, M., Hatakeyama, S., and Miyashita, M. 1990. Effects on reproduction in the guppy (*Poecilia reticulata*) under chronic exposure to temphos and fenitrothion. Bulletin of Environmental Contamination and Toxicology 25: 29-33.
- Yenchum, W. 2004. Histopathology of common silver barb *Puntius gonionotus* liver at Klong 7 agricultural area, Pathum Thani Province. Thesis, Graduate school Chulalongkorn University, Thailand.
- Yousef, M.I., et al. 1995. Toxic effects of carbofuran and glyphosate on semen characteristics in rabbits. Journal of Environmental Science Health B20(4): 513-534.
- Yu, C.C., Booth, G. M., Hansen, D.J., and Larsen, J.R. 1974. Fate of Carbofuran in a Model Ecosystem. Journal of Agricultural and Food Chemistry 22(3): 431-434.
- Zeljezic, D., Vrdoljak, A.L., Kopjar, N., Radic, B., and Kraus, S.M. 2008. Cholinesterase-inhibiting and genotoxic effects of acute carbofuran intoxication in man: A Case Report. Basic and Clinical Pharmacology and Toxicology 103: 329-335

- Zeljezic, D., et al. 2007. Comparative evaluation of acetylcholinesterase status and genome damage in blood cells of industrial workers exposed to carbofuran. Food and Chemical Toxicology 45: 2488–2498.
- Zhang, Z., Hu, J., Zhen, H., Wu, X., and Huang, C. 2008. Reproductive inhibition and transgenerational toxicity of triphenyltin on medaka (*Oryzias latipes*) at environmentally relevant levels. Environmental Science and Technology 42(21): 8133-8139.
- Zhou, P., Liu, B., and Lu, Y. 2005. DNA damaging effects of carbofuran and its main metabolites on mice by micronucleus test and single cell gel electrophoresis. Science China Life Sciences 1:40-47.
- Zodrow, J.M., Stegeman, J.J., and Tanguay, R.L. 2004. Histological analysis of acute toxicity of 2,3,7,8-tetrachlorodibenzo-p-dioxin (TCDD) in zebrafish. Aquatic Toxicology 66: 25-38.
- Zutshi, B. 2005. Ultrastructural studies on the effect of fenthion on pituitary (GTH cells) and testis of *Glossogobius giuris*. (HAM) during breeding phase. Journal of Environmental Biology 26(1): 31-36.



APPENDICES

ศูนย์วิทยทรัพยากร
จุฬาลงกรณ์มหาวิทยาลัย

APPENDIX A
ACUTE TOCIXITY TEST DATA

Table 1-A Effective concentrations and 95% confidence limits of guppy *Poecilia reticulata* Peters from probit analysis program

Prob	CONC	95% Confidence Limits	
		Lower	Upper
0.01	.06322	-.10789	.07249
0.05	.06585	-.03658	.07581
0.10	.06752	.00025	.07922
0.15	.07174	.02382	.08353
0.20	.07506	.04098	.08671
0.25	.07635	.05379	.09563
0.30	.08199	.06336	.10559
0.35	.08722	.07060	.11643
0.40	.09219	.07632	.12787
0.45	.09699	.08111	.13969
0.50	.10172	.08533	.15182
0.55	.10644	.08921	.16428
0.60	.11124	.09292	.17718
0.65	.11621	.09657	.19069
0.70	.12144	.10028	.20506
0.75	.12708	.10417	.22069
0.80	.13337	.10839	.23820
0.85	.14070	.11322	.25871
0.90	.14992	.11919	.28462
0.95	.16358	.12789	.32317
0.96	.16756	.13040	.33442
0.97	.17245	.13348	.34827
0.98	.17896	.13755	.36669
0.99	.18921	.14394	.39575

APPENDIX B
LIPID ACCUMULATION DATA IN SHORT-TERM

Table 1-B The mean of lipid accumulation at 96 hours exposure period in liver tissue per $100 \mu\text{m}^2$ in natural water and tap water at various concentrations.

	Control	DMSO control	Treatment (Mean \pm SE)				
			0.005	0.010	0.025	0.040	0.050
Natural water	0.662 \pm 0.009 ^a	0.666 \pm 0.004 ^a	0.746 \pm 0.005 ^{ab}	0.823 \pm 0.003 ^b	1.199 \pm 0.005 ^c	1.855 \pm 0.006 ^d	1.888 \pm 0.004 ^d
Tap water	0.660 \pm 0.002 ^a	0.662 \pm 0.002 ^a	0.761 \pm 0.003 ^{ab}	0.820 \pm 0.002 ^b	1.199 \pm 0.009 ^c	1.865 \pm 0.006 ^d	1.876 \pm 0.003 ^d

Mean with different letters (a, b, c and d) within a row are significantly different ($P < 0.05$).

Table 2-B The mean of lipid accumulation at 96 hours exposure period in liver tissue per $100 \mu\text{m}^2$ in natural water at exposure period and recovery period.

	Control	DMSO control	Treatment (Mean \pm SE)				
			0.005	0.010	0.025	0.040	0.050
Exposure period	0.662 \pm 0.009 ^a	0.666 \pm 0.004 ^a	0.746 \pm 0.005 ^{ab}	0.823 \pm 0.003 ^b	1.199 \pm 0.007 ^c	1.855 \pm 0.006 ^d	1.888 \pm 0.004 ^d
Recovery period	0.663 \pm 0.002 ^a	0.0657 \pm 0.002 ^a	0.764 \pm 0.003 ^{ab}	0.846 \pm 0.004 ^{b*}	1.222 \pm 0.007 ^{b*}	1.864 \pm 0.006 ^d	1.878 \pm 0.006 ^d

Mean with different letters (a, b, c and d) within a row are significantly different ($P < 0.05$). Mean with different (*) within a column are significantly different ($P < 0.05$)

Table 3-B The mean of lipid accumulation at 96 hours exposure period in liver tissue per $100 \mu\text{m}^2$ in tap water at exposure period and recovery period.

	Control	DMSO control	Treatment (Mean \pm SE)				
			0.005	0.010	0.025	0.040	0.050
Exposure period	0.660 \pm 0.002 ^a	0.662 \pm 0.002 ^a	0.761 \pm 0.003 ^{ab}	0.820 \pm 0.002 ^b	1.199 \pm 0.009 ^c	1.865 \pm 0.006 ^d	1.876 \pm 0.003 ^d
Recovery period	0.661 \pm 0.002 ^a	0.0659 \pm 0.002 ^a	0.770 \pm 0.003 ^{ab}	0.851 \pm 0.002 ^{b*}	1.212 \pm 0.004 ^c	1.865 \pm 0.007 ^d	1.866 \pm 0.005 ^d

Mean with different letters (a, b, c and d) within a row are significantly different ($P < 0.05$). Mean with different (*) within a column are significantly different ($P < 0.0$)

APPENDIX C
LIPID ACCUMULATION DATA IN LONG-TERM

Table 1-C Mean of lipid accumulation (Mean \pm SE) in hepatic cells by computing area/ 100 μm^2 (n=25 / month)

Month	Control	DMSO control	Treatment
1	2.661 \pm 0.098	2.648 \pm 0.104	2.949 \pm 0.088
2	3.140 \pm 0.047	3.194 \pm 0.052	3.563 \pm 0.099*
3	3.401 \pm 0.066	3.397 \pm 0.055	4.134 \pm 0.067*
4	5.258 \pm 0.112	5.180 \pm 0.170	7.377 \pm 0.090*
5	5.480 \pm 0.110	5.510 \pm 0.121	7.419 \pm 0.079*

Mean with (*) within a row are significantly different ($P < 0.05$).

ศูนย์วิทยทรัพยากร
จุฬาลงกรณ์มหาวิทยาลัย

APPENDIX D
REPRODUCTIVE INDICED DATA

Table1-D Mean survival index of offspring with different concentration and different period

Day	Survival index (%)			
	(Mean±SE)			
	Control	DMSO control	Treatment 0.01 ppm 0.05 ppm	
1	99.22±0.33	99.69±0.21	91.80±0.72 ^a	73.32±2.48 ^b
2	99.22±0.33	99.69±0.21	91.80±0.72 ^a	73.32±2.48 ^b
3	99.22±0.33	99.69±0.21	90.68±0.83 ^a	69.31±2.45 ^b
4	99.22±0.33	99.69±0.21	90.68±0.83 ^a	69.31±2.45 ^b
5	99.22±0.33	99.69±0.21	90.68±0.83 ^a	68.18±2.42 ^b
6	99.22±0.33	99.69±0.21	90.68±0.83 ^a	68.18±2.42 ^b
7	99.22±0.33	99.69±0.21	90.68±0.83 ^a	68.18±2.42 ^b
8	99.22±0.33	99.69±0.21	90.68±0.83 ^a	68.18±2.42 ^b
9	99.22±0.33	99.69±0.21	90.68±0.83 ^a	68.18±2.42 ^b
10	99.22±0.33	99.69±0.21	90.68±0.83 ^a	68.18±2.42 ^b
11	99.22±0.33	99.69±0.21	90.68±0.83 ^a	68.18±2.42 ^b
12	99.22±0.33	99.69±0.21	90.68±0.83 ^a	68.18±2.42 ^b
13	99.22±0.33	99.69±0.21	90.68±0.83 ^a	68.18±2.42 ^b
14	99.22±0.33	99.69±0.21	90.68±0.83 ^a	68.18±2.42 ^b
15	99.22±0.33	99.69±0.21	90.68±0.83 ^a	68.18±2.42 ^b

Mean with (*) within a row are significantly different ($P < 0.05$).

APPENDIX E
ACCEPTANCE LETTER



JOURNAL OF HEALTH RESEARCH, EDITORIAL OFFICE

Office: 10th floor, College of Public Health Sciences, Chulalongkorn University, Institute Building 3, Soi Chulalongkorn 62,
Phayathai Road, Wangmai, Pathumwan, Bangkok, 10330, Thailand
Phone: +66 (0) 2218-8230 Fax: +66 (0) 2218-8195
E-mail: JHR@chula.ac.th Website: <http://www.jhr.cphs.chula.ac.th>

Acceptance Letter

Manuscript JHR No. 009

Date 29 March 2011

Dear Ms. Watiporn Yenchum,

The Journal of Health Research is pleased to accept your manuscript:

Reproductive toxicity effects of CARBOFURAN exposure on pregnant guppy *Poecilia reticulata*

Your paper is scheduled for publication in an upcoming issue of the Journal, but we do not give final citations to authors until going to press. I would, however, anticipate that your paper will appear in Vol. 25 No. 2 (June) 2011

Authors of accepted articles are requested to submit the completed copyright transfer form to the Editorial Office. Authors of each published article will receive a complimentary copy of the issue in which the article appears and 10 reprints. Additional reprints can be ordered at cost.

We appreciate your interest in the Journal, and we look forward to publishing your work.

Sincerely,

Robert Sedgwick Chapman, MD, MPH.

Editor

VITAE

Miss Watiporn Yenchum was born on November 21, 1979, in Nakhon Nayok Province, Thailand. She received a Bachelor's degree of Science in Biology, from Faculty of Science, Chulalongkorn University, in 2001. She graduated her Master's degree of Science in Zoology at the same institute in 2004. She continued her study for Ph.D in Biological Sciences Program, Faculty of Science, Chulalongkorn University in 2006 and completed program in 2010. She was awarded a scholarship by Development and Promotion of Science and Technology Talents Project (DPST) from 1998 to 2010.



ศูนย์วิทยทรัพยากร
จุฬาลงกรณ์มหาวิทยาลัย