

CHAPTER IV

RESULTS

***H. pylori* detection in rat stomach**

In this study, the method of *H. pylori* inoculation was using according to the method described by Thong-Ngam *et al.* [29]. It was performed that *H. pylori* was detected by positive either rapid urease test or histology. For overall results, there were 17 of 20 rats (85%) that were infected by *H. pylori*.

When the rapid urease test was performed, the gastric antrum mucosa was cut and examined the *H. pylori* urease activity. After that, the gastric tissue was fixed in 4% buffer paraformaldehyde at least one day, and embedded in paraffin. The tissue sections were stained with H&E following standard procedures. By histological examination, there were no *H. pylori* found in the control and curcumin control groups as shown in figure 18. However, in the *H. pylori* infected group, *H. pylori* were observed mainly in the antrum of stomach. There were both in the lumen and on the surface of epithelial cells as shown in the figure 19 and 20.

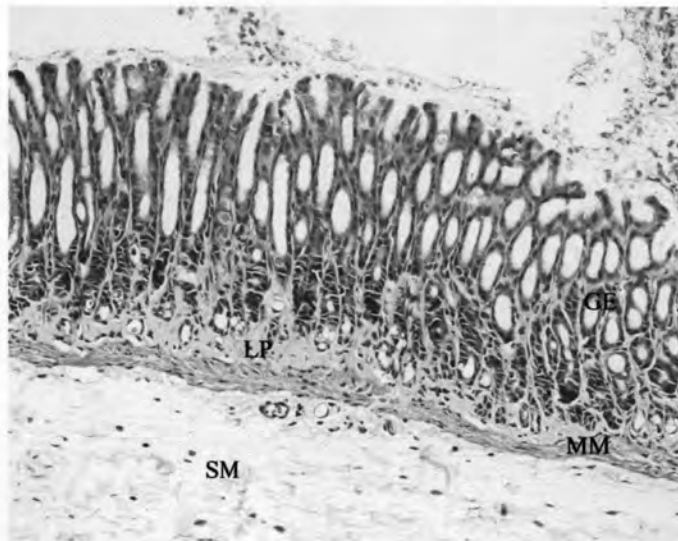


Figure 18 Histopathology of control group (H&E staining, $\times 10$); GE: gastric epithelium, LP: lamina propria, MM: muscularis mucosae, and SM: submucosa. In GE, holes surrounded by epithelial cells are gastric pits.

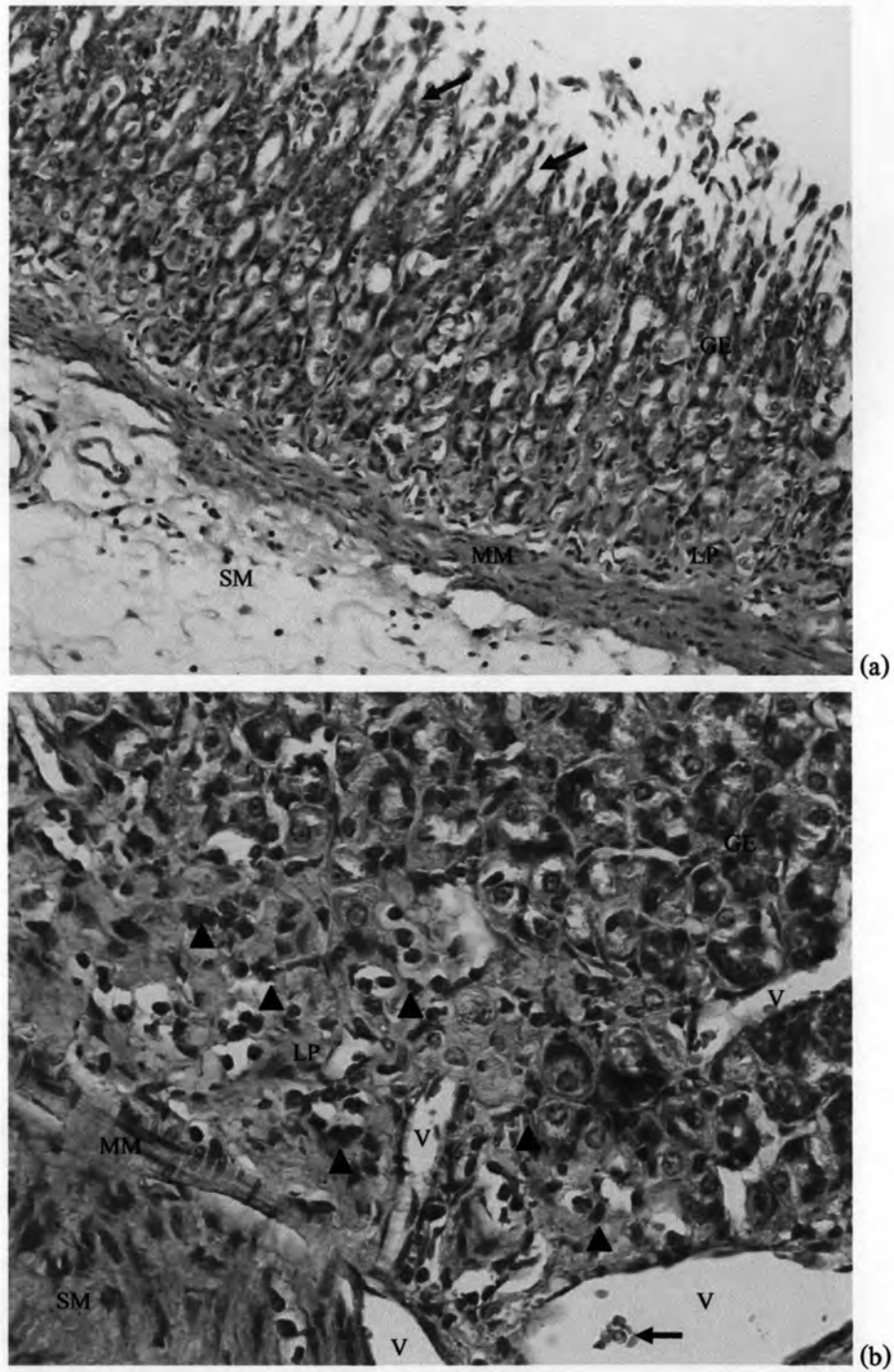


Figure 19 Histopathology of *H. pylori* infected group; GE: gastric epithelium, LP: lamina propria, MM: muscularis mucosae, SM: submucosa, and V: vessel. (a) Gastric mucosa from *H. pylori*-infected rat; note the epithelial erosion (arrows) (H&E staining, ×10). (b) Histology of rat in *H. pylori* infected group; note the infiltration by inflammatory cells (arrowheads) in LP. This section showed vessels surrounded by endothelial cells and filled with red blood cells (arrow) (H&E staining, ×40).

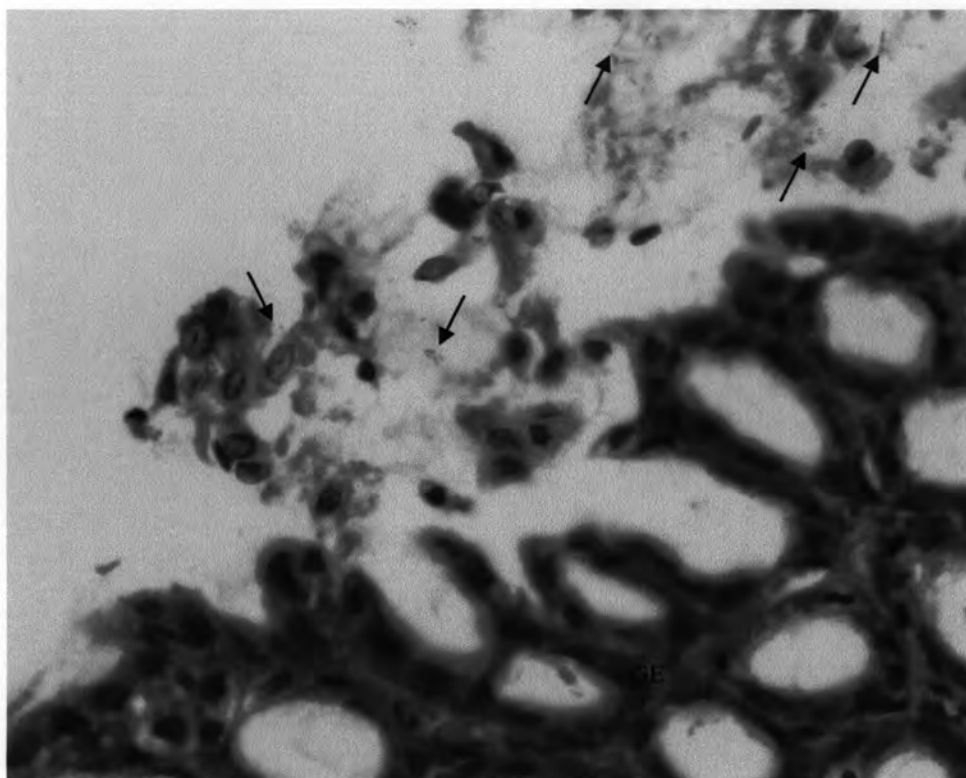


Figure 20 Histopathology of *H. pylori* infected group; GE: gastric epithelium *H. pylori* clumped on gastric epithelium (arrows) (H&E staining, $\times 100$).

Physiologic characters of *H. pylori* infection and role of curcumin

Two weeks after *H. pylori* inoculation and following one week of treatments, the changes of hemodynamic characters of animals were recorded. On the day of examination, the animals were monitored systolic blood pressure (SBP), diastolic blood pressure (DBP), and heart rate (HR) via catheter (PE 10, inner diameter 0.28 mm) by using the pressure transducer (Nihon Kohden). Mean arterial blood pressure (MAP) was calculated with this formula: $MAP = DBP + (SBP - DBP) / 3$. The mean and standard deviation (SD) of these parameters were shown in the table 2. There is no significant difference of these hemodynamic parameters among experimental groups.

Group	SBP (mmHg)	DBP (mmHg)	MAP (mmHg)	HR (beats/min)
control	139.7 ± 9.9	126.9 ± 12.3	131.1 ± 11.5	369.5 ± 29.5
curcumin control	137.2 ± 15.6	121.9 ± 14.7	127.0 ± 14.9	352.0 ± 56.5
<i>H. pylori</i> infected	141.4 ± 10.8	128.1 ± 11.6	132.6 ± 11.2	397 ± 16.7
200 mg/kg BW curcumin treated	140.6 ± 16.1	127.1 ± 17.1	131.6 ± 16.7	376.7 ± 35.6
600 mg/kg BW curcumin treated	150.2 ± 13.6	132.1 ± 10.1	138.1 ± 11.0	366.5 ± 25.6

Table 2 Mean ± SD of hemodynamic parameters, systolic blood pressure (SBP), diastolic blood pressure (DBP), mean arterial pressure (MAP), and heart rate (HR) of all experimental groups

Effects of *H. pylori* infection on gastric microvascular leakage and role of curcumin

The intravital fluorescent microscopic-technique showed that macromolecular leakage was observed by calculating the percentage of intensity ratio using the equation: $[(I_{out}/I_{in}) \text{ at } 30 \text{ minute} - (I_{out}/I_{in}) \text{ at } 0 \text{ minute}] \times [100 / (I_{out}/I_{in}) \text{ at } 0 \text{ minute}]$. From the results, the percentage of macromolecular leakage at the postcapillary venules (PCVs) of gastric mucosa was not significantly different between control group and curcumin control group. The percentage of macromolecular leakage significantly increased in *H. pylori* infected group compared with control group ($p = 0.001$). The average percentages of macromolecular leakage were $10.69\% \pm 1.43$, $9.74\% \pm 1.5$, and $15.41\% \pm 2.83$ in control, curcumin control, and *H. pylori* infected group, respectively. Two weeks after *H. pylori* inoculation followed by one week of gavage with 200 mg/kg BW or 600 mg/kg BW of curcumin, there was significant decrease of macromolecular leakage ($p < 0.05$) in both curcumin treated groups compared with *H. pylori* infected group. Interestingly, the average percentages of macromolecular leakage in both curcumin treated groups were similar to both control groups. The average percentages of macromolecular leakage of all groups were shown in table 3 and figure 21.

Group	Macromolecular leakage (%)	P (compared with control group)	P (compared with <i>H. pylori</i> infected group)
control	10.69 ± 1.43 [#]		0.001
curcumin control	9.74 ± 1.50 [#]	0.463	0.000
<i>H. pylori</i> infected	15.41 ± 2.83 [★]	0.001	
200 mg/kg BW curcumin treated	12.32 ± 2.13 [#]	0.216	0.025
600 mg/kg BW curcumin treated	12.14 ± 1.86 [#]	0.269	0.018

Note: [★] is represented significant difference compared with control group ($p < 0.05$).

[#] is represented significant difference compared with *H. pylori* infected group ($p < 0.05$).

The percentage of macromolecular leakage = $[(I_{out}/I_{in}) \text{ at 30 minute} - (I_{out}/I_{in}) \text{ at 0 minute}] \times [100 / (I_{out}/I_{in}) \text{ at 0 minute}]$

Table 3 Means ± SD of macromolecular leakage (%) of all experimental groups

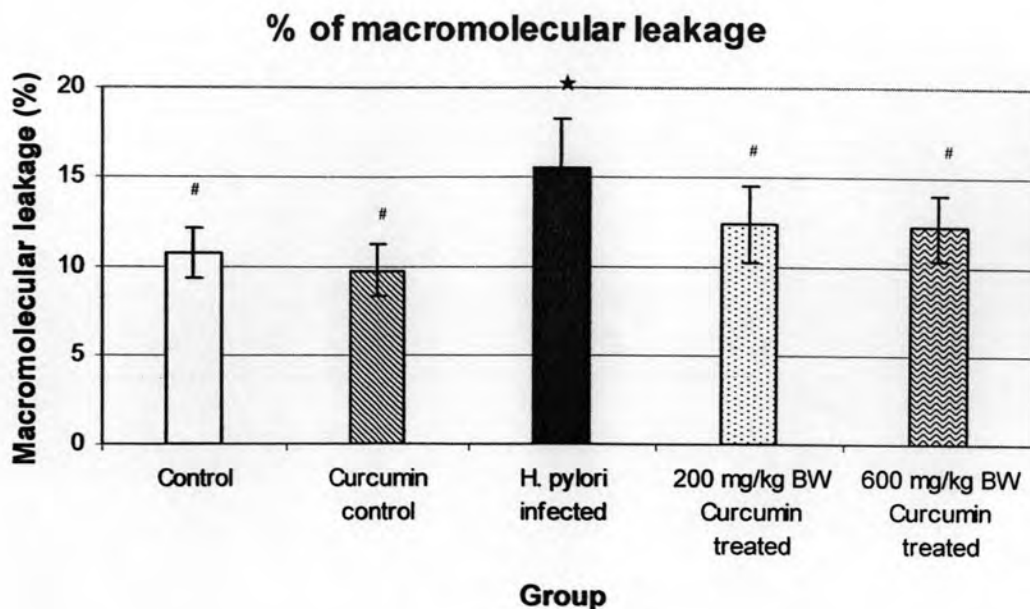


Figure 21 A bar graph shows the mean \pm SD of macromolecular leakage (%) of all experimental groups. Each group is represented by the mean of 5 rats. The sign \star is represented significant difference compared with control group ($p < 0.05$), and the sign $\#$ is represented significant difference compared with *H. pylori* infected group ($p < 0.05$).

The following figures showed intravital fluorescent images of all experimental groups at baseline (0 minute) and 30 minute after FITC-dx-250 injection. The vessels were fluoresced under fluorescent microscopy after FITC-dx-250 injection. By the time, at 30 minute, the leakage of macromolecules from the PCVs into the interstitial fluid was occurred. Therefore, the interstitial fluid was fluoresced.

In the gastric mucosal PCVs, blood must collectively flow from branches of hexagonal mucosal capillary to collecting venule. In addition, selected PCVs in this study were 15-30 μm in diameter. The intensity of fluorescence was measured at the same PCVs at 0 and 30 minute.

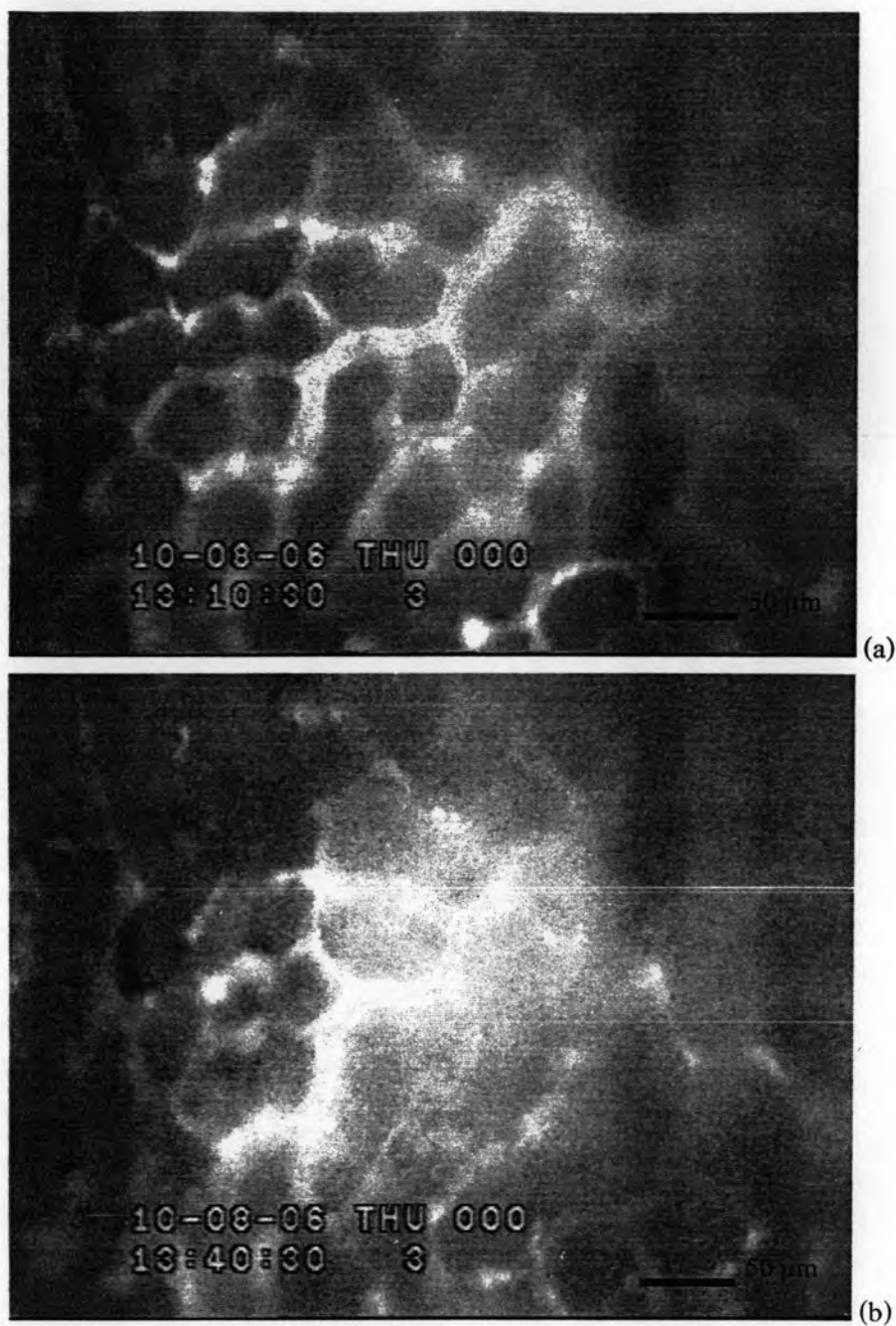


Figure 22 Intravital fluorescent microscopic images ($\times 20$) demonstrate macromolecular leakage from vessels to the interstitial fluid (increase intensity of fluorescence) by the time (0 and 30 minute) of control group. After FITC-dx-250 injection, the gastric mucosal vessels were fluoresced under fluorescent microscopy. (a) At 0 minute of FITC-dx-250 injection, the microvessels were visible (b) 30 minute after FITC-dx-250 injection, at the same area, the labelled macromolecules slightly leaked into the interstitial space.

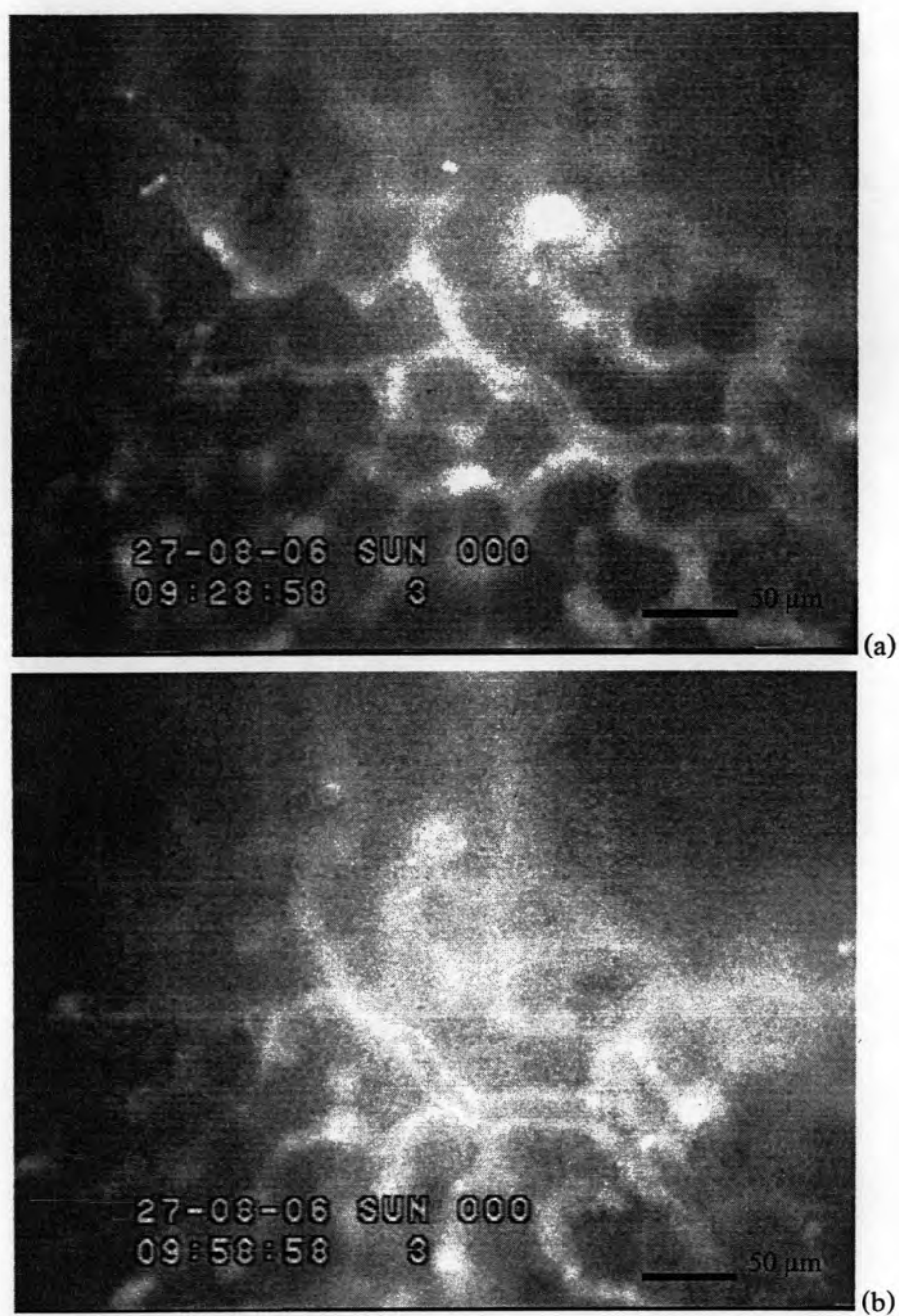
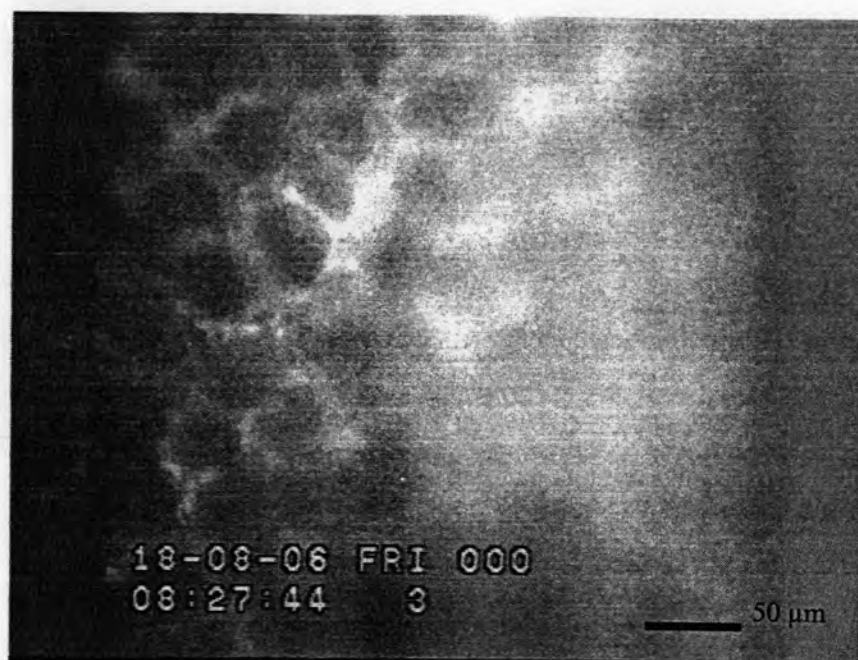
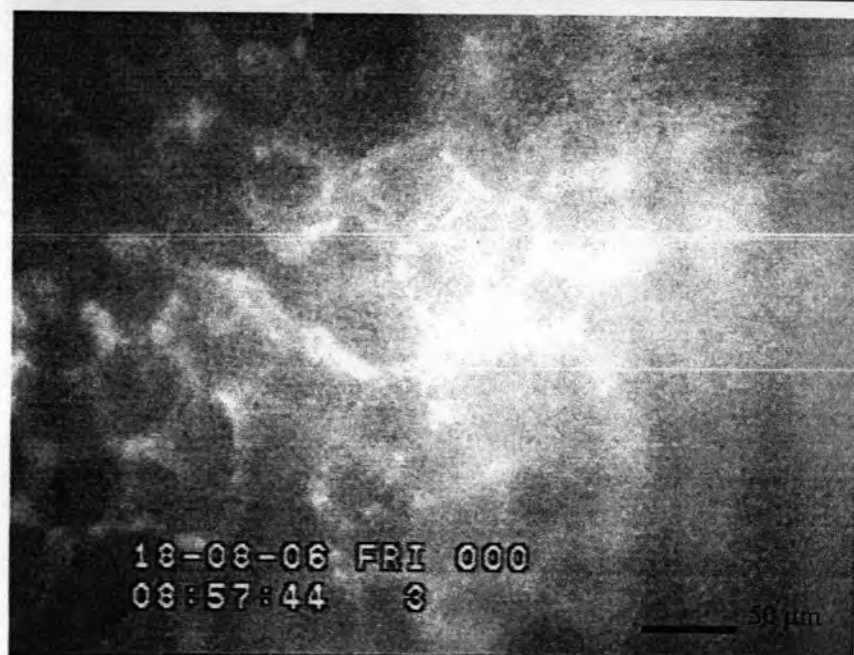


Figure 23 Intravital fluorescent microscopic images ($\times 20$) demonstrate macromolecular leakage from vessels to the interstitial fluid (increase intensity ratio) by the time (0 and 30 minute) of curcumin control group. After FITC-dx-250 injection, the fluorescence made the vessels visible. (a) At 0 minute of FITC-dx-250 injection, the microvessels were visible (b) 30 minute after FITC-dx-250 injection, at the same area, the labelled macromolecules slightly leaked into the interstitial space.



(a)



(b)

Figure 24 Intravital fluorescent microscopic images (X20) demonstrate macromolecular leakage from vessels to the interstitial fluid (increase intensity ratio) by the time (0 and 30 minute) of *H. pylori* infected group. After FITC-dx-250 injection, the fluorescence made the vessels visible. (a) At 0 minute of FITC-dx-250 injection, the microvessels were visible (b) 30 minute after FITC-dx-250 injection, at the same area, the labelled macromolecules leaked into the interstitial space, and resulted in high intensity ratio.

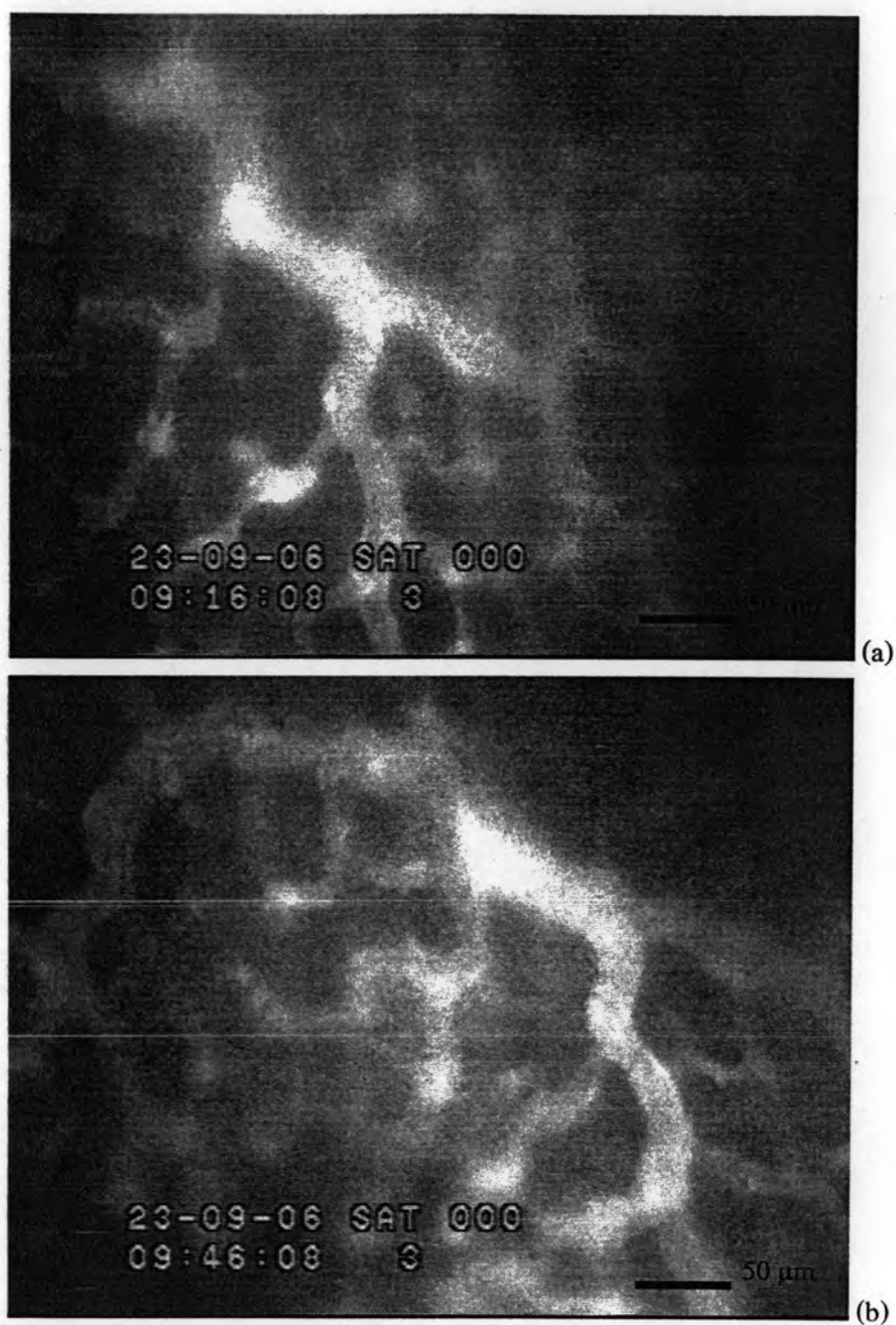


Figure 25 Intravital fluorescent microscopic images ($\times 20$) demonstrate macromolecular leakage from vessels to the interstitial fluid (increase intensity ratio) by the time (0 and 30 minute) of 200 mg/kg BW curcumin treated group. After FITC-dx-250 injection, the fluorescence made the vessels visible. (a) At 0 minute of FITC-dx-250 injection, the microvessels were visible (b) 30 minute after FITC-dx-250 injection, at the same area, the labelled macromolecules slightly leaked into the interstitial space.

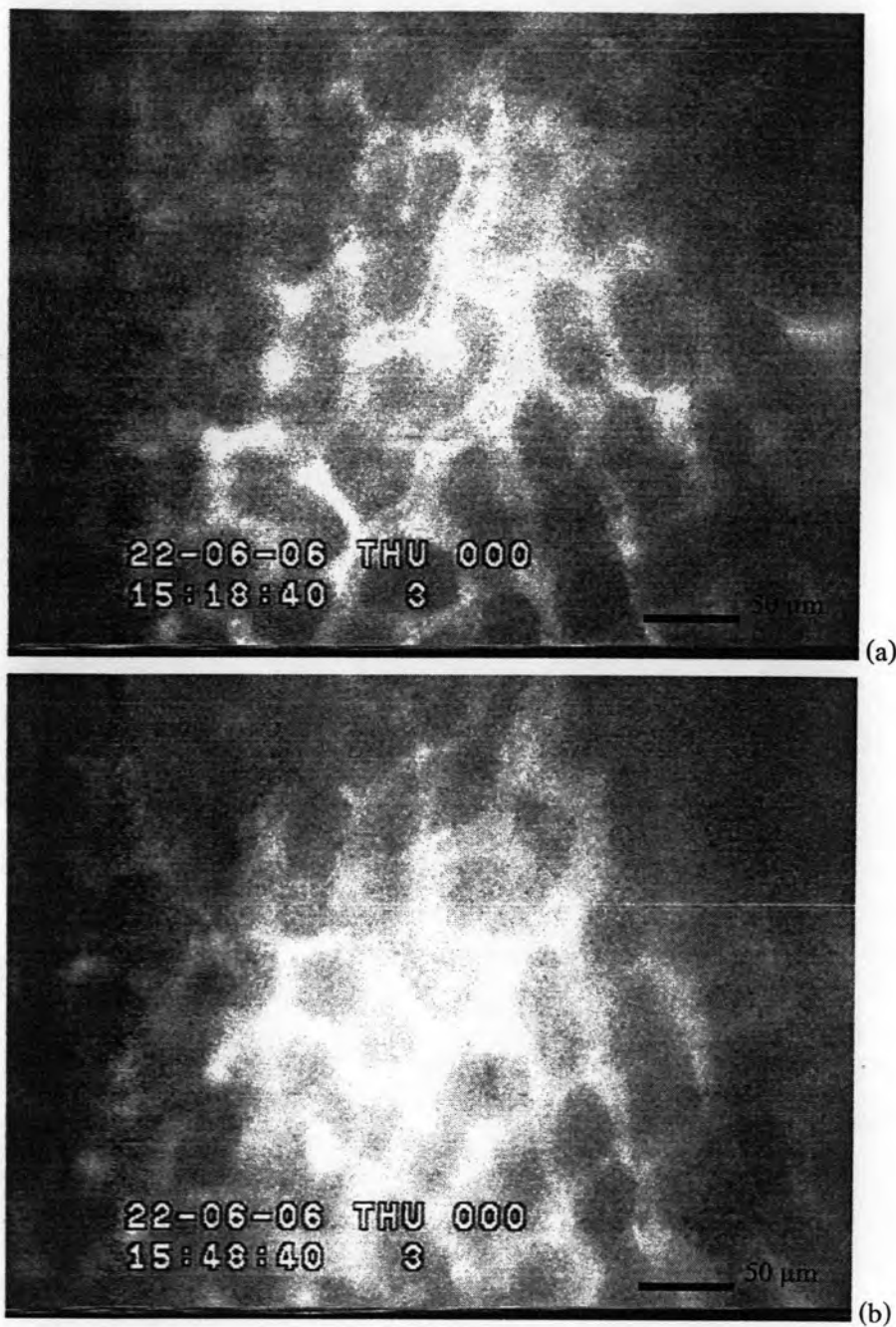


Figure 26 Intravital fluorescent microscopic images ($\times 20$) demonstrate macromolecular leakage from vessels to the interstitial fluid (increase intensity ratio) by the time (0 and 30 minute) of 600 mg/kg BW curcumin treated group. After FITC-dx-250 injection, the fluorescence made the vessels visible. (a) At 0 minute of FITC-dx-250 injection, the microvessels were visible (b) 30 minute after FITC-dx-250 injection, at the same area, the labelled macromolecules slightly leaked into the interstitial space.

Effects of *H. pylori* infection on serum VEGF level and role of curcumin

The serum VEGF level was determined by using ELISA assay. From the results, the serum VEGF levels were not significantly different between control group and curcumin control group. In *H. pylori* infected group, there was significant increase of serum VEGF level compared with control group ($p = 0.000$). The average concentrations of serum VEGF were $228.57 \text{ pg/ml} \pm 40.41$, $193.14 \text{ pg/ml} \pm 37.50$, and $619.43 \text{ pg/ml} \pm 145.68$ in control, curcumin control, and *H. pylori* infected group, respectively. After treating one week with 200 mg/kg BW or 600 mg/kg BW of curcumin, there were no significant decrease of serum VEGF concentration ($p > 0.05$) in both of curcumin treated groups compared with *H. pylori* infected group. In addition, the serum VEGF levels of 200 mg/kg BW and 600 mg/kg BW curcumin treated groups were significantly different compared with control group. The averages of serum VEGF level of all groups were shown in table 4 and figure 27

Group	Serum VEGF level (pg/ml)	P (compared with control group)
control	228.57 ± 40.41	
curcumin control	193.14 ± 37.50	0.689
<i>H. pylori</i> infected	619.43 ± 145.68 *	0.000
200 mg/kg BW curcumin treated	476.57 ± 181.34 *	0.010
600 mg/kg BW curcumin treated	480.57 ± 194.46 *	0.009

Note: * is represented significant difference compared with control group ($p < 0.05$).

Table 4 Means \pm SD of serum VEGF level (pg/ml) of experimental groups

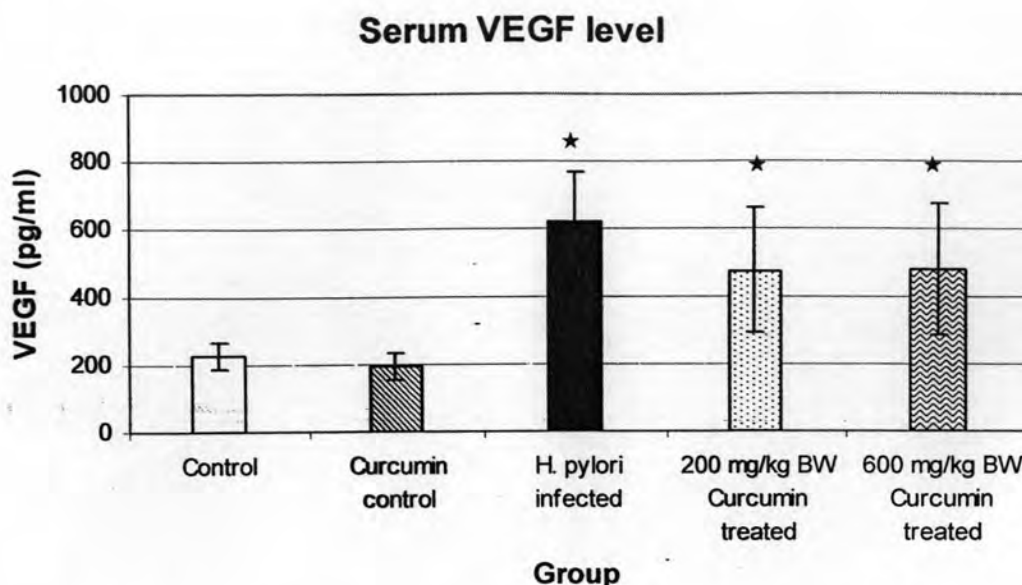


Figure 27 A bar graph shows the mean \pm SD of serum VEGF level (pg/ml) of experimental groups. Each group is represented by the mean of 5 rats. The sign * is represented significant difference compared with control groups ($p < 0.05$).

Effects of *H. pylori* infection on NF-KB p65 expression in gastric epithelial cells and role of curcumin

NF-KB p65 expression was studied by using immunohistochemistry and shown as cytoplasmic-stained cells. To validate the expression of NF-KB p65, the numbers of stained cells were counted. One thousand of gastric epithelial cells were counted for each rat. The data were shown as percent (%) of immunoreactive cells calculating from this equation: % of immunoreactive cells = (number of stained cells \times 100) / 1000. From the results, the percentage of immunoreactive cells was not significantly different between control group and curcumin control group. The percentage of immunoreactive cells was significantly increased in *H. pylori* infected group compared with control group ($p = 0.000$). The average percentages of NF-KB p65 antibody-stained cells were 28.58% \pm 2.82, 26.08% \pm 3.61, and 44.2% \pm 5.24 in control, curcumin control, and *H. pylori* infected group, respectively. After treatment with 200 mg/kg BW or 600 mg/kg BW of curcumin, the percentage of immunoreactive cells was significantly decreased in 200 mg/kg BW ($p = 0.001$) and 600 mg/kg BW ($p = 0.016$) compared with *H. pylori* infected group. The average percentages of immunoreactive cells of all groups were shown in table 5 and figure 28.

Group	Immunoreactive cells (%)	P (compared with control group)	P (compared with <i>H. pylori</i> infected group)
control	28.58 ± 2.82 [#]		0.000
curcumin control	26.08 ± 3.61 [#]	0.364	0.000
<i>H. pylori</i> infected	44.2 ± 5.24 [★]	0.000	-
200 mg/kg BW curcumin treated	33.99 ± 4.83 [#]	0.058	0.001
600 mg/kg BW curcumin treated	37.11 ± 4.34 ^{★#}	0.005	0.016

Note: [★] is represented significant difference compare with control group ($p < 0.05$).

[#] is represented significant difference compare with *H. pylori* infected group ($p < 0.05$).

Table 5 Means ± SD of Immunoreactive cells (%) of experimental groups

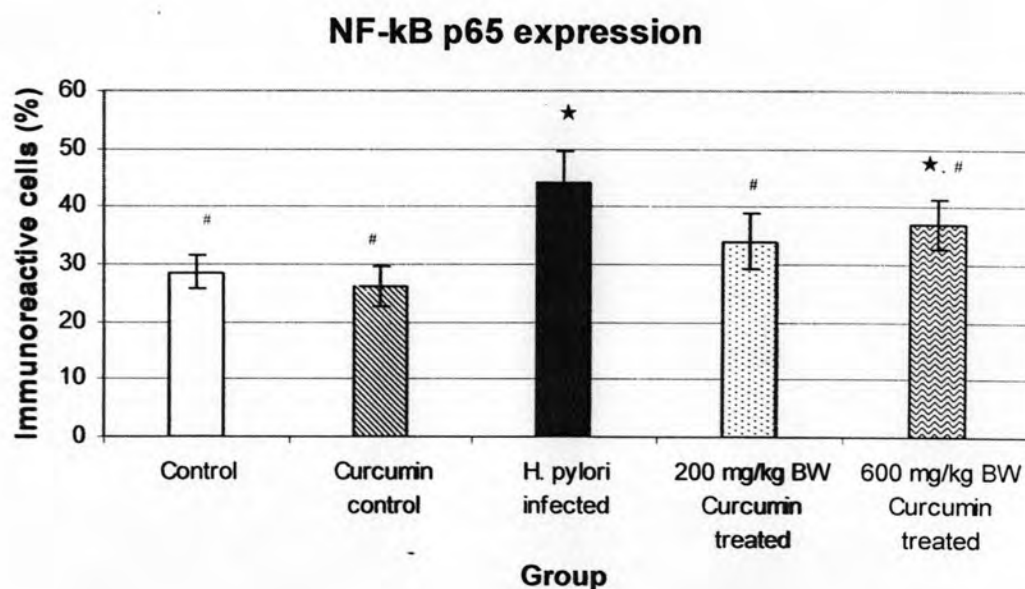


Figure 28 A bar graph shows the mean ± SD of NF-KB expression (%) of experimental groups. Each group is represented by the mean of 5 rats. The sign [★] is represented significant difference compare with control group ($p < 0.05$), and [#] is represented significant decrease compared with *H. pylori* infected group ($p < 0.05$).

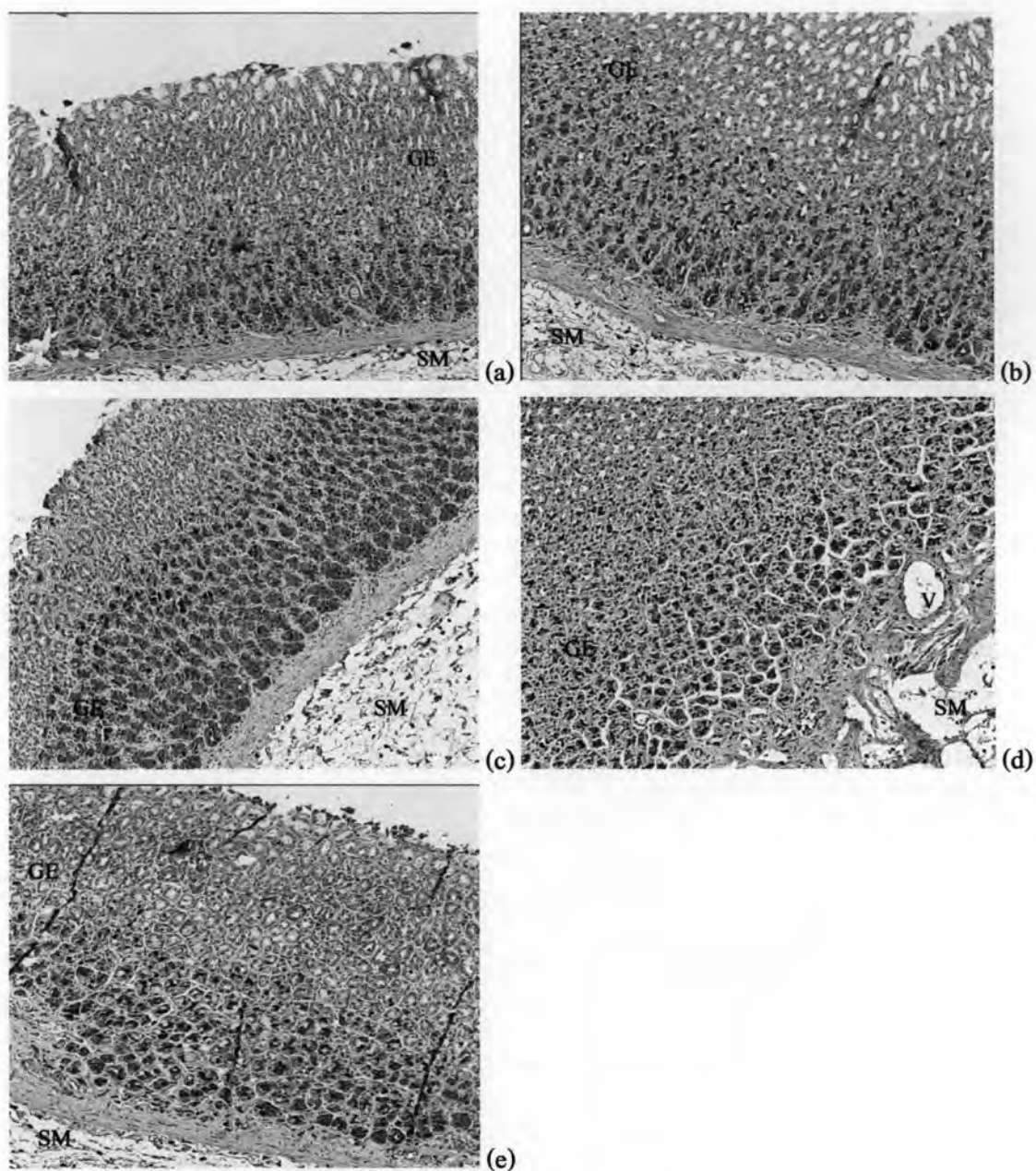


Figure 29 Immunohistochemical staining of NF-KB p65 antibody in representative tissue specimens: (a) control group, (b) curcumin control group, (c) *H. pylori* infected group, (d) 200 mg/kg BW curcumin treated group, and (e) 600 mg/kg BW curcumin treated group. DAB stained immunoreactive cells (dark brown); nuclear counterstaining was performed with hematoxylin ($\times 10$). The pattern of immunoreactive cells was different between control group and *H. pylori* infected group. In *H. pylori* infected group, immunoreactive cells were significantly increased. GE: gastric epithelium, SM: submucosa, and V: vessel.

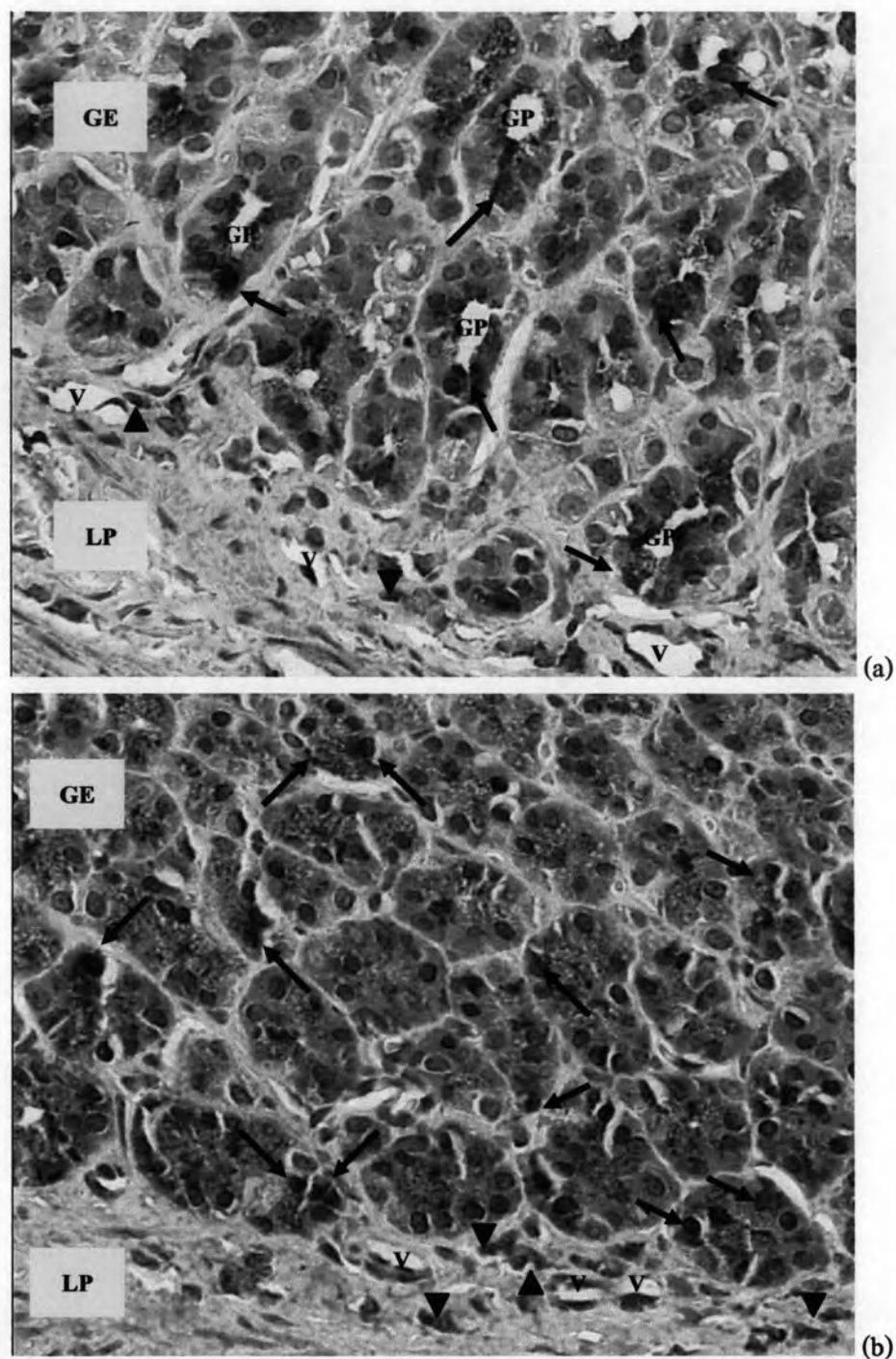


Figure 30 Immunohistochemical staining of NF-KB p65 antibody: DAB stained immunoreactive cells (dark brown); nuclear counterstaining was performed with hematoxylin ($\times 40$). (a) control group; some gastric epithelial cells (arrows) and immune cells (arrowheads) were stained. (b) *H. pylori* infected group; the most of gastric epithelial cells (arrows) and immune cells (arrowheads) were stained. GE: gastric epithelium, GP: gastric pit, LP: laminae propria, MM: muscularis mucosae, and V: vessel.