

## Clinicopathological study of testicular tumors diagnosed at King Chulalongkorn Memorial Hospital between January 1999 and July 2004

Narida Chirakalwasan\*

**Chirakalwasan N. Clinicopathological study of testicular tumors diagnosed at King Chulalongkorn Memorial Hospital between January 1999 and July 2004. Chula Med J 2004 Dec; 48(12): 789 - 801**

- Objective** : *To find out the prevalence, percentage and relative frequency of each testicular tumor, including the histopathologic features, mode of presentation and age distribution, at King Chulalongkorn Memorial Hospital between January 1999 and July 2004.*
- Setting** : *Department of Pathology, Faculty of Medicine, King Chulalongkorn Memorial Hospital*
- Research design** : *Retrospective descriptive study*
- Material and Method** : *All consecutive cases of testicular tumors diagnosed at the department of pathology, Faculty of medicine, King Chulalongkorn Memorial Hospital, during the period of 5 1/2 years from January 1999 to July 2004 were included in this study. Requisite forms, pathological reports and microscopic sections were reviewed.*
- Results** : *There were 26 cases of testicular tumors. The most common tumors were seminoma and lymphoma. The others were, in decreasing frequency, mixed germ cell tumors (15.38 %), leukemia (7.69 %), yolk sac tumor (3.85 %), embryonal carcinoma (3.85 %), metastatic prostatic adenocarcinoma (3.85 %) and malignant mesothelioma (3.85 %). Almost all cases presented with scrotal mass, the ages at the presentation range from 1 to 81 years. The involvement of the right testicle was slightly more frequent than the left side one.*

\* Department of Pathology, Faculty of Medicine, Chulalongkorn University

**Conclusion** : *Seminoma was the most common testicular tumors, similar to the reports from other institutions. Lymphoma was interestingly found to be as common as seminoma in this study. Other tumors were, in decreasing frequency, mixed germ cell tumors, leukemia, yolk sac tumor, embryonal carcinoma, metastatic prostatic adenocarcinoma and malignant mesothelioma. Nearly all of the other findings corresponded to previous studies.*

**Keywords** : Testicular tumors, Prevalence, Presentation.

Reprint request: Chirakalwasan N. Department of Pathology, Faculty of Medicine,  
Chulalongkorn University, Bangkok 10330, Thailand.

Received for publication. September 15, 2004.

สถาบันวิทยบริการ  
จุฬาลงกรณ์มหาวิทยาลัย

นฤดา จีรกาลวสาน. การศึกษาย้อนหลังเนื้องอกของลูกอัณฑะในโรงพยาบาลจุฬาลงกรณ์ ตั้งแต่เดือนมกราคม 2542 ถึงกรกฎาคม 2547. จุฬาลงกรณ์เวชสาร 2547 ๕.๓; 48(12): 789 - 801

- วัตถุประสงค์** : เพื่อศึกษาหาความชุก ร้อยละและความถี่สัมพันธ์ของเนื้องอกของลูกอัณฑะ รวมทั้งลักษณะทางพยาธิเนื้อเยื่อ อาการแสดงและอายุของผู้ป่วยในโรงพยาบาลจุฬาลงกรณ์ตั้งแต่เดือนมกราคม 2542- กรกฎาคม 2547
- สถานที่ทำการศึกษา** : ภาควิชาพยาธิวิทยา โรงพยาบาลจุฬาลงกรณ์
- รูปแบบการวิจัย** : การศึกษาย้อนหลังเชิงพรรณนา
- วิธีการศึกษาวัตถุผล** : ศึกษาข้อมูลจากใบส่งชิ้นเนื้อตรวจทางพยาธิวิทยา ใบรายงานผลทางพยาธิวิทยา และสไลด์แก้วของผู้ป่วยทั้งหมดที่ได้รับการวินิจฉัยเป็นเนื้องอกของลูกอัณฑะในโรงพยาบาลจุฬาลงกรณ์ ตั้งแต่เดือนมกราคม 2542- กรกฎาคม 2547
- ผลการศึกษา** : พบเนื้องอกของลูกอัณฑะทั้งหมด 26 ราย ได้รับการวินิจฉัยเป็น seminoma และ lymphoma มากที่สุด ( 61.53 %) ลำดับถัดมา ได้แก่ mixed germ cell tumors (15.38 %), leukemia (7.69 %), yolk sac tumor (3.85 %), embryonal carcinoma (3.85 %), metastatic prostatic adenocarcinoma (3.85 %) and malignant mesothelioma (3.85 %) ผู้ป่วยเกือบทั้งหมดมาด้วยก้อนที่ถุงหรือลูกอัณฑะ ช่วงอายุที่พบอยู่ระหว่าง 1 ปี ถึง 81 ปี โดยพบที่ข้างซ้ายบ่อยกว่าข้างขวาเล็กน้อย
- สรุป** : seminoma เป็นเนื้องอกของลูกอัณฑะที่พบได้บ่อยที่สุดในการศึกษานี้ เช่นเดียวกับการศึกษาอื่น ๆ ในขณะที่เป็นที่น่าสังเกตว่าความชุกของ lymphoma สูงกว่าการศึกษาอื่น ๆ มากและพบเป็นเนื้องอกของลูกอัณฑะที่พบบ่อยที่สุดร่วมกับ seminoma ข้อมูลอื่น ๆ เกือบทั้งหมดในการศึกษานี้สอดคล้องกับข้อมูลที่เคยศึกษามาก่อนหน้านี้
- คำสำคัญ** : เนื้องอกของลูกอัณฑะ, ความชุก, อาการแสดง

Testicular cancer is a rare disease, accounting for 1 % to 2 % of all neoplasms in men and boys.<sup>(1-3)</sup> It has an unusual age distribution with one peak in the incidence in young adults (age 20 - 39) and another peak in ages over 60.<sup>(3-4)</sup> Testicular tumors are divided into five general categories: germ cell tumors (GCTs), sex cord-stromal tumors, mixed germ cell-sex cord-stromal tumors, primary tumors not specific to the testis and metastatic tumors.<sup>(5)</sup> Germ cell tumors comprise up to 83 to 95 % of testicular cancer.<sup>(6-7)</sup> Cryptorchidism, a prior testicular germ cell tumor, a family history of testicular germ cell tumors and somatosexual ambiguity syndromes are well-established risk factors.<sup>(3,5,8-10)</sup> Amongst these, seminoma is the most common tumor<sup>(3,6-8)</sup> followed by mixed germ cell tumors.<sup>(7)</sup> Lymphoma, although comprising only about 5 % of all testicular malignancies, is the most common testicular tumor in elderly persons.<sup>(5,8,11)</sup> The patients with testicular tumors are usually diagnosed with the presence of scrotal mass or swelling.<sup>(7,12-14)</sup> The purpose of this study is to report the prevalence, percentage and relative frequency of each testicular tumor, including histopathologic features, mode of presentation and age distribution, at King Chulalongkorn Memorial Hospital between January 1999 and July 2004.

### Materials and Methods

All cases of testicular tumors diagnosed at the department of pathology, Faculty of Medicine, King Chulalongkorn Memorial Hospital, during January 1999 to July 2004 were included in this study. Requisite forms, pathological reports and microscopic sections, including hematoxylin and eosin staining and immunostaining, were reviewed by the author. Prevalence, percentage and relative frequency of each

testicular tumor were analyzed. Histopathologic features, modes of presentation including the side of the testicular involvement and age distribution were also assessed.

### Results

Between January 1999 and July 2004, there were 26 cases of testicular tumors diagnosed in the department of pathology, Faculty of Medicine, King Chulalongkorn Memorial Hospital. Twenty three and 3 cases were orchidectomy and incisional biopsy specimens, respectively. The ages of the patients ranged from 1 to 81 years (mean = 36.9 years). Almost all the patients were found to have scrotal or testicular mass in various durations, ranging from 1 week to 1 year. Orchidectomy was done in one case due to the underlying prostatic adenocarcinoma. There were 10, 12 and 4 cases involving right, left and bilateral testis, respectively. In the group with bilateral involvement, half of them were considered to be synchronous tumor. Microscopy showed seminoma in 8 cases, lymphoma in 8 cases, mixed germ cell tumor in 4 cases, leukemia in 2 cases, yolk sac tumor in 1 case, embryonal carcinoma in 1 case, metastatic prostatic adenocarcinoma in 1 case and malignant mesothelioma in 1 case. The number, percentage, relative frequency and range of age of each testicular tumor are shown in Table 1. Cryptorchidism was found in 6 cases (4 cases of seminoma, 1 case of embryonal carcinoma and 1 case of mixed germ cell tumor). The cases that showed tumors involving bilateral testis were 2 cases of seminoma (synchronous and metachronous tumors), 1 case of lymphoma (metachronous tumor) and 1 case of leukemia (synchronous tumor).

**Table1.** The number, percentage, relative frequency and range of age of each testicular tumor in Chulalongkorn Memorial Hospital between January 1999 and July 2004.

Tumor type	Number of cases	Frequency (%)	Range of age
Seminoma	8	30.77	22-43
Lymphoma	8	30.77	9-81
Mixed germ cell tumor	4	15.38	19-35
Leukemia	2	7.69	5-7
Yolk sac tumor	1	3.85	1
Embryonal carcinoma	1	3.85	20
Malignant mesothelioma	1	3.85	54
Metastatic prostatic adenocarcinoma	1	3.85	72
<b>Total</b>	<b>26</b>	<b>100</b>	

All 8 cases of the seminoma were of the classic types. The tumors were composed of diffuse, sheet-like or confluent multinodular patterns. The individual tumor cells were uniform with abundant clear to lightly eosinophilic cytoplasm, sharply outlined cell membranes, a large centrally located nucleus and one or two large central nucleoli. Branching fibrous septa with varying number of lymphocytic infiltrates occurred in all cases (Figure 1). Two cases displayed lymphoid follicle formation with germinal center. Neither syncytiotrophoblastic cell nor granuloma was seen in any cases. Anaplastic features were also absent in these cases. The age at presentation ranged from 22 to 43 years with a mean age of 30.5 years. The tumors involved the right, left and bilateral testis in 3 cases, 3 cases and 2 cases, respectively. In the bilateral group, one of them was metachronous tumor with an interval between tumors of 2 years.

Eight cases of lymphoma, based on WHO criteria, 6 cases were classified as diffuse large B cell lymphoma, 1 as T cell lymphoblastic lymphoma

and 1 as Burkitt lymphoma. All cases except the last one were assumed to represent a primary neoplasm of testicular origin due to the absence of other sites involvement. Most testes were diffusely involved by the malignant cells (Figure 2) with only two cases showing distinct interstitial pattern. The ages at presentation of diffuse large B cell lymphoma ranged from 60 to 81 years with a mean age of 66 years. T cell lymphoblastic lymphoma and Burkitt lymphoma were presented at the ages of 9 and 12 years. The tumor involved right, left and bilateral testis in 3 cases, 4 cases and 1 case, respectively. The bilateral tumor was metachronous with an interval between tumors of 3 years.

Each case of mixed germ cell tumors was composed of embryonal carcinoma and seminoma in the proportion of 9:1; teratoma, embryonal carcinoma, yolk sac tumor and choriocarcinoma in the proportion of 6:2:1:1; yolk sac tumor, embryonal carcinoma and teratoma in the proportion of 7:2:1 and seminoma and embryonal carcinoma in the proportion of



1:1 (Figure 3 - 4). CD 30, beta human chorionic gonadotrophin ( $\beta$ HCG), alpha fetoprotein (AFP) were used to confirm the components of embryonal carcinoma, choriocarcinoma and yolk sac tumor, respectively in the equivocal cases. The age at presentation ranged from 19 to 35 years with a mean age of 27.75 years. The tumor involved the right and left testis in 1 case and 3 cases, respectively.

Both cases of leukemia were acute lymphoblastic types involving left-sided and bilateral testis. Testicular interstitial infiltration of the tumor cells were the predominant features (Figure 5). The ages at presentation were 5 and 7 years.

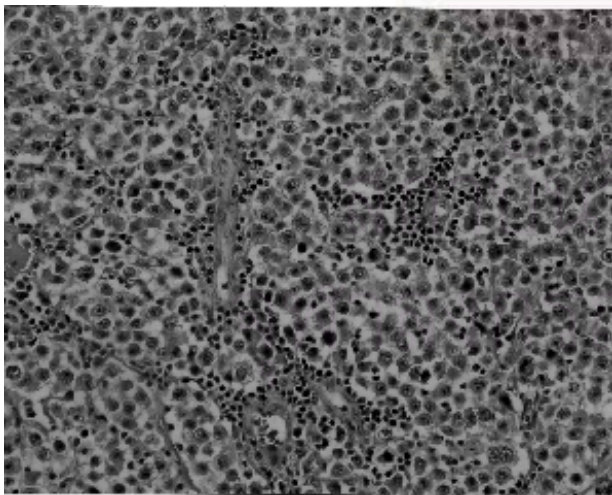
Yolk sac tumor and embryonal carcinoma were present at the ages of 1 and 20 years and involved left and right-sided testis, respectively. The former displayed mixed microcystic, endodermal sinus and glandular-alveolar patterns. The latter also demonstrated typical features of embryonal

carcinoma comprising solid sheets of undifferentiated cells with focal papillary and glandular formations.

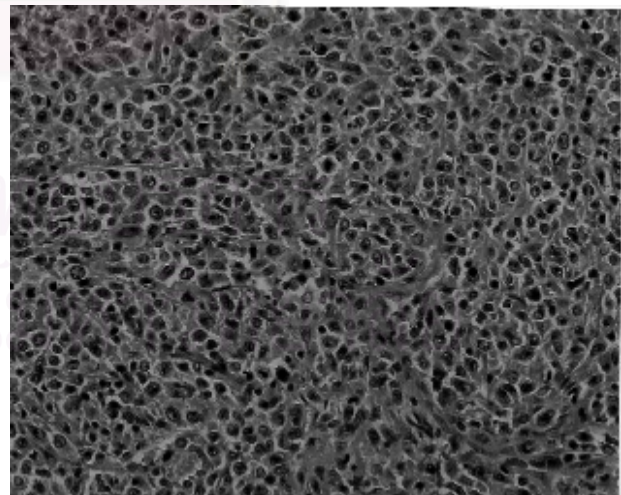
The case of malignant mesothelioma was composed of epithelial and mesenchymal components. The epithelial part displayed solid sheet and glandular arrangement. Spindle-shaped cells reminiscent smooth muscle cell were the mesenchymal component. The tumor cells were stained positively with cytokeratins (KB) and epithelial membrane antigen (EMA); the reverse was true for AFP and CD30 immunostainings. The age at presentation was 54 years. The tumor involved the right-sided testis.

Metastatic prostatic adenocarcinoma was considered as Gleason score 7. This patient presented with dysuria at the age of 72 year and the tumor involved the right-sided testis.

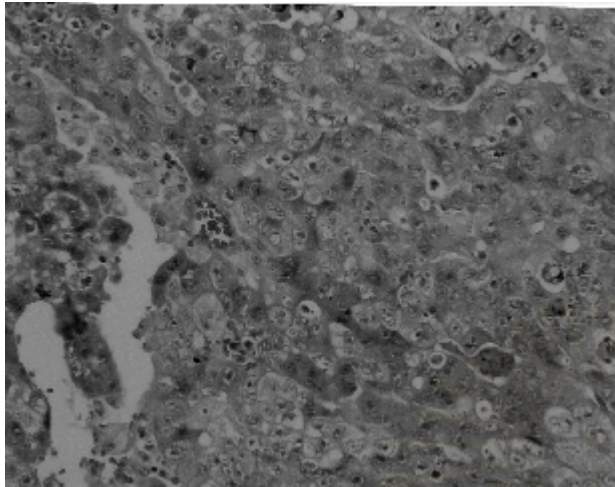
The age at presentation, the side of testicular involvement and the association with cryptorchidism of each tumor are summarized in Table 2.



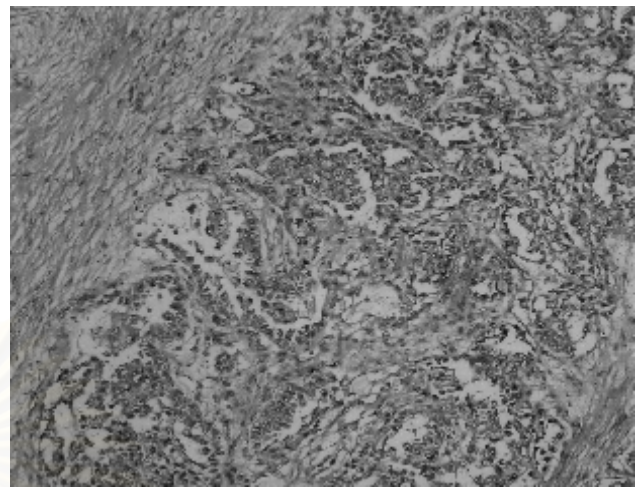
**Figure 1.** Classic seminoma showing sheet-like arrangement of cells with clear cytoplasm, well-defined cell membranes and nuclei with prominent nucleoli. Note fibrous septa containing lymphocytes.



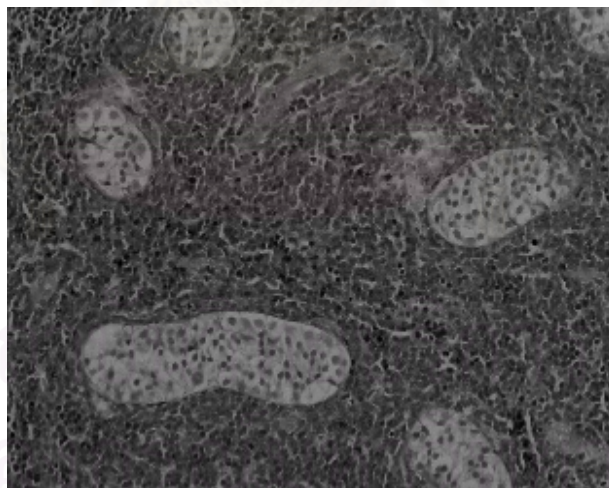
**Figure 2.** Diffuse large B cell lymphoma showing diffuse replacement of the testis by large lymphoid cells.



**Figure 3.** Embryonal carcinoma showing solid growth pattern. Note crowded, pleomorphic and vesicular nuclei with prominent nucleoli and poorly defined borders of the tumor cells.



**Figure 4.** Yolk sac tumor showing microcystic and endodermal sinus patterns.



**Figure 5.** Leukemic infiltration showing interstitial growth pattern. Note preserved seminiferous tubules.

**Table2.** The age at presentation, side of testicular involvement and association with cryptorchidism of each testicular tumor.

Tumor type	Age	Testicular side	History of cryptorchidism
1. seminoma	24	left	-
2. seminoma	22	right	-
3. seminoma	43	right	Present
4. seminoma	24	right	Present
5. seminoma	36	bilateral (metachronous)	Present
6. seminoma	37	left	Present
7. seminoma	27	left	-
8. seminoma	31	bilateral (synchronous)	-
9. diffuse large B cell lymphoma	79	right	-
10. diffuse large B cell lymphoma	63	left	-
11. diffuse large B cell lymphoma	70	left	-
12. diffuse large B cell lymphoma	81	left	-
13. diffuse large B cell lymphoma	71	left	-
14. diffuse large B cell lymphoma	60	right	-
15. T cell lymphoblastic lymphoma	9	bilateral (synchronous)	-
16. Burkitt lymphoma	12	right	-
17. mixed germ cell tumor (embryonal carcinoma and seminoma)	29	left	-
18. mixed germ cell tumor (teratoma,embryonal carcinoma, yolk sac tumor and choriocarcinoma)	19	left	-
19. mixed germ cell tumor (teratoma, yolk sac and embryonal carcinoma)	28	left	Present
20. mixed germ cell tumor (seminoma and embryonal carcinoma)	35	right	-
21. acute lymphoblastic leukemia	5	left	-
22. acute lymphoblastic leukemia	7	bilateral (synchronous)	-
23. yolk sac tumor	1	left	-
24. embryonal carcinoma	20	right	Present
25. malignant mesothelioma	54	right	-
26. metastatic prostatic adenocarcinoma	72	right	-



## Discussion

There are 26 cases of testicular tumor found in the Department of Pathology, Faculty of Medicine, King Chulalongkorn Memorial Hospital, during the year 1999-2004. All cases, except one, are present with scrotal or testicular mass which is also the most common complaint of the patients in other studies.<sup>(7,12-14)</sup> Slight predominance of left-side testicular tumor, as opposed to right side reported by Gill MS et al. is observed.<sup>(7)</sup> Seminoma and lymphoma are the two most common types that constituted more than 60 % of all testicular tumors in this study. Others present in decreasing frequency are mixed germ cell tumors (15.38 %), leukemia (7.69 %), yolk sac tumor (3.85 %), embryonal carcinoma (3.85 %), metastatic prostatic adenocarcinoma (3.85 %) and malignant mesothelioma (3.85 %). A previous review of testicular tumors by Zhonghua Zhong Liu Za Zhi has shown seminoma in 49.1 %, yolk sac tumor in 17.5 %, teratoma in 14.9 %, embryonal carcinoma in 8.8 %, mixed carcinoma in 8.8 % and choriocarcinoma in 0.9 %.<sup>(15)</sup> Gill MS et al. found seminoma (36.5 %) as the most common followed by mixed germ cell tumor (28.82 %).<sup>(7)</sup> Parallel to other studies, seminoma is the most common types of testicular tumor, making up 30 % to 40 % of the testicular tumors.<sup>(3,6-8)</sup> However, a mean age at presentation of the tumor is about 10 years younger than other data (30 years versus to 40 years).<sup>(3,8)</sup> Microscopically, seminoma is divided into two major categories: classic and spermatocytic, the latter comprises only 1.2 to 7 % of all seminoma and has not been found in this study. All cases are classic seminomas that show typical histologic features composed of a diffuse, sheetlike pattern or

a confluent multinodular pattern. Branching fibrous septa often course through the seminomas. The individual tumor cells are uniform with abundant clear to lightly eosinophilic cytoplasm, sharply outlined cell membranes, a large centrally located nucleus and one or two large central nucleoli. Lymphocytic infiltrates occur in virtually all the seminomas, intensely in and around the fibrous trabeculae. Granulomatous reaction with Langhans giant cells and syncytiotrophoblastic cells that can develop in some cases have been also absent. Lymphomas have occurred much more frequently in this study compared with other series (5 % versus 30 % of testicular tumors).<sup>(5,8,11)</sup> For testicular lymphoma, the great majority is usually of B- cell immunophenotype. Diffuse large B-cell lymphoma is the most common type occurring in elderly persons over 60 years of age in this study. These findings correspond with other literature.<sup>(3,5,8)</sup> Burkitt lymphoma and lymphoblastic lymphoma are common testicular lymphoma occurring in children and each has been found once in this study.<sup>(8)</sup> Other testicular lymphomas include small lymphocytic lymphoma, anaplastic large cell lymphoma, nasal type T/natural killer cell lymphoma, low grade T-helper cell lymphoma, intravascular (angiotropic) lymphoma and follicular center cell lymphoma. Microscopically, it is well documented that an interstitial pattern with relative tubular preservation is an important clue to the diagnosis. However, this feature has been found in only two cases in this study.

Embryonal carcinoma in pure form accounts for only 2.3 % to 10 % of testicular germ cell tumors but presents as a component of nonseminomatous germ cell tumors up to 87 %.<sup>(3,8)</sup> The tumor occurs between 25 to 35 years of age with the average age of

32 years. In this study, the pure form has occurred in the younger patients (20 years) and all 4 cases of mixed germ cell tumor (100 %) have had an embryonal carcinoma component. Microscopically, it may be composed entirely of solid sheets of undifferentiated cells or show signs of early differentiation in the form of papillary or glandular formations. The tumor cells are reactive for keratin and CD 30 but usually not for CD117.<sup>(3,8)</sup>

Yolk sac tumor is the most common testicular tumor of children, representing 82 % of all prepubertal germ cell tumors.<sup>(3)</sup> About half to three fourths of children cases involve patients under 2 years of age. It is almost always a pure neoplasm in prepubertal child, whereas it is also a component of a mixed germ cell tumor in postpubertal patients. In Talerman's study, there was a 44 % frequency of a yolk sac tumor component in prospectively examined nonseminomatous germ cell tumors.<sup>(16)</sup> These data are also supported by this study comprising one case of pure yolk sac tumor occurred in patient at the age of 1 year, and two out of four mixed germ cell tumors (50 %) with yolk sac tumor component, all have occurred in postpubertal patients. Microscopically, the tumor has been classified into 11 patterns: endodermal sinus, reticular, macrocystic, papillary, solid, glandular-alveolar, myxomatous, sarcomatoid, polyvesicular vitelline, hepatoid and parietal.

Pure choriocarcinomas are rare representing only 0.3 % of testicular tumors. However, a component of choriocarcinoma is identified in 8 % to 16 % of mixed germ cell tumors on careful examination.<sup>(3,8)</sup> Only one out of 4 mixed germ cell tumor (25 %) has had this tumor component and pure form has been absent in this study, corresponding to previous data.

Teratomas account for about 7 % of testicular germ cell tumors, occurring in two distinct age groups. Like yolk sac tumor, they are usually pure neoplasm in prepubertal patient, representing about 15 % of testicular germ cell tumor. In adult patient, they occur over 50 % as one component of mixed germ cell tumors.<sup>(8)</sup> Accordingly, half cases of mixed germ cell tumors in this study have had this tumor element, however pure form have been absent.

Leukemic involvement of the testis occurs 40 % to 65 % of patient with acute leukemia and 20 % to 30 % of patient with chronic leukemia at the autopsy.<sup>(8)</sup> Children with acute lymphoblastic leukemia are especially prone to have the testicular involvement. Microscopically, the pattern of leukemic infiltration is similar to that of lymphoma, predominantly intertubular/interstitial growth. Both cases of leukemic involvement in this study were acute lymphoblastic leukemia with this typical growth pattern as well.

Malignant mesothelioma of the testis arising from the tunica vaginalis is a very rare tumor with aggressive biological behavior.<sup>(17-19)</sup> The frequency of this tumor is 0.3 % of all mesothelioma cases, reported in Japan by Murai Y.<sup>(20)</sup> Typically, it is the tumor of middle-aged to elderly men with the mean age of 53.5 years. A strong relationship with occupational exposure to asbestos and long lasting hydrocele are well documented.<sup>(17,21)</sup> Histologic findings show that approximately 75 % of the tumors are epithelial and 25 % biphasic.<sup>(19)</sup> The epithelial tumor is typically papillary or tubulopapillary. Areas of spindle cells are noted in biphasic tumor. The tumor cells are stained positively with cytokeratin, EMA and calretinin. In this study, there has been one case of malignant mesothelioma with biphasic pattern occurring in

54 year-old patient. The tumor without association of asbestos exposure and long lasting hydrocele as in this case has also been reported.<sup>(17)</sup>

Metastatic tumors of the testis are very rare, representing less than 3 % of all testicular tumors. Most often occur in men over 50 years of age. Haupt HM et al. reported the metastatic tumors with decreasing frequency including prostate and lung cancer, malignant melanoma, carcinomas of the colon and kidney. The first two account for one half of the cases.<sup>(24)</sup> Metastatic prostate cancer has been found in 6 % of therapeutic orchidectomy specimens and has found in one case in this study.<sup>(25)</sup> Other metastatic tumors are cancer of pancreas, stomach, colon, appendix and liver.<sup>(23,26-30)</sup> Metastatic neuroblastoma and rhabdomyosarcoma have also been mentioned in children.<sup>(31-32)</sup>

Bilateral testicular involvement is usually observed in leukemia, lymphoma and metastatic tumor. The last two occur in about 20 % and 12 % to 18 % of the cases, respectively.<sup>(3,33,30)</sup> In bilateral germ cell tumors, 69 - 83 % and 17-31 % were metachronous and synchronous tumors, respectively.<sup>(34-35)</sup> Seminoma was the most common histology in these groups.<sup>(34)</sup> The median interval between metachronous tumor is about 4 years. Overall, bilateralism is found in 2 % of typical seminomas.<sup>(6)</sup> Accordingly, the tumors which show bilateral testicular involvement included 2 cases of seminoma, 1 case of lymphoma and 1 case of leukemia in this study.

Men with cryptorchidism are well known to be susceptible to germ cell neoplasms. Swerdlow and Prener A et al indicate a risk of 5.2 to 7.5 % for the development of testicular germ cell malignancy

relative to that of the population of male with descended testes.<sup>(36-37)</sup> Of germ cell tumors, only spermatocytic seminoma has not been reported occurring in undescended testis.<sup>(38)</sup> Seminoma is the most common type of germ cell tumor associated with cryptorchidism, constituting more than 50 % of the cases.<sup>(39)</sup> Correspondingly, there are 4 cases of seminoma, one case of embryonal carcinoma and one case of mixed germ cell tumor that has occurred in the patients with cryptorchidism in this study.

### Conclusion

Seminoma is the most common tumor in this study parallel to prior data. Higher prevalence of malignant lymphoma equally to seminoma has been observed. Other tumors present in decreasing frequency are mixed germ cell tumors, leukemia, yolk sac tumor, embryonal carcinoma, metastatic prostatic adenocarcinoma and malignant mesothelioma. Nearly all of other findings correspond with other literature.

### References

1. Bosl GJ, Motzer RJ. Testicular germ cell cancer. *N Engl J Med* 1997 Jul;337(4):242-53
2. Oliver RT. Testis cancer: review. *Curr Opin Oncol* 1997 May; 9(3): 287 - 94
3. Ulbright TM, Amin MB, Young RH. Tumors of the testis, adnexa, spermatic cord, and scrotum. In: Rosai J, Sobin LH, eds. *Atlas of Tumor Pathology*. 3<sup>rd</sup> Series, Fascicle 25. Washington DC: Armed Forces Institute of Pathology, 1999: 27 - 285
4. Nori F, Settini L, Figa-Talamanca I. Testicular tumors in Italy: historical trends, geographic difference and etiological hypotheses. *Epidemiol Prev*

- 2002 Mar-Apr; 26(2): 76 - 81
5. Rosai J. Rosai and Ackerman's Surgical Pathology. 9<sup>th</sup> ed. St. Louis: C.V.Mosby, 2004: 1361-444
  6. Huyghe E, Matsuda T, Thonneau P. Increasing incidence of testicular cancer worldwide: a review. *J Urol* 2003 Jul; 70(1):5 - 11
  7. Gill MS, Shah SH, Soomro IN, Kayani N, Hasan SH. Morphological pattern of testicular tumors. *J Pak Med Assoc* 2000 Apr; 50(4):110 - 3
  8. Ulbright TM. Testicular and paratesticular tumors. In: Mills SE, Carter D, Greenson JK, Oberman HA, Reuter V, Stoler MH, eds. *Sternberg's Diagnostic Surgical Pathology*. 4<sup>th</sup> ed. Philadelphia: Lippincott Williams & Wilkins, 2004: 2167 - 217
  9. Ulbright TM. Germ cell neoplasm of the testis. *Am J Surg Pathol* 1993 Nov;17(11): 1075 - 91
  10. Raina V, Shukla NK, Gupta NP, Deo S, Rath GK. Germ cell tumours in uncorrected cryptorchid testis at Institute Rotary Cancer Hospital, New Delhi. *Br J Cancer* 1995 Feb;71(2): 380 - 2
  11. Aviles-Salas A, Turbiner-Miasnikova J, Labardini-Mendez JR, Sobrevilla-Calvo Pde J. Primary testicular lymphomas. Clinicopathologic analysis of 10 cases. Experience at the National Institute of Cancerology in Mexico City. *Gac Med Mex* 2004 Mar-Apr;140(2): 123 - 8
  12. Yang JL, Shi YK, He XH Zhou AP, Liu P, Ai B, Zhang CG. Clinical and pathological features of 23 patients with primary lymphoma of the testis. *Zhonghua Zhong Liu Za Zhi* 2003 Sep; 25(5): 498 - 500
  13. Metcalfe PD, Farivar-Mohseni H, Farhat W, McLorie G, Khoury A, Bagli DJ. Pediatric testicular tumors: contemporary incidence and efficacy of testicular preserving surgery. *J Urol* 2003 Dec;170(6 Pt 1); 2412 - 5
  14. Buse S, Lurati G, Schmid HP. Testicular tumors: a current review. *Schweiz Rundsch Med Prax* 2003 Nov 19;92(47):1989-97
  15. Chen SF. Germ cell tumor of the testis: clinicopathologic analysis of 114 cases. *Zhonghua Zhong Liu Za Zhi* 1985 Jul; 7(4): 277 - 9
  16. Talerman A. Endodermal sinus tumor elements in testicular germ cell tumors in adults: comparison of prospective and retrospective studies. *Cancer* 1980 Sep; 46(5):1213 - 7
  17. Garcia de Jalon A, Gil P, Azua-Romeo J, Borque A, Sancho C, Rioja LA. Malignant mesothelioma of the tunica vaginalis: report of a case without risk factors and review of literature. *Int Urol Nephrol* 2003; 35(1): 59 - 62
  18. Harmse JL, Evans AT, Windsor PM. Malignant mesothelioma of the tunica vaginalis: a case with unusually indolent course following radical orchidectomy and radiotherapy. *Br J Radiol* 1999 May; 72(857): 502 - 4
  19. Jones MA, Young RH, Scully RE. Malignant mesothelioma of the tunica vaginalis. A clinicopathologic analysis of 11 cases with review of the literature. *Am J Surg Pathol* 1995 Jul; 19(7): 815 - 25
  20. Murai Y. Malignant mesothelioma in Japan: analysis of registered autopsy cases. *Arch Environ Health* 2001 Jan-Feb; 56(1): 84 - 8
  21. Kasdon EJ. Malignant mesothelioma of the tunica vaginalis propria testis. Report of two cases. *Cancer* 1969 May; 23(5): 1144 - 50
  22. Rosser CJ, Gerrard E. Metastatic small cell carcinoma to the testis. *South Med J* 2000 Jan; 93(1): 72 - 3
  23. Haupt HM, Mann RB, Trump DL, Abeloff MD.



- Metastatic carcinoma involving the testis. Clinical and pathologic distinction from primary testicular neoplasm. *Cancer* 1984 Aug; 54(4): 709 - 14
24. Rosales Bordes A, Montlleo Gonzalez M, Villavicencio Mavrich H, Algaba Arrea F. Metastatic testicular carcinoma. *Arch Esp Urol* 2000 Jul-Aug; 53(6): 469 - 71
25. Johansson JE, Lannes P. Metastases to the spermatic cord, epididymis and testicles from carcinoma of the prostate-five cases. *Scand J Urol Nephrol* 1983;17(2): 249 - 51
26. Young RH, Talerma A. Testicular tumors other than germ cell tumors: review. *Semin Diagn Pathol* 1987 Nov; 4(4): 342 - 60
27. Richardson PG, Millward MJ, Shrimankar JJ, Cantwell BM. Metastatic melanoma to the testis simulating primary seminoma. *Br J Urol* 1992 Jun; 69(6): 663 - 5
28. Datta MW, Ulbright TM, Young RH. Renal cell carcinoma metastatic to the testis and its adnexa: a report of five cases including three that accounted for the initial clinical presentation. *Int J Surg Pathol* 2001 Jan; 9(1): 49 - 56
29. Datta MW, Young RH. Malignant melanoma metastatic to the testis: a report of three cases with clinically significant manifestations. *Int J Surg Pathol* 2000 Jan; 8(1): 49 - 57
30. Garcia-Gonzalez R, Pinto J, Val-Bernal JF. Testicular metastases from solid tumors: an autopsy study. *Ann Diagn Pathol* 2000 Apr; 4(2): 59 - 64
31. Backhaus BO, Kaefer M, Engum SA, Davis MM. Contralateral testicular metastasis in paratesticular rhabdomyosarcoma. *J Urol* 2000 Nov; 164(5): 1709 - 10
32. Kumari PK, Surendran N, Chellam VG, Pillai GR, Rama CK. Neuroblastoma with testicular metastasis: review of literature and report of a case. *Int J Cancer* 1994 Mar; 31(1): 52 - 5
33. Doll DC, Weiss RB. Malignant lymphoma of the testis: review. *Am J Med* 1986 Sep;81(3): 515 - 24
34. Holzbeierlein JM, Sogani PC, Sheinfeld J. Histology and clinical outcomes in patients with bilateral testicular germ cell tumors: the Memorial Sloan Kettering Cancer Center experience 1950 to 2001. *J Urol* 2003 Jun; 169(6): 2122 - 5
35. Theodore Ch, Terrier-Lacombe MJ, Laplanche A, Benoit G, Fizazi K, Stamera O, Wibault P. Bilateral germ-cell tumours: 22-year experience at the Institut Gustave Roussy. *Br J Cancer* 2004 Jan 12; 90(1): 55 - 9
36. Swerdlow AJ, Higgins CD, Pike MC. Risk of testicular cancer in cohort of boys with cryptorchidism. *BMJ* 1997 May; 314(7093): 1507 - 11
37. Prener A, Engholm G, Jensen OM. Genital anomalies and risk for testicular cancer in Danish men. *Epidemiology* 1996 Jan; 7(1): 14 - 19
38. Levin HS. Nonneoplastic diseases of the testis. In: Mills SE, Carter D, Greenson JK, Oberman HA, Reuter V, Stoler MH, eds. *Sternberg's Diagnostic Surgical Pathology*. 4<sup>th</sup> ed. Philadelphia: Lippincott Williams & Wilkins, 2004: 2133 - 61
39. Kulkarni JN, Kamat MR. Tumors in undescended testis. *J Surg Oncol* 1991 Apr; 46(4): 257 - 60