

Current surgical treatment of idiopathic scoliosis

Wicharn Yingsakmongkol*

Robert W.Gaines**

Yingsakmongkol W, Gaines RW. Current surgical treatment of idiopathic scoliosis. Chula Med J 2002 Feb; 46(2): 163 - 79

Idiopathic Scoliosis is the most common spinal deformity occurring in normal healthy patients. Outcome of the treatment is favorable when early diagnosis and appropriate timing and methods of treatment are made.

This article describes the details of idiopathic scoliosis in terms of diagnosis, natural history patient evaluation, assessment and treatment. Update in the surgical treatment is emphasized.

Key words : Scoliosis, Surgery.

Reprint request : Yingsakmongkol W, Department of Orthopaedics, Faculty of Medicine, Chulalongkorn University, Bangkok 10330, Thailand.

Received for publication. November 15, 2001.

Objective

To provide comprehensive knowledge on idiopathic scoliosis for anyone who deals with the patients suffering from this disease.

* Department of Orthopaedics, Faculty of Medicine, Chulalongkorn University

** Columbia Orthopaedic Group; Columbia Spine Center, and Department of Orthopaedic Surgery, University of Missouri-Columbia, USA

วิชาญ ยี่งศักดิ์มงคล, Robert W.Gaines. การรักษาโรคกระดูกสันหลังคดชนิดที่ไม่ทราบสาเหตุ (Idiopathic scoliosis) โดยวิธีการผ่าตัดในยุคนปัจจุบัน. จุฬาลงกรณ์เวชสาร 2545 ก.พ; 46(2): 163 - 79

โรคกระดูกสันหลังคดชนิดที่ไม่ทราบสาเหตุ เป็นภาวะที่ผิดปกติของกระดูกสันหลังที่พบได้บ่อยที่สุดในจำนวนภาวะกระดูกสันหลังผิดรูปที่พบในกลุ่มวัยรุ่นที่มีสุขภาพร่างกายแข็งแรงและมีความสำคัญเนื่องจากผลของการรักษาโรคชนิดนี้ในระยะเบื้องต้น ขณะโรคยังไม่รุนแรงได้ผลดีมาก จนทำให้ผู้ป่วยที่ได้รับการรักษาสามารถกลับมาทำงานได้ใกล้เคียงหรือเป็นปกติ รวมทั้งอัตราการเจ็บป่วยและอัตราการตายจากโรคไม่แตกต่างจากคนปกติทั่วไป แต่หากวินิจฉัยไม่ได้หรือได้แต่ช้าเกินไป จะส่งต่อผลการรักษาเป็นอย่างมาก

สถาบันวิทยบริการ
จุฬาลงกรณ์มหาวิทยาลัย

The most common form of spinal deformity is idiopathic scoliosis, a spinal curvature in the coronal plane occurring in normal healthy patients. No known etiology exists except a familial predisposition. There is no evidence of an underlying neurologic or muscular disorder and there are no congenital vertebral anomalies. The Scoliosis Research Society classifies idiopathic scoliosis based on the age when the curvature develops. There are three categories:

1. Infantile idiopathic scoliosis- presents from birth to 3 years of age (2-3 % of patients)
2. Juvenile idiopathic scoliosis- presents between 4 and 10 years of age (10 -15 %)
3. Adolescent idiopathic scoliosis- presents after 10 years of age. (the most common type-85 %)

The indications for surgical treatment of idiopathic scoliosis are based on the patient's curve magnitude and its progression, skeletal maturity, balance in the coronal and sagittal planes, and, sometimes the psychological impact of the spinal curvature and rib deformities, and the knowledge of the natural history of scoliosis. There are four important questions: (1) What are the possible health consequences of untreated scoliosis? (2) How does scoliosis develop? (3) Which curve is going to progress? (4) What is the place for brace and operative treatment for scoliosis?

Natural History

Numerous studies have shown that curves less than 30° cause few problems for adult patients.⁽¹⁻⁸⁾ Adult patients with curves under 30° are mainly pain free, their pulmonary functions are within normal limits and they have minimal if any cosmetic and/or psychological disfiguring.

Infantile Idiopathic Scoliosis: Fifty five to sixty per cent of scoliosis occurs in boys and almost 90 % are left thoracic curves that develop before the age of two years.⁽⁹⁻¹¹⁾ They are associated with plagiocephaly. Infantile idiopathic scoliosis is divided into a resolving and progressive type. Almost 90 % of these curves spontaneously correct or stabilize. If not treated, progressive type curves show relentless progression up to 70° or more by the age of 10 years.^(9,11,12)

Juvenile Idiopathic Scoliosis: These curves predominate in boys in the age group under 6, and in girls after 6 years of age. Curve patterns vary with age. The left thoracic curve pattern is more common in younger children, while double thoracic and right thoracic curves are equally seen in older children. Other causes for scoliosis must be considered in each case of juvenile scoliosis (tumors, congenital anomalies, etc). One third of the cases of juvenile idiopathic scoliosis are nonprogressive; the other two thirds progress at various rates. Curves first detected under the age 6 years and over 30° usually progress to over 60°- 70°. The earlier curves present, the higher the risk for progression.

Adolescent Idiopathic Scoliosis: These curves generally appear in late childhood (age 8 -10 years) then progress during the adolescent growth spurt. Curve progression has been proven to be related to curve pattern, curve magnitude, the age of the patient at presentation, skeletal maturity (Risser sign), and menarchal status according to Bunnell.⁽¹³⁾ Peak body height velocity has recently been shown by Little DG et al, to be a very sensitive predictor as well.⁽¹⁴⁾

Thoracic curves have the highest risk of progression (77 %), followed by thoracolumbar curves (67 %), double thoracic curves (66 %) and lumbar

curves (30 %).⁽¹³⁾

The patient's age is an important factor in predicting curve progression; if a curve is diagnosed before 10 years of age, the risk of progression of 5° or more is 88 %, if diagnosed between 12 and 15 years 56 %; and 29 % if diagnosed after age 15.⁽¹³⁾

The magnitude of the curve at the time of diagnosis is another important factor influencing the curve progression. Most studies showed that curves less than 30° at maturity tend not to progress during adult life regardless of the curve pattern.^(3,6,15) Of the total 123 skeletally immature patients who were followed up until skeletal maturity in Bunnell's study, the average age at the time of the first visit was 13.6 years (range 10.5 -15.6 years) and the average curvature at the time of diagnosis was 33°(10°- 49°). Follow-up showed that 70 % of curves less than 20° at the time of diagnosis progressed more than 5° and 44 % of these more than 10°. Curvatures of 20°- 30° progressed more than 5° in 52 % of patients and more than 10° in 30 %. Curvatures of 30°- 40° progressed more than 5° in 67 % and 10° or more in 48 %. Curvatures of 40° - 50° at the time of diagnosis progressed more than 5°, and 62 % of these progressed more than 10°.

Skeletal maturity is one of the important factors affecting curve progression. Although questioned by some, the Risser sign is still the most reliable and the easiest parameter to follow and document (already seen on the long PA radiographs of the spine). According to Bunnell, patients who were Risser 0 at the time of diagnosis had a 68 % risk of curve progression of 10° or more. This risk was decreased to 52 % in those whose Risser sign was 1 or 2, and to 18 % for those whose Risser sign was 3

or 4. The risk of curve progression is higher if the scoliosis develops before menarche. Fifty three percent of the patients whose curves developed before menarche progressed 10° or more, while only 11 % of those which were diagnosed after menarche.

Gender seems to influence the natural history of scoliosis in growing children. With respect to gender, several studies indicated that the curve progression secondary to growth usually stops at Risser 4 in females and at Risser 5 in males with idiopathic scoliosis.^(13,15,16) While this is true, the other factors which influence curve progression such as curve magnitude, sagittal plane alignment and the tilt angle (for TL-curve) are more important for patient management.

Little DG, et al⁽¹⁴⁾ found the peak height velocity (generated from standing-height measurements within a minimum six-month interval) to be more accurate than the other maturity indicators (chronological age, menarchal status and Risser sign) in prediction of progression of scoliosis in girls. Results of the study showed that most of the curves progressed maximally at the patient's peak height velocity. Of the total 120 patients whose curves were between 25° and 45° and were treated by bracing, 90 % of them ceased growing by 3.6 years after the peak height velocity. Curvatures progressed for 68 % of the patients whose curves were 30° or more at the peak height velocity. Most of these curves (83 % of the patients) progressed to 45° or more while only 4 % of those whose curves were 30 degrees or less at the peak height velocity progressed.

Adult Scoliosis: Adult scoliosis is either an adolescent idiopathic curve found after skeletal maturity or a de novo curve (one that develops after age 45). Studies on the prognosis in patients with

idiopathic scoliosis, up to 50 years follow up, showed a two fold increase in the mortality rate. Sixty percent of the deaths were due to cardiopulmonary disease.⁽⁵⁾ Mortality appeared to be highest after the age of 45 years. The life style of patients with scoliosis also changes: many women with obvious scoliotic deformity stay single.⁽⁵⁾

A forty year follow-up study of 102 patients with idiopathic scoliosis show that, regardless of curve pattern, curves less than 30 degrees at patient's maturity tend not to progress, while 68 % of those over 30 degrees do progress.⁽⁷⁾ Lumbar curves in which the fifth lumbar vertebra was not well seated and the apical rotation was greater than 33 % commonly progress in adult life. There was significant curve progression and translational shift of the vertebrae at the lower end of the curve. The highest risk of progression was found in patients with thoracic curves between 50° and 75° at skeletal maturity. No statistically significant difference in the incidence of back pain was found in 219 patients with idiopathic scoliosis versus a control group of 100 age and sex-matched individuals without spinal deformity followed up over an average period of 39 years.⁽⁸⁾ However, at 51 years follow-up, the scoliosis patients had a significantly larger percentage of chronic middle and low back pain and current back pain of greater intensity and duration than the control group (33 % versus 15 %; $p = 0.01$).⁽¹⁷⁾

Reduction of vital capacity is directly related to the severity of thoracic curves.⁽⁸⁾ Thoracic curves over 80° resulted in loss of vital capacity up to 75 % of the predicted normal values. Patients with double thoracic and lumbar curves had fewer pulmonary symptoms than those with single thoracic curves.⁽⁸⁾

Weinstein recently reported a more-than-50 year review of untreated scoliosis patients. At 50 years follow-up, the patients curve magnitude averaged 85° for the single thoracic curves, 90° for the thoracolumbar curves, 49° for the single lumbar curves and 77° for the double major curves. Forty-three percent were single thoracic curves, 14 % were thoracolumbar, 28 % were single lumbar curves and 15 % were double major curve. This report made it clear that idiopathic scoliosis does progress after skeletal maturity and that the progression risk is primarily related to the curve magnitude at the end of skeletal growth. The incidence of degenerative disease of the spine increased dramatically over the study period, from only 2 % at maturity, to 75 % after an average 51 years follow-up. However, no evidence of a relationship between back pain and osteoarthritis could be established. No significant difference between a control and the study group regarding functioning and presence of back pain were found. Although more scoliosis patients reported more chronic back pain and current back pain of greater intensity and duration than controls, their ability to work and perform daily activities was similar to their unaffected peers. Back pain had the same impact on work and activities for scoliosis patients as it did for the control patients. Despite back pain, this group of untreated patients continued to be productive and functioned at a high level.⁽¹⁷⁾ There were no significant difference in marital status or number of children between the scoliosis patients and the control group.

Patient assessment

The best test to assess developing scoliosis is the Adam's forward bending test. The earliest clinical

sign of a developing scoliosis is a rotational prominence ("rib hump") with or without accompanying loss of thoracic kyphosis. This prominence can be quantified using a scoliometer (a difference of 5° - 7° more triggers a referral for medical evaluation). Asymmetry in the shoulder level, neckline or waistline can be noticed too. Some cases the "rib hump" can be accompanied by compensatory "lumbar hump". In neglected cases a particularly large and angular rib hump, called a "razorback", can develop. Clinically, the spinal balance in the coronal plane is evaluated by dropping a plumb line from the occiput

and measuring the distance between the gluteal cleft and the midline.

It is necessary to perform a complete neurologic examination (especially abdominal reflexes) and look for any associated conditions such as Marfan's syndrome, syringomyelia, or neurofibromatosis.

Curve flexibility is evaluated by side bending in the standing and prone position. Sagittal plane alignment is assessed while the patient is standing. Spinal flexibility in the sagittal plane is clinically assessed also.

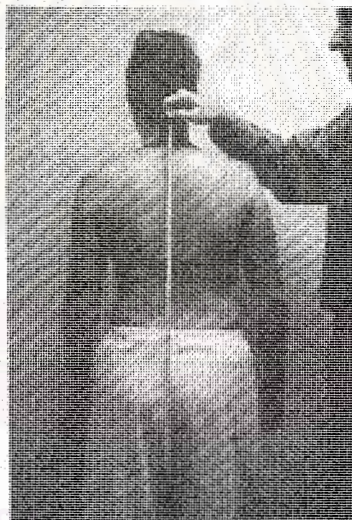


Figure 1. Clinical measurement of balance in the coronal plane.




Figure 2. Clinical examination of curve flexibility in standing position.




Figure 3. Clinical examination of curve flexibility in prone position.

Radiographic Evaluation

Evaluation of the Erect Spine

Standing PA and lateral radiographs are taken on a 36-inch (90 cm) long cassette from 72 inches (180 cm) distances from the x-ray tube. Antero-posterior exposures must be avoided since they increase the risk of radiation and may induce breast cancer.^(18,19) A three-to sevenfold reduction in cumulative radiation doses to the thyroid gland and the female breast occurs when the AP radiograph was replaced by the PA view radiograph. This yields a three- to fourfold reduction in the lifetime risk of breast cancer and a halving of the lifetime risk of thyroid cancer.⁽²⁰⁾ There is also an indication that number of radiographs can influence development of breast cancer in females.^(18,20) The incidence of breast cancer was 1.69 times higher in comparison with the general population if up to 20 radiographs were taken during the adolescent years.⁽¹⁸⁾ The location of the end and apical vertebrae, the magnitude of the curve as measured by the Cobb method and pattern of the curves, and the tilt angle of the most inferior end vertebra (The

angle formed by the line parallel to the endplate of lower end vertebrae and the intercrystal line) are determined in the coronal and sagittal planes. In the coronal plane, a plumb line dropped from the center of C₇ should bisect the sacrum. In the sagittal plane, a plumb line dropped from the center of C₇ should intersect the posterior aspect of the sacrum or fall behind it.⁽²¹⁾

Spine Flexibility Assessment

Radiographic evaluation of curve flexibility must be done since it helps predict the ability of a spinal curvature to be straightened, particularly from the posterior approach. This can be assessed by either lateral bending, stretching (traction) or fulcrum bending.^(22,23) Lateral bending radiographs are taken with a patient in the supine position. We find stretch or traction radiographs the most useful. For these radiographs, a patient is lying supine on the X-ray table. The examiner gently supports a patient's head and neck or shoulders, while an assistant pulls distally on both legs.

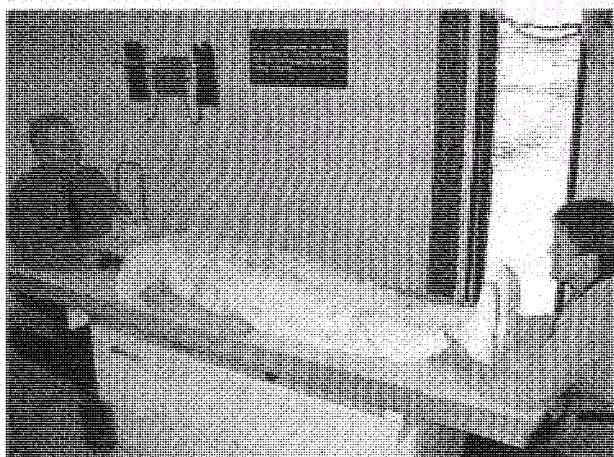


Figure 4. Traction or stretching procedure for radiographic evaluation the curve flexibility.

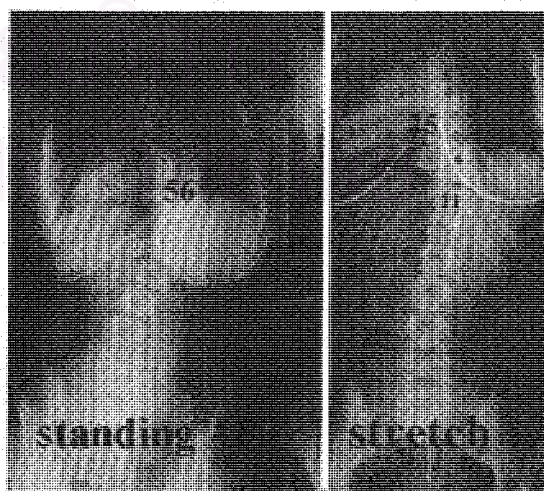


Figure 5. Radiographic demonstration of stretch view compare with AP- standing view.

It is important to explain the procedure to the patient before the exam so he/she can relax and allow maximal traction to be applied. The exam should be stopped if the patient would feel uncomfortable or neurological signs encountered. Preoperative traction or bending radiographs provide an estimation of curve correction from a posterior approach.

Magnetic Resonance Imaging Evaluation

Several studies have shown neural axis abnormalities on MRI in scoliosis patients with no neurologic complaints or abnormality on physical examination.⁽²⁴⁻³⁰⁾ The most common abnormalities found were syringomyelia and Arnold-Chiari malformation. The highest incidence was found in children less than 11 years of age.^(25,26,28,30)

A retrospective study of MRI of patients with idiopathic scoliosis found intraspinal abnormalities in 14.7 % - 15.4 % of the patients between one and twenty-eight years.⁽²⁸⁾ Neural axis abnormalities were found by MRI in 47 % of infantile and juvenile scoliosis patients, and in 15.4 % of the adolescent scoliosis.⁽³⁰⁾ In patients under 4 years of age the prevalence of neural axis abnormalities was around 50 %, ^(25,26,30) while in patients under age 11 years it ranged from 20% ^(25,26) to 26 %.⁽²⁴⁾ This incidence was up to 40 %⁽²⁶⁾ and 62.5 %⁽²⁸⁾ when the patient's age was less than 11 years old and he or she had a left thoracic curve.

In prospective preoperative MRI studies of patients with adolescent idiopathic scoliosis who underwent surgery for their scoliosis, the prevalence of spinal or spinal canal abnormality ranged from 2.8 %⁽²⁹⁾ to 4.4 %⁽²⁷⁾ Neither of these studies was able to identify any clinical features which could reliably discriminate the patients with or without abnormalities

on MRI.

We agree with suggestions of many authors^(25,26) for a routine MRI of the whole spine in the patients with idiopathic scoliosis who are younger than 11 years old, due to the high incidence of intraspinal abnormalities found in these patients. Scoliosis patients with stiff curves on lateral bending with lower extremity atrophy or neurologic abnormality, or back pain requiring narcotic medication should also receive MRI evaluation, regardless of their age.

Indications for Surgical Treatment

The goals of surgical correction and stabilization of a spinal curvature are to improve the patient's spinal balance, prevent curve progression and pain, and to correct the development of a potentially functionally and psychologically crippling deformity.

Based on our experience, surgery is needed for a patient with idiopathic scoliosis when the curve progresses beyond 45° by the Cobb angle, the tilt angle (the angle between the most tilted lumbar vertebral body and the horizontal line across the top of the pelvis if there is no pelvic obliquity) increases beyond 20°, or when spinal decompensation extends beyond 3 cm. Factors also influencing the decision are the age at the onset of the curvature, the curve progression over time, the size and rigidity of the curve, the age of the patient and the symptoms produced by the curve.

Infantile Idiopathic Scoliosis

As mentioned earlier, the majority of the curves in these patients are of the non-progressive resolving type. As long as those curves improve or remain mild, they can be observed. Thus, active

management is only indicated for the curves that progress. The initial management is always non-operative. Serial casting or bracing treatment are started as soon as curve progression is noticed in order to prevent further deterioration. Several types of braces can be used. A child is observed with occasional radiography of the whole spine for possible relapses until maturity. Surgical stabilization is considered in patients whose curves cannot be controlled with bracing. (> 40°)

Instrumentation without fusion is indicated for children less than 6 - 8 years of age. One of the options is performing end fusions that are later used as anchors for hooks to distract and correct a curved segment of the spine in-between.^(31,32) The spine is exposed only in the area of the end fusions and the rod is inserted under the muscle fascia or subcutaneously. The rod is lengthened every 6 months and replaced every 12 to 18 months. With this technique, additional spinal growth can be obtained and fusion delayed until most trunk growth is completed. The largest long term review of this technique showed a disappointing average growth of only 3 cm of the unfused spine segments over the mean treatment period of 3 years.⁽³¹⁾ In this study, only 10 of 73 patients were idiopathic scoliosis (9-congenital scoliosis, 31-neuromuscular scoliosis and 23-miscellaneous type). For all 67 patients, a total of 402 procedures (6.1 procedures per patient) were performed from initial instrumentation to definitive fusion.

Anterior and posterior hemiepiphyodesis can be performed in some patients who have larger and more rigid curves.

Juvenile Idiopathic Scoliosis

In general, in juvenile scoliosis, curves under

25° are observed. Curves present under age 6 years are treated similarly to those of the infantile type: serial casting, and bracing. Curves over 25° or curves with documented progression should be treated. Nonoperative treatment with the Milwaukee brace is the treatment of choice. If curves progress beyond 50°, surgery is indicated. Selection of fusion levels is generally the same as for adolescent idiopathic scoliosis. The crankshaft phenomenon (post-operative spinal deformity caused by continuous growth of the vertebral bodies under a solid posterior fusion mass) is a concern if posterior fusion is required for children below 9 or 10 years. In children who are Risser 0 and Tanner 1, who still have open triradiate cartilages of the acetabulae, an anterior growth arrest procedures at the apical vertebrae may be indicated before posterior instrumentation is performed to prevent crankshafting.^(33,34) The need for this may be avoided by using a large diameter posterior rod and getting full correction of the curve by posterior instrumentation.⁽³⁵⁾

Adolescent Idiopathic Scoliosis

The goals of surgical treatment for adolescent idiopathic scoliosis are: to correct the curve to the maximum degree that the spinal cord safely accommodates, to stabilize the deformity, and to re-balance the spine in both the coronal and sagittal planes. These goals should be achieved while instrumenting and fusing as few segments as possible. Generally, curves over 50° are treated surgically. Curves between 40° and 50° without progression are treated on individual basis. The existence of striking thoracic lordosis may suggest the need for operative treatment of progressive curves

slightly below 40° since thoracic curves with striking thoracic lordosis are notably resistant to bracing.

Adult Idiopathic Scoliosis

The indications for surgery in adult scoliosis usually include pain due to foraminal or spinal canal stenosis, and the progression of deformity with loss of body height and contour. Muscle fatigue is usually the first symptom created by a progressing adult curve. The discomfort is usually present on the convex side of the curve and is exacerbated with exertion. When complaints are located in the concavity of a curve, the origin of pain most likely is from foraminal narrowing by a disc or a facet joint. Osteophytes from narrow discs, facet hypertrophy and foraminal stenosis create nerve root symptoms from root compression. In degenerative scoliosis, osteophytes and infolded ligamentum flavum produce spinal canal stenosis, causing neurogenic claudication as well. The presence of a curve is not necessarily associated with the presence of symptoms. A source of pain outside the scoliotic curve must be excluded.

Principles of Operative Planning

Selecting fusion levels is relatively simple with a single-curve pattern. However, if a double-curve pattern is present, it is important to consider selective fusion, in which only the primary curve is instrumented and fused. If surgery is indicated, it is necessary to determine the fusion levels, the type of spinal instrumentation and the surgical approach. For moderate (40° to 70°) and flexible curves (more than 50 % correction on a stretch or bending radiograph), a single stage anterior or posterior spinal instrumentation and fusion can be performed.

The treatment of larger or stiffer curves may require staged reconstruction including anterior discectomy or corpectomy of one or more levels in the first, and posterior instrumentation and fusion in the second stage. Usually a single staged anterior instrumentation and fusion is not successful in double major curves.

Selection of Fusion Levels

Different principles for selection of fusion levels have developed over time. The type of instrumentation used definitely determines the stability of a construct and influences the selection of fusion levels, curve correction and retention of correction. The selection of appropriate fusion levels has changed with the development of newer, more versatile instrumentation systems. Harrington recommended instrumenting and fusing from one level above to two levels below the measured curve if the lower end vertebra was in the stable zone. Restoring spinal compensation following instrumentation requires balancing the fusion mass over the S₁ articular processes. Moe advocated fusing from the neutrally rotated vertebra above to the neutrally rotated vertebra below, using the technique described by Nash and Moe in assessing vertebral rotation.⁽³⁶⁾ He pioneered the concept of carefully studying curve flexibility by using side bending radiographs to define and consider fusion of only the structural curve, allowing the compensatory curve to correct itself spontaneously. This concept avoids long fusion. An experimental study showed that shorter fusions are less stressful on adjacent vertebral levels.⁽³⁷⁾

The ideal goals for scoliosis correction is to have the curved spine become straight, if possible,




Figure 6. Normal sagittal balance is measured by C7 (or Odontoid process) plumb line. This line should pass through the L5/S1 disc or behind.

with a balanced sagittal plane (Fig.6), with the tilt angle less than 10° , and fusion done in as few segments of spine as possible to maintain a flexible spine. The fusion should be done only in the diseased segments of the spine, which allows the flexible compensatory curves to correct spontaneously later on. After surgery, the patients should have no disabling back pain or implant related complications.

Sagittal plane imbalance (lumbar hypolordosis and thoracic hypokyphosis) must also be corrected over short segments. If the lumbar spine is fused in a position of relative kyphosis, the distal segments are forced into hyperextension to keep the patient in a sagittal plane balance. This position may be tolerated by adolescent patients but, as aging occurs, this "flatback deformity" can cause disc degeneration. As the discs degenerate, maintaining painless sagittal balance becomes increasingly difficult for a patient.

Historical Devices and Procedures

Posterior Spinal Instrumentation

Harrington Instrumentation: This system was developed in the 1950s by Dr. Paul Harrington of Houston, Texas.⁽³⁸⁾ It used to be the most widely used type of spinal instrumentation. Originally applied to spinal deformities resulting from poliomyelitis, since the 1960s it has been used for all spinal deformities. The basic Harrington instrumentation consists of a 1/8 inch (3.2 mm) stainless steel distraction rods, 1/8 inch (3.2 mm) flexible compression rod, and a wide array of numbered hooks. The instrumentation relies on distraction and/or compression forces to correct a deformity. Due to limited number of sublaminar hooks (at the ends of a rod only), the Harrington rods are not as securely fixed to the posterior elements as some other systems. Postoperative casting or bracing are needed to prevent hooks or rod displacement. The results of Harrington instrumentation and fusion in adolescent idiopathic scoliosis showed the pseudarthrosis rate was about 1% to 2% and reported curve correction varied from 40% to 50%. Rib hump correction varied, too. Although it can be still used for King type 3 curves, Harrington instrumentation is more of a historical value.

Luque Instrumentation: Developed in the 1970s by Dr. Eduardo Luque, the implants consist of smooth, 1/4-inch (6.4 mm) and 3/16-inch (4.8 mm) L-shaped rods and 16- or 18-gauge sublaminar wire loops. Two L-shaped rods are contoured to preserve thoracic kyphosis and lumbar lordosis and the sublaminar wires are tightened around the rods. This system is now rarely used for idiopathic scoliosis but is still commonly used for treatment of neuromuscular scoliosis. In a previously reported series using the

Luque technique, the radiographic correction was 45 % to 60 %, with little rotational correction.^(39,40) However, Luque's concepts of segmental fixation had a substantial influence on development of subsequent posterior instrumentation systems since it was the first which allowed true "segmental" correction and improved stability of the construct.

Development of the Drummond "buttons" (a series of small metal plates with an 18 gauge wire placed through them) allowed using this system when posterior vertebral elements (laminae) are missing (spina bifida, postlaminectomy conditions, etc).

Harrington Rod with Sublaminar Wires. This combination of implants increased the stability of the construct and allowed better curve correction. A modification of this system is the Wisconsin instrumentation (spinous process wiring) which has a square-ended Harrington distraction rod and a C-shaped 3/16-inch (4.8 mm) Luque rod. Reported radiographic correction was 39 % to 50 %, with only minimal rotation correction.⁽³⁸⁾

Multi-Segmental Hook/Pedicle Screw Rod Systems. Since 1984, the most common instrumentation in treatment of thoracolumbar scoliosis have been multisegmental hook and pedicle screw based systems for posterior spinal fusion. After Cotrel and Dubouset introduced the first such instrumentation,⁽⁴¹⁾ several other systems have been developed to reduce the profile and improve the strength of fixation (Texas Scottish Rite Hospital, Isola, and Moss-Miami systems, etc). The goal was a triplanar correction of scoliosis using multisegmental hooks or pedicle screws posteriorly. These implant systems allowed multiple points of attachment to the spine and therefore provided better correction in the sagittal and coronal

planes. Correction of rotational deformity occurred within a range which could be predicted preoperatively.

The limitations of posterior segmental rod-and-hook-screw systems are cost, profile and occasional iatrogenic spinal decompensation - a very serious complication. In addition, they always create long segment patterns of instrumentation.

Anterior Spinal Instrumentation

Currently, an anterior approach is fundamentally changing the way all scoliotic patients with a single curve will be surgically treated. Any single curve (thoracic, thoracolumbar or lumbar) can be instrumented and fused over about half the levels in the major curve, anticipating 75 %- 90 % coronal plane correction with restoration of physiologic sagittal plane balance.⁽⁴²⁻⁴⁷⁾

Dwyer Instrumentation. The titanium implants include staples placed laterally on the vertebral body, screws that stabilize the staples to the vertebral body (one screw for each vertebral body), and a flexible cable that passes through the screw heads to connect the vertebrae together. The Dwyer system provided limited stability based on the compressive effect of the tensioned cable. The flexible cable resisted only tension forces, and the flexible nature of the cable often led to cable or screw failure with subsequent pseudarthrosis. Although curve correction was better than with posterior implants (60 % - 80 % with 20 % of an associated rotational correction), several complications were reported including a high pseudarthrosis rate in the thoracic spine, and a "flat back" if an excessive straightened of the lumbar lordosis is made.^(42 - 43)

Zielke Instrumentation. The substitution of a cable by a semi-flexible threaded rod and nuts gave

not only better correction of scoliosis (60 % to 90 % improvement in scoliosis, and 40 % to 50% correction of the rotational deformity), but improved the stability and endurance of the instrumented area.⁽⁴⁸⁾ Possible complications were localized kyphosis over the instrumented segments resulting from the disc removal and spinal shortening, and rod breakage (8 % to 23 %), mainly in obese patients and also if a sharp bend in the rod is present post-operatively due to poor alignment. However, several authors^(49 - 51) reported that the kyphogenic nature of Zielke instrumentation was not always a problem. This instrumentation is rarely used now because of these problems.

Two dual-rod systems

Several posterior instrumentations have been used for single rod anterior spinal correction and instrumentation. Stability is improved by using a solid rod, in comparison with a cable or threaded rod. Single rod anterior constructs do not provide as much stability as do dual rod systems, especially in rotation and extension.⁽⁵²⁾ Two dual-rod systems were developed recently: the Kaneda Anterior Scoliosis System (KASS) in 1996, and the Halm-Zielke instrumentation (HZI) in 1997.

The Halm-Zielke instrumentation (HZI) is composed of a lid-plate, which is fixed at the lateral aspect of the vertebral body with two screws, a sunken screw anteriorly and a Ventral Derotation Spondylolysis (VDS) screw posteriorly. The longitudinal components consist of a threaded VDS rod and a solid, fluted rod. The solid rod allows internal derotation and relordosation. The fluted design of the rod provides rotational stability. The results in patients with

adolescent idiopathic scoliosis whose preoperative curves ranged from 36° to 77°, showed the correction of the frontal plane at an average of 77.5 % postoperatively, and 72.2 % at latest follow-up without implant-related complications.⁽⁴⁵⁾ All patients were without any additional external immobilization after surgery.

The Kaneda Anterior Scoliosis System (KASS). The KASS system has some key advantages over the others; better and triplanar correction of a curve, including better derotation. KASS consists of two 3/16 inch (4.8 mm) rods, lateral vertebral plates with tetra-spikes, and two vertebral screws for each vertebra. The clinical results of 25 thoracolumbar and lumbar scoliosis treated with KASS, with the average follow-up of 3 years, showed the average major curve correction of 83 %; apical vertebral rotation of 86 %, the tilt angle improved by 97 %, and improvement of the sagittal plane from 7° of thoracic kyphosis to 9° of lordosis⁽⁴⁶⁾ This excellent correction of the frontal and sagittal plane alignment was also reported for thoracic scoliosis⁽⁴⁷⁾ without significant loss of correction, implant failures or pseudarthrosis.

Forty-six patients with single curve idiopathic scoliosis have been treated by the senior author since 1996. The technique consists of an open anterior approach using rib head resection and total discectomy over the apical levels of the curve. Dual rod and screw instrumentation over the apical levels allowed full correction of any single curve over 3-6 vertebral levels (2-5 discs).

The average preoperative curve measured 53° (38° - 75°), and the average patient age was 14.5 years.^(9,12,21,24,25,31,38,46,47) Follow-up period has been up to 4 years in 46 cases. The primary curve correction averaged 75% and the sagittal plane alignment has

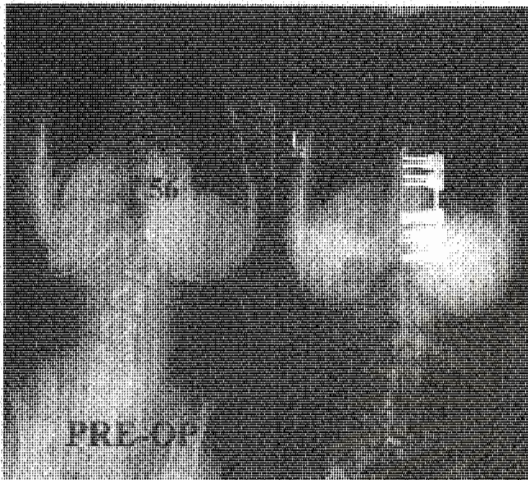

Figure 7. Radiographic demonstration of coronal plane correction by KASS device, an excellent curve correction was achieved with fewer segment fusion compare to posterior approach.

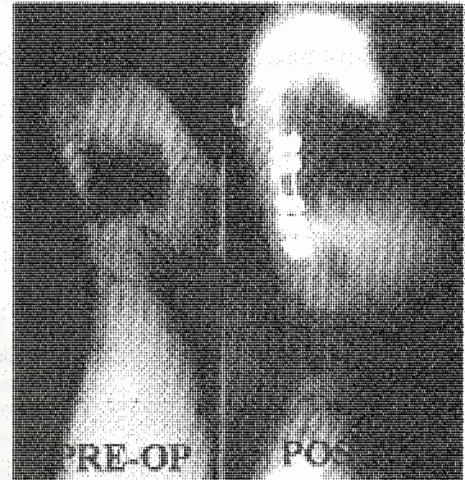


Figure 8. Radiographic demonstration of the sagittal plane alignment restoration in the same patient in Figure 7. The sagittal plane balance has been restored in addition to the coronal plane correction.

been restored toward normal in all cases. The Tilt angle has been corrected to less than 10° in all cases fused below L_3 . The average coronal decompensation was corrected from 20 mm preoperatively to 10 mm postoperatively. There have been no significant systemic or neurologic complications, broken implants or nonunion, and there has been no loss of correction. For most patients, the levels instrumented have included only half of the vertebral levels which would have been operated with a posterior technique.

In our experience, to achieve such correction, resection of the rib heads and all the intervertebral disc of the segments in the fusion area must be performed. In addition to the rib head resection on the convex side, complete resection of all of the annulus of the instrumented levels is the key to obtain most of the deformity correction.

Our correction, maintenance of correction and complication results are as good as Dr.Kaneda's

landmark results.⁽⁴⁴⁾ However, our cases are operated over several fewer levels. The KASS system and procedure produces excellent correction of the tilt angle and superior frontal and sagittal plane correction, instrumenting only about half of the fusion levels that would be instrumented from the posterior approach. This represents a significant advance in the surgical treatment of mild to moderately severe ($50^\circ - 90^\circ$) idiopathic scoliosis.

Idiopathic scoliosis is a common spinal deformity. The results of treatment depend on many factors (curve magnitude and its progression, skeletal maturity, balance in the coronal & sagittal plane). Although the exact etiology remains unknown, outcome of the treatment is favorable with careful evaluation, early diagnosis and propre management. The morbidity and mortality in the surgically treated patients are closely silimilar to the normal healthy population at their age.

References

1. Bjure J, Nachemson A. Non-treated scoliosis. Clin. Orthop 1973 Jun; 93: 44 - 52
2. Collis DK, Ponseti IV. Long-term follow-up of patients with idiopathic scoliosis not treated surgically. J Bone Joint Surg Am 1969 Apr; 51(3):425-45
3. Lonstein JE, Carlson JM. The prediction of curve progression in untreated idiopathic scoliosis during growth. J Bone Joint Surg Am 1984 Sep; 66(1):1061 - 71
4. Nachemson A. A long-term follow-up of non-treated scoliosis. Acta Orthop Scand 1968; 39(4): 446 - 76
5. Nilsson U, Lundgren KD. Long-term prognosis in idiopathic scoliosis. Acta Orthop Scand 1968; 39(4): 456 - 65
6. Rogala EJ, Drummon DS, Gurr J. Scoliosis. Incidence and natural history. A prospective epidemiological study. J Bone Joint Surg Am 1978 Mar; 60(2):173 - 6
7. Weinstein SL, Ponseti IV. Curve progression in idiopathic scoliosis. J Bone Joint Surg Am 1983 Apr; 65(4): 447 - 55
8. Weinstein SL, Zavala DC, Ponseti IV. Idiopathic scoliosis: long-term follow-up and prognosis in untreated patients. J Bone Joint Surg Am 1981 Jun; 63(5): 702 - 12
9. James JIP, Lloy-Roberts GC, Pilcher MF. Infantile structural scoliosis. J Bone Joint Surg Br 1959 Nov; 41(4): 719 - 35
10. Lloyd-Roberts GC, Pilcher MF. Structural idiopathic scoliosis in infancy; a study of the natural history of 100 patients. J Bone Joint Surg Br 1965 Aug; 47(3): 520 - 3
11. Scott JC, Morgan TH. The natural history and prognosis of the infantile idiopathic scoliosis. J Bone Joint Surg Br 1955 Aug; 37(3): 400 - 13
12. James JIP. Idiopathic scoliosis. The prognosis, diagnosis, and operative indications related to curve patterns and the age of onset. J Bone Joint Surg Br 1954 Feb; 36(1): 36 - 49
13. Bunnell WP. The natural history of idiopathic scoliosis before skeletal maturity. Spine 1986 Oct; 11(8): 773 - 6
14. Little DG, Song KT, Katz D, Herring JA. Relationship of peak height velocity to other maturity indicators in idiopathic scoliosis in girls. J Bone Joint Surg Am 2000 May; 82(5):685- 93
15. Bunnell WP. The natural history of idiopathic scoliosis. Clin Orthop 1988 Apr; 229: 20 - 5
16. Suh PB, McEwen GD. Idiopathic scoliosis in males. A natural history study. Spine 1988 Oct; 13(10):1091 - 5
17. Weinstein SL, Dolan LA, Spratt KF, Peterson K, Spoonamore M. Natural History of Adolescent Idiopathic Scoliosis: Back Pain at 50-Year Follow-Up. Presented at SRS annual meeting 1998; Oct 16-20: New York, 1998.
18. Morin Doody M, Lonstein JE, Stoval M, Hacker DG, Luckyanov N, Land CE. Breast cancer mortality after diagnostic radiology: findings from the U.S. Scoliosis cohort study. Spine 2000 Aug; 25(16): 2052 - 63
19. Nash CL Jr, Gregg EC, Brown RH, Pillai K. Risks of exposure to X-rays in patients undergoing long-term treatment for scoliosis. J Bone Joint Surg Am 1979 Apr; 61(3): 371 - 4
20. Levy AR, Goldberg MS, Mayo NE, Hanley JA, Poitras B. Reducing the lifetime risk of cancer from spinal radiographs among people with

- adolescent idiopathic scoliosis. *Spine* 1996 Jul; 21(13):1540-7
21. Jackson RP, McManus AC. Radiographic analysis of sagittal plane alignment and balance in standing volunteers and patients with low back pain matched for age, sex, and size. A prospective controlled clinical study. *Spine* 1994 Jul 15; 19(14):1611-8
 22. Cheung KMC, Luk KDK. Prediction of correction of scoliosis with use of the fulcrum bending radiograph. *J Bone Joint Surg Am* 1997 Aug; 79(8):1144-50
 23. Vaughan JJ, Winter RB, Lonstein JE. Comparison of the use of supine bending and traction radiographs in the selection of the fusion area in adolescent idiopathic scoliosis. *Spine* 1996 Nov; 21(21):2469-73
 24. Evans SC, Edgar MA, Hall-Craggs MA, Powell MP, Taylor BA, Noordeen HH. MRI of "idiopathic" juvenile scoliosis. A prospective study. *J Bone Joint Surg Br* 1996 Mar; 78(2): 314-7
 25. Gupta P, Lenke LG, Bridwell KH. Incidence of neural axis abnormalities in infantile and juvenile patients with spinal deformity; Is an magnetic resonance image screening necessary? *Spine* 1998 Jan 15; 23(2):206-10
 26. Lewonowski K, King JD, Nelson MD. Routine use of magnetic resonance imaging in idiopathic scoliosis patients less than eleven years old of age. *Spine* 1992; 17(6 Suppl):109-16
 27. Maiocco B, Deeney VF, Coulon R, Parks PF Jr. Adolescent idiopathic scoliosis and the presence of spinal cord abnormalities. Preoperative magnetic resonance imaging analysis. *Spine* 1997 Nov; 22(21): 2537-41
 28. Schwend RM, Henrikus W, Hall JE, Emans JB. Childhood scoliosis : clinical indications for magnetic resonance imaging. *J Bone Joint Surg Am* 1995 Jan; 77(1):46-53
 29. Winter RB, Lonstein JE, Heithoff KB, Kirkham JA. Magnetic resonance imaging evaluation of the adolescent patient with idiopathic scoliosis before spinal instrumentation and fusion. A prospective, double-blinded study of 140 patients. *Spine* 1997 Apr; 22(8): 855-8
 30. Winter RB, Lonstein J, Denis F, Koop S. Presence of spinal canal or cord abnormalities in idiopathic, congenital and neuromuscular Scoliosis. *Orthop Trans* 1992; 16:135
 31. Klemme WR, Denis F, Winter RB, Lonstein JW, Koop SE. Spinal instrumentation without fusion for progressive scoliosis in young children. *J Pediatr Orthop* 1997 Nov-Dec; 17(6): 734-42
 32. Marchetti PG, Faldini A. End fusion in the treatment of severe progressing or severe scoliosis in childhood or early adolescence. *Orthop Trans* 1978; 2:271
 33. Roberto RF, Lonstein JE, Winter RB, Denis F. Curve progression in Risser stage 0 or I patients after posterior spine fusion for idiopathic scoliosis. *J Pediatr Orthop* 1997 Nov-Dec; 17(6): 718-25
 34. Sanders JO, Herring HA, Browne RH. Posterior arthrodesis and instrumentation in immature (Risser-grade- 0) spine in idiopathic scoliosis. *J Bone Joint Surg Am* 1995 Jan; 77(1):39-45
 35. Burton DC, Asher MA, Lai SM. Scoliosis correction maintenance in skeletally immature patients with idiopathic scoliosis. Is anterior fusion really necessary? *Spine* 2000 Jan; 25(1):61-8

36. Nash CL Jr, Moe JH. A study of vertebral rotation. *J Bone Joint Surg Am* 1969 Mar;51(2):223 - 9
37. Nagata H, Schendel MJ, Transfeldt EE, Lewis JL. The effects of immobilization of long segments of the spine on the adjacent and distal facet force and lumbosacral motion. *Spine* 1993 Dec; 18(16): 2471 - 9
38. Harrington PR. Treatment of scoliosis. Correction and internal fixation by spine instrumentation. *J Bone Joint Surg Am* 1962 Jun;44(4): 591 - 610
39. Luque ER: Segmental spinal instrumentation for correction of scoliosis. *Clin Orthop* 1982 Mar; 163:192 - 8
40. Thompson GH, Wilber RG, Shaffer JW, Scoles PV, Nash CL Jr. Segmental spinal instrumentation in idiopathic scoliosis. A preliminary report. *Spine* 1985 Sep;10(7): 623 - 30
41. Cotrel Y, Dobousset J. A new technic for segmental spinal osteosynthesis using the posterior approach. *Rev Chir Orthop Reparatrice Appar Mot* 1984; 70(6): 489 - 94
42. Dwyer AF, Newton NC, Sherwood AA. An anterior approach to Scoliosis: a preliminary report. *Clin Orthop* 1969 Jan-Feb; 62:192 - 202
43. Dwyer AF, Schafer MF. Anterior approach to scoliosis: results of treatment of fifty-one cases. *J Bone Joint Surg Br* 1974 May; 56(2): 218-24
44. Gaines RW. KASS results. Presenting at 35th SRS Annual Meeting, Cairns, Australia, October 18 - 21, 2000
45. Halm HF, Liljenqvist, Niemeyer T, Chan DP, Zielke K, Winkelmann W. Halm-Zielke instrumentation for stable anterior scoliosis surgery: operative technique and 2-year results in ten consecutive adolescent idiopathic Scoliosis patients within a prospective clinical trial. *Eur Spine J* 1998; 7(5): 429 - 34
46. Kaneda K, Shono Y, Satoh S, Abumi K. New anterior instrumentation for the management of thoracolumbar and lumbar scoliosis. Application of Kaneda two-rod system. *Spine* 1996 May; 21(10): 1250 - 62
47. Kaneda K, Shono Y, Satoh S, Abumi K. Anterior correction of thoracic scoliosis with Kaneda anterior spinal system. A preliminary report. *Spine* 1997 Jun; 22(12):1358 - 68
48. Zielke K, Stunkat R, Beaujean F. Ventrale dertations-spondylodese. *Arch Orthop Unfallchir* 1976 Apr 19; 85(3): 257 - 77
49. Kostuik JP, Carl A, Ferron S. Anterior Zielke instrumentation for spinal deformity in adults. *J Bone Joint Surg Am* 1989 Jul;71(6):898-912
50. Lowe TG, Peters JD. Anterior spinal fusion with Zielke instrumentation for idiopathic scoliosis. A frontal and sagittal curve analysis in 36 patients. *Spine* 1993 Mar;18(4): 423 - 6
51. Moskowitz A, Trommanhauser S. Surgical and clinical results of Scoliosis surgery using Zielke instrumentation. *Spine* 1993;18(16): 2444 - 51
52. Oda I, Cunningham BW, Lee GA, Abumi K, Kaneda K, McAfee PC. Biomechanical properties of anterior thoracolumbar multisegmental fixation: an analysis of construct stiffness and screw-rod strain. *Spine* 2000 Sep; 25(18): 2303 - 11

กิจกรรมการศึกษาต่อเนื่องสำหรับแพทย์

ท่านสามารถได้รับการรับรองอย่างเป็นทางการสำหรับกิจกรรมการศึกษาต่อเนื่องสำหรับแพทย์ กลุ่มที่ 3 ประเภทที่ 23 (ศึกษาด้วยตนเอง) โดยศูนย์การศึกษาต่อเนื่องของแพทย์ จุฬาลงกรณ์มหาวิทยาลัย ตามเกณฑ์ของศูนย์การศึกษาต่อเนื่องของแพทย์แห่งแพทยสภา (ศนพ.) จากการอ่านบทความเรื่อง "การรักษาโรคกระดูกสันหลังคดชนิดที่ไม่ทราบสาเหตุ (Idiopathic scoliosis) โดยวิธีการผ่าตัดในยุคปัจจุบัน" โดยตอบคำถามข้างล่างนี้ พร้อมกับส่งคำตอบที่ท่านคิดว่าถูกต้องโดยใช้แบบฟอร์มคำตอบท้ายคำถาม แล้วใส่ของพร้อมซองเปล่า (ไม่ต้องติดแสตมป์) จ่าหน้าซองถึงตัวท่าน ส่งถึง

ศ. นพ. สุทธิพร จิตต์มิตรภาพ

บรรณานิการจุฬาลงกรณ์เวชสาร

และประธานคณะกรรมการการศึกษาต่อเนื่อง

คณะแพทยศาสตร์ จุฬาลงกรณ์มหาวิทยาลัย

หน่วยจุฬาลงกรณ์เวชสาร

ตึกอบรมวิชาการ ชั้นล่าง

เขตปทุมวัน กทม. 10330

จุฬาลงกรณ์เวชสารขอสงวนสิทธิ์ที่จะส่งเฉลยคำตอบพร้อมหนังสือรับรองกิจกรรมการศึกษา ต่อเนื่องอย่างเป็นทางการ ดังกล่าวแล้วข้างต้นสำหรับท่านที่เป็นสมาชิกจุฬาลงกรณ์เวชสารเท่านั้น สำหรับ ท่านที่ยังไม่เป็นสมาชิกแต่ถ้าท่านสมัครเข้าเป็นสมาชิกจุฬาลงกรณ์เวชสารสำหรับวารสารปี 2545 (เพียง 200 บาทต่อปี) ทางจุฬาลงกรณ์เวชสารยินดีดำเนินการส่งเฉลยคำตอบจากการอ่านบทความให้ตั้งแต่วันที่ เดือนมกราคม 2545 จนถึงวันที่เดือนธันวาคม 2545 โดยสามารถส่งคำตอบได้ไม่เกินเดือนมีนาคม 2546 และจะส่งหนังสือรับรองชนิดสรุปเป็นรายปีว่าท่านสมาชิกได้เข้าร่วมกิจกรรมการศึกษาต่อเนื่องที่จัดโดย จุฬาลงกรณ์เวชสาร จำนวนกี่เครดิตในปีที่ผ่านมา โดยจะส่งให้ในเดือนเมษายน 2546

คำถาม - คำตอบ

1. The only factor which is currently proved to be the etiology of idiopathic scoliosis is ?

A. Over-weight lifting

B. Genetic

C. Obesity

D. Abnormal sitting behavior

คำตอบ สำหรับบทความเรื่อง "การรักษาโรคกระดูกสันหลังคดชนิดที่ไม่ทราบสาเหตุ (Idiopathic scoliosis) โดยวิธีการผ่าตัดในยุคปัจจุบัน"

จุฬาลงกรณ์เวชสาร ปีที่ 46 ฉบับที่ 2 เดือนกุมภาพันธ์ พ.ศ. 2545

รหัสสื่อการศึกษาต่อเนื่อง 3-15-201-2000/0202-(1004)

ชื่อ - นามสกุลผู้ขอ CME credit เลขที่ใบประกอบวิชาชีพเวชกรรม.....
ที่อยู่.....

1. (A) (B) (C) (D)

4. (A) (B) (C) (D)

2. (A) (B) (C) (D)

5. (A) (B) (C) (D)

3. (A) (B) (C) (D)

2. Considering the curve pattern, which type of curve has the highest risk of progression ?
- A. Single throacic curve
 - B. Thoraco-lumbar curve
 - C. Lumbar curve
 - D. Double throacic curve
3. What is the best test to assess the developing of scoliosis ?
- A. Push-prone test
 - B. Adam's forward bending test
 - C. Stretching test
 - D. Side bending test
4. Most of idiopathic scoliosis patients are asymptomatic, some of those are associated with intraspinal abnormalities. Which one of the following considered to be a risk factor ?
- A. Age less than 11 years old when curve first develops
 - B. Curve magnitude $> 40^{\circ}$
 - C. Left lumbar curve pattern
 - D. Symmetrical superficial abdominal reflex
5. All of the following are the indications for surgical treatment of idiopathic scoliosis except ?
- A. Curve magnitude progresses beyond 45° Cobb angle
 - B. The tilt angle increases beyond 20°
 - C. Spinal decompensation extends beyond 3 cm
 - D. Association with a congenital abnormal vertebra

สถาบันวิทยบริการ
จุฬาลงกรณ์มหาวิทยาลัย

ท่านที่ประสงค์จะได้รับเครดิตการศึกษาต่อเนื่อง (CME credit)
กรุณาส่งคำตอบพร้อมรายละเอียดของท่านตามแบบฟอร์มด้านหน้า

ศาสตราจารย์นายแพทย์สุทธิพร จิตต์มิตรภาพ
ประธานคณะกรรมการการศึกษาต่อเนื่อง
คณะแพทยศาสตร์ จุฬาลงกรณ์มหาวิทยาลัย
หน่วยจุฬาลงกรณ์เวชสาร ตึกอบรมวิชากร ชั้นล่าง
คณะแพทยศาสตร์ จุฬาลงกรณ์มหาวิทยาลัย
เขตปทุมวัน กทม. 10330