

CHAPTER I



1. BACKGROUND AND RATIONALE

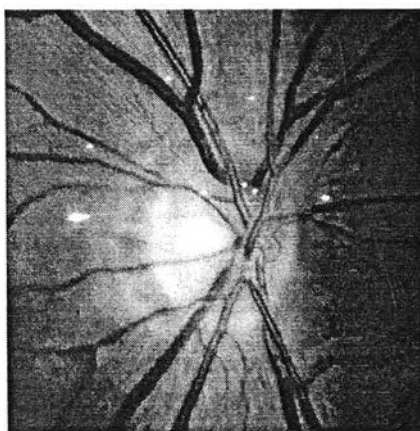
Glaucoma is a leading cause of blindness. In the U.S. about 2.25 millions American older than 45 years old were estimated to have glaucoma.¹ More than 166,000 persons were legally blind (20/200 or less) from glaucoma. Glaucoma affected about 5.2 millions people worldwide. It is the third leading cause of blindness in the world. In Thailand a recent community-based survey from Siriraj Hospital (pre-published data, personal communication) found that the prevalence of glaucoma in people older than 60 years old was about 6%. Glaucoma is also a leading cause of blindness in Thailand second only to cataract.

The standard approach for a suspected glaucoma patient is to test whether there are visual field defects. However, visual field defects may manifest later than optic nerve damage in some patients.^{2,3} So in some patients, an evaluation of optic disc topography may provide the earliest sign of damage by demonstrating structural changes of the optic nerve head before visual field loss.^{2,4}

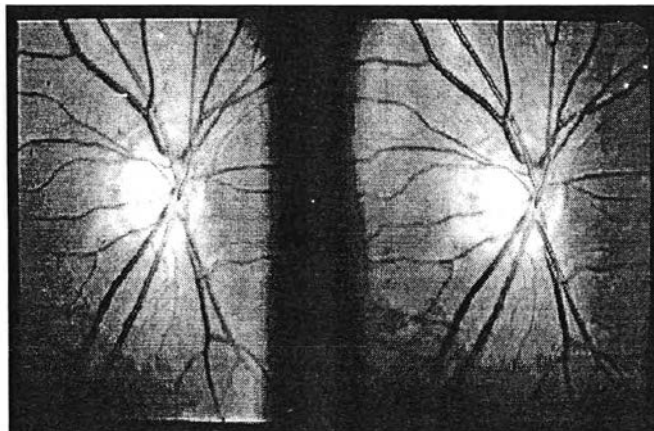
The standard instruments for optic nerve head examination include direct ophthalmoscope, slit-lamp biomicroscopy with special lenses and fundoscopy with indirect ophthalmoscope. These instruments provide the ophthalmologists with subjective impression of the two or three-dimensional structure of the optic nerve head. Documentation of the examination is usually by sketching of the subjective impression in the medical record. Alternatively, if available, monocular or stereoscopic optic disc photographs (figure 1.1) can be done for documentation and follow up. All these methods are not objective and sensitive enough to detect subtle abnormality of the early damage in glaucoma.

Figure 1.1 An example of a monocular and stereoscopic optic disc photograph.

Monocular
disc photograph



Stereoscopic disc photograph



The Heidelberg Retina Tomograph (figure 1.2) or HRT (Heidelberg Engineering GmbH, Heidelberg, Germany) is a confocal scanning laser ophthalmoscope (CSLO) system that combines confocal optics and low energy laser (670 nm) to obtain three-dimensional optical section of the optic nerve head with the aids of a computer software.⁵ The HRT provides the ophthalmologists with an objective and reproducible measurements to evaluate three-dimensional data of the optic nerve head called optic nerve topography (figure 1.3). The reproducibility of the local height measurements (individual pixel) is between 20-40 micron.⁶⁻¹⁵ The reproducibility of stereometric parameter values is also very good with the coefficient of variation between 3-12%.^{8, 15-18} The topographic optic disc parameters had been shown to correlate well with visual field indices^{6, 19-26} and had the ability to detect early glaucomatous damage.^{6, 7, 27-31} The HRT software provides many topographic optic nerve parameters e.g., disc area, cup area, cup-to-disc area ratio, rim area, cup volume, rim volume etc. These parameters can then be evaluated for abnormality by tools that provided by the software (figure 1.4).

Figure 1.2 The Heidelberg Retina Tomograph (HRT)

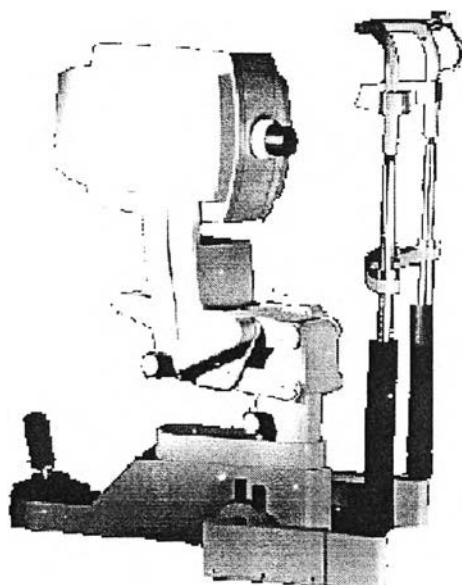


Figure 1.3 Diagram of cross-section of an optic nerve head (optic disc) showing the definitions of some of the topographic optic disc parameters.

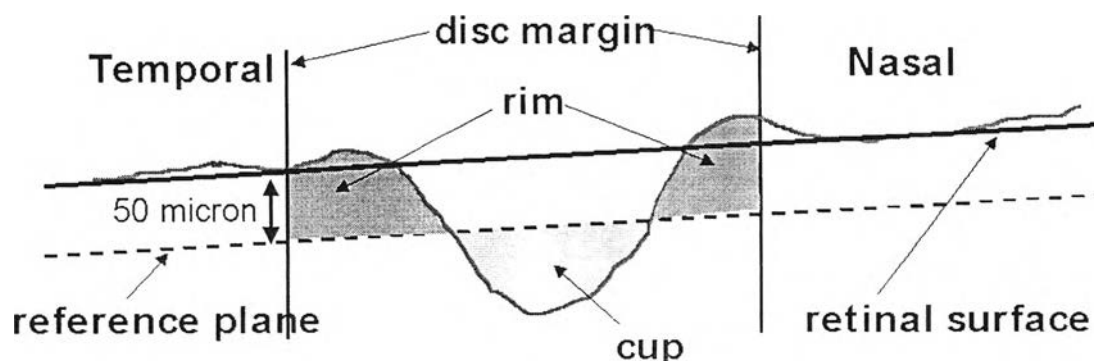
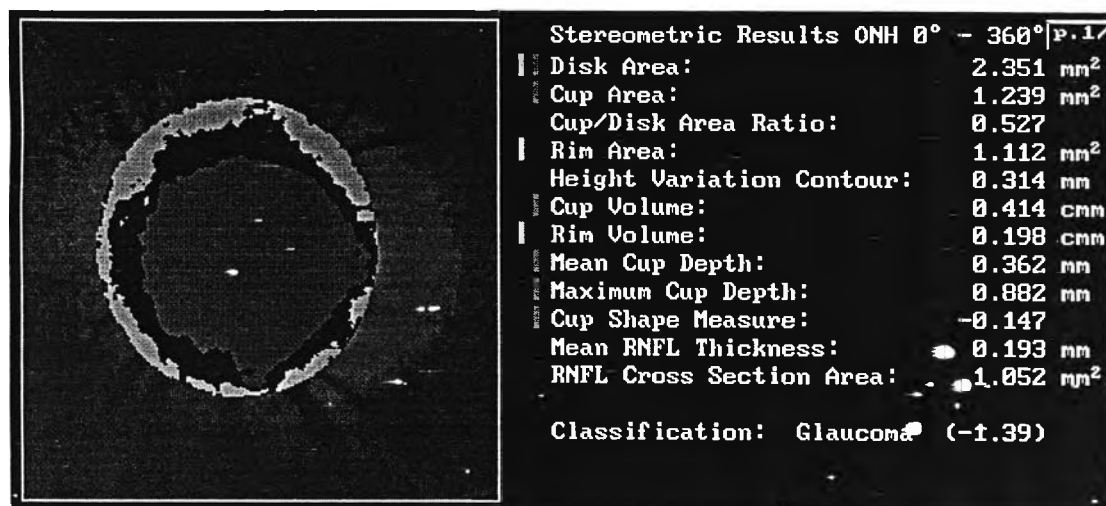


Figure 1.4 An example of a computer screen showing the topographic optic disc parameters calculated by the software of the HRT instrument.



Two such tools are discriminant functions and ranked-segment distribution curves.³² These tools can differentiate between normal and glaucomatous optic nerve based on the normative database included in the software. The present normative database in the instrument is collected from only Caucasian (Whites) healthy subjects. There are many reports demonstrated that there are ethnic differences in optic nerve head topography.^{33, 34} Using the included normative data with Thai patients may not be appropriate. Hence the need for a race-specific normative database of the Thai population is obvious and it is the main purpose of this study.

Contradictory results had been reported concerning the relationship of age and optic disc parameters. Some clinical studies have detected no age-related differences in the optic disc³⁵⁻³⁸, while other investigators have found age-related differences.³⁹⁻⁴² These were all clinic-based studies and their generalizability is unclear. The population-based studies like the Ferndale⁴³, Framingham⁴⁴, and Baltimore³⁴ eye study did not find any significant relationship between age and size of the cup or the cup-to-disc ratio. However, some histologic studies have shown an annual loss of 4,000 to 12,000 nerve fibers per year.⁴⁵⁻⁴⁸ But Repka and Quigley⁴⁹ and Johnson et al⁵⁰ found no statistically significant decrease in the number of nerve fibers with age. In summary, there are still controversies about relationships of age and optic disc parameters. This issue will also be explored in this study.

This study is aimed to establish a Thai specific and age group specific normative data of topographic optic disc parameters in normal Thai subjects. To avoid any biases that can occur, normal subjects will be recruited from a community rather than from a hospital.