

## Double-wing volar V-Y advancement flap for reconstruction of finger tip defects: Report of 23 cases.

Pravit Kitidumrongsook\* Adisorn Patradul\*

Chaitavat Ngarmukos\* Vinai Parkpain\*

Kitidumrongsook P, Patradul A, Ngarmukos C, Parkpain V. Double-wing volar V-Y advancement flap for reconstruction of finger tip defects: Report of 23 cases. Chula Med J 2002 Feb; 46(2): 131 - 6

**Objective** : *The Volar V-Y advancement flap is one of the most common local flaps used for coverage of the fingertip. Primary closure of the donor site and good sensibility are the advantages but deformed fingertip contour also commonly seen and linear scar contracture was postulated for the cause. The original design of the flap was modified to prevent this unpleasant deformity.*

**Methods** : *The surgery was performed in 23 patients with fingertip injuries requiring flap coverage and only intact pulp tissue longer than 1.5 cm (measured from volar DIP disease) was enrolled. The degree of scar contracture and fingertip deformity was observed.*

**Result** : *Although more operative time was consumed, the result was satisfactory in all cases. The wound healed at 3 weeks and no ballooning of the flap occurred at three and six months intervals following the operation.*

**Conclusion** : *Favorable cosmesis was achieved with this double wing design. This may be a way to improve the result of the Volar V-Y advancement flap, one of the most commonly used flaps.*

**Key words** : *Double-Wing, Volar V-Y advancement flap, Fingertip defect, Coverleaf deformity.*

Reprint request : Kitidumrongsook P, Department of Orthopaedics, Faculty of Medicine,  
Chulalongkorn University, Bangkok 10330, Thailand.

Received for publication. October 18, 2001.

ประวิทย์ กิตติดำรงสุข, อติศร ภัทรธาตุย์, ชายธวัช งามอุโฆษ, วินัย พากเพียร. การรักษาบาดแผลบาดเจ็บบริเวณปลายนิ้วโดยใช้ double-wing volar V-Y advancement flap: รายงานผู้ป่วย 23 ราย. จุฬาลงกรณ์เวชสาร 2545 ก.พ; 46(2): 131 - 6

- วัตถุประสงค์** : Volar V-Y advancement flap coverage เป็นการผ่าตัดซึ่งใช้บ่อยในการรักษาบาดแผลจากการบาดเจ็บบริเวณปลายนิ้ว โดยที่ข้อดีของการผ่าตัดชนิดนี้คือ เป็นการผ่าตัดครั้งเดียว (one stage) และให้การรับความรู้สึกที่ดี แต่ในบางครั้งพบว่าบริเวณแผลผ่าตัดมีการบวมบูนขึ้นของ flap ซึ่งอาจเป็นปัญหาในแง่ของความสวยงาม โดยเชื่อว่าการบวมบูนขึ้นดังกล่าวอาจเกิดจากการหดรั้งของแผลเป็นในแนวเส้นตรง ดังนั้นจึงได้ดัดแปลงรูปร่างของ flap เพื่อหวังจะลดความผิดปกติดังกล่าว
- สถานที่ทำการศึกษา** : ภาควิชาออร์โธปิดิกส์ คณะแพทยศาสตร์ จุฬาลงกรณ์มหาวิทยาลัย
- รูปแบบการวิจัย** : การวิจัยเชิงพรรณนา แบบศึกษาย้อนหลัง
- ผู้ป่วยที่ได้ทำการศึกษา** : ผู้ป่วยซึ่งมีบาดแผลจากการบาดเจ็บที่ปลายนิ้วและมีกระดูกโผล่ที่มารับการรักษาที่โรงพยาบาลจุฬาลงกรณ์ โดยคัดเลือกเฉพาะผู้ป่วยที่มีผิวหนังด้านฝ่ามือบริเวณปลายนิ้วที่ยังเหลืออยู่มากกว่า 1.5 ซม. วัดจาก DIP crease จำนวน 23 ราย
- วิธีการศึกษา-วัดผล** : ตรวจบาดแผลจากการผ่าตัดเป็นระยะ ๆ เพื่อดูการเกิดการบวมบูนขึ้นของ flap
- ผลการศึกษา** : พบว่าการผ่าตัดวิธีนี้ให้ผลน่าพอใจในแง่ของความสวยงามของบาดแผล โดยไม่พบการบวมบูนขึ้นของ flap จากการตรวจติดตามผลการรักษาที่ระยะเวลา 3 เดือน และ 6 เดือน
- วิจารณ์และสรุป** : จากผลการศึกษาเมื่อพิจารณาถึงความสวยงามของบาดแผลในระยะยาววิธีนี้จะให้ผลการรักษาที่ดีกว่าแบบดั้งเดิม ข้อเสียคือ การผ่าตัดยากขึ้น และใช้เวลานานขึ้น
- คำสำคัญ** : บาดแผลบาดเจ็บบริเวณปลายนิ้ว, Double-wing, Volar V-Y advancement flap, การบวมบูนขึ้นของ flap

The Volar V-Y advancement flap is a widely accepted method for coverage of the fingertip defect (E. Tranquilli Leali 1935,<sup>(1)</sup> Atasoy et al in 1970<sup>(2)</sup>) since it is a simple, one-stage procedure that provides good cosmesis and sensibility.<sup>(3,4)</sup> Complications such as flap necrosis, inadequate mobilization of the flap and hook nail deformity<sup>(1,3,4-6)</sup> were well recognized but late deformed fingertip contour (according to LC Teoh) was seldomly noted. This so-called coverleaf deformity was

ballooning of the flap from the contracted surrounding tissue (Figure 1 and Figure 2) possibly caused by linear scar contracture. Though this is only cosmetic concerning without functional impairment, prevention is desirable. Conventional design of the flap again was modified by LC Teoh who added two wings, one for each limb and his early report was encouraging and also supported by our report.<sup>(7)</sup>

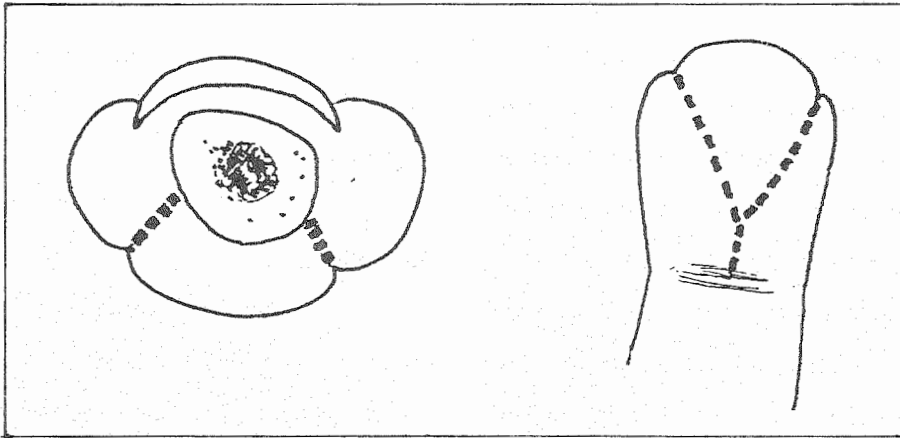


Figure 1. Diagram of coverleaf deformity

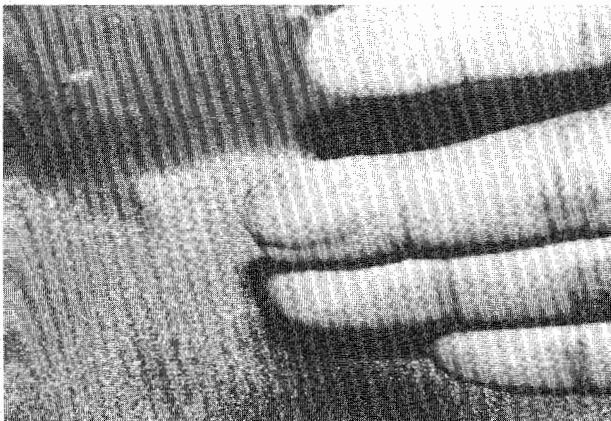
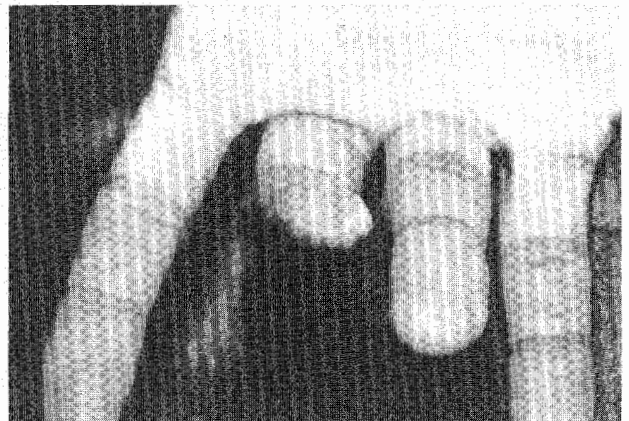

Figure 2. A. Coverleaf deformity - AP view



B. Coverleaf deformity - Cross section

## Materials and Methods

Generally accepted indications for the Volar V-Y advancement flap coverage was fingertip defect whereby the bone was exposed and adequate volar tissue was left. We followed LC Teoh's guideline that the volar pulp skin should be left by more than 1.5 cm (measured from volar distal interphalangeal (DIP) crease) together with an adequate nailbed of 0.5 cm measured from the eponychial fold. Twenty-three patients with twenty-three injured digits were included, started from January 1998 till January 2001. The injured digits were ten middle fingers, seven index, three thumbs, two ring fingers and one little finger. In all patients the procedure was carried out by either digital block or wrist block with finger tourniquet. Figure 3 shows the double-wing design compared to the conventional design in figure 1.


Two cases of acute nailbed grafting were performed simultaneously, one harvested from the preserved amputated part, the other from the injured digit (split nailbed graft).

## Results

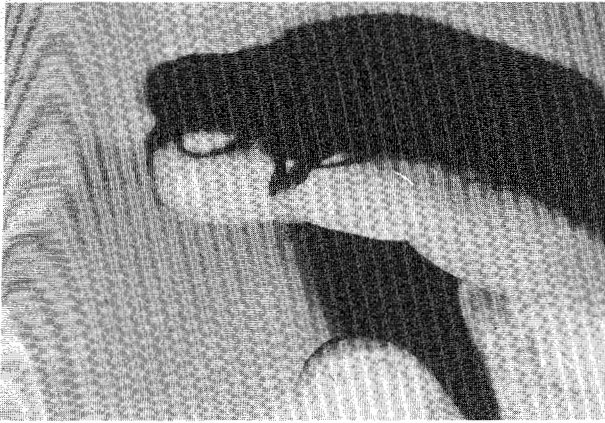
The procedure was successfully performed in all cases, mean operating time was forty three minutes (eight minutes more than the conventional design according to the first author). In all patients, the wound healed at about three weeks without flap necrosis except the two cases of which acute nailbed grafting was performed which delayed the healing of the nail to about six weeks. After three weeks all patients were followed to detect the coverleaf deformity which was still not occurring at three months. At six months only fifteen from twenty three patients could be followed and still showed no coverleaf deformity. No limitation of the DIP joint of the injured digit was noted.

## Example of the case

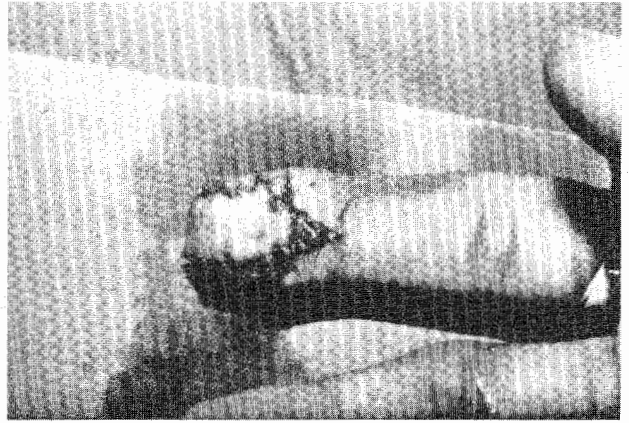
A twenty five year-old male who injured his right index in a plastic pumping machine. The injury is shown in figure 4. Immediate postoperative pictures were shown in figures 5,6. Figures 7,8 and 9 showed the result at six months.



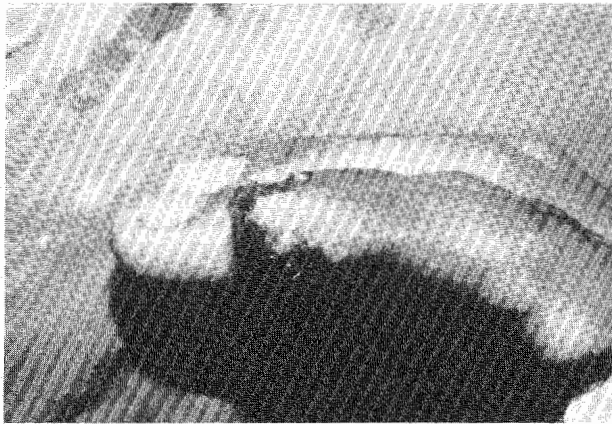
**Figure 3.** Diagram of the double-wing design compared to conventional design in Figure 1.



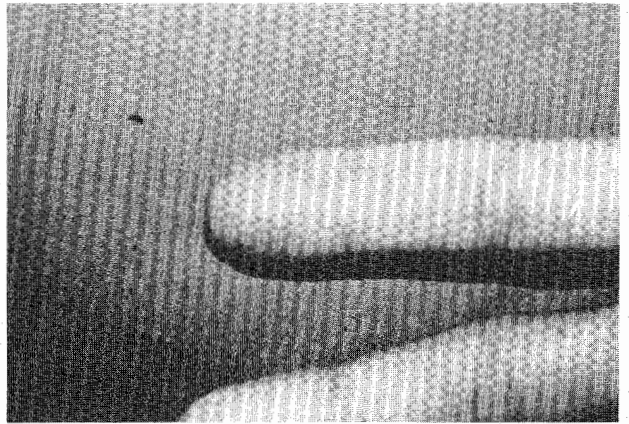
**Figure 4.** Preoperative photograph.




**Figure 5.** Immediate postoperative photograph-AP view.



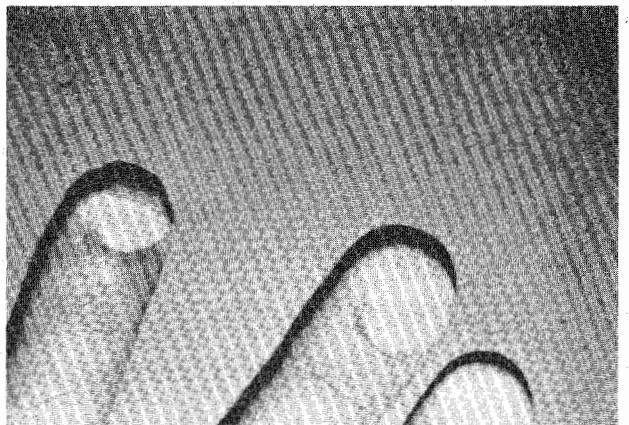
**Figure 6.** Lateral view.



**Figure 7.** AP view photograph at 6 months.



**Figure 8.** Lateral view.



**Figure 9.** Nail growth

## Discussion

As mentioned, the Volar V-Y advancement flap was popularized for a long time and is still not out of date. Patients should be properly selected and this method of reconstruction can only be applied if adequate tissue is left.<sup>(1,2)</sup> Lack of definite criteria may still be problematic but it may be useful to follow the guideline in this study as we found no problems such as; inadequate mobilization, fingertip hypersensitivity<sup>(4)</sup> and flap necrosis. With regard to the coverleaf deformity, it is very difficult to study the incidents in our country because most of the patients are workers that will never give permission for a long term follow up which is necessary for this type of cosmetic problem. Nevertheless, better results were achieved in our study whereby the selected patients followed the guidelines for the double wing design. No ballooning and deformed fingertip occurred even after six month. One of the disadvantages may be that procedure is more time consuming in the process of raising and suturing of the flap and it may be very difficult or impossible in children whose fingers are very small. Closure of the vertical limb of the Y, sometimes caused problems and could be left to heal by secondary healing or by performing split skin grafting.

In the end we supported that this modification "the double wing Volar V-Y advancement flap", though it is more difficult, is worth performing.

## Acknowledgement

We would like to express our gratefulness to Dr. LC Teoh Head of the Hand Surgery Department, Singapore General Hospital for his permission to present his case of the coverleaf deformity and his academic reasoning which supports the chosen method. (Figure 2A and B).

## References

1. Lister GD. V-Y advancement flaps. In: Foucher G ed. Fingertip and Nailbed Injuries. The Hand and Upper Limb. Vol 7. New York: Churchill Livingstone, 1991: 52 - 61
2. Atasoy E, Ioakimidis E, Kasdan ML, Kutz JE, Kleinert HE. Reconstruction of the amputated finger tip with a triangular volar flap. A new surgical procedure. J Bone Joint Surg Am 1970 Jul; 52A(5): 921 - 6
3. Tupper J, Miller G. Sensitivity following volar V-Y plasty for fingertip amputations. J Hand Surg [Br] 1985 Jun; 10(2): 183 - 4
4. Frandsen PA. V-Y plasty as treatment of finger tip amputations. Acta Orthop Scand 1978 Jun; 49(3): 255 - 9
5. Weston PA, Wallace WA. The use of locally based triangular skin flaps for the repair of finger tip injuries. 1976 Feb; 8(1): 54 - 8
6. Foucher G, Citron N. Therapeutic approach in fingertip injuries. In: Evans DM ed. Skin Cover in the Injured Hand. The Hand and Upper Limb. Vol.9 New York: Churchill Livingstone, 1992: 181 - 91
7. Kitidumrongsook P, Patradul A, Ngramukos C, Parkpian V. The double-wing volar V-Y advancement flap for reconstruction of fingertip defects. Report of 5 cases. Presented at the Combined Meeting of the 14<sup>th</sup> Annual Meeting of the Thai Society for Surgery of the Hand, 9<sup>th</sup> Annual Meeting of the Thai society for Reconstructive Microsurgery, and 1<sup>st</sup> Regional Education Program of the Asian Pacific Federation of Societies for surgery of the Hand at Royal Golden Jubilee Building, Bangkok. Thailand 2 April 1998.