

Outcome of percutaneous balloon pulmonary valvuloplasty in children at King Chulalongkorn Memorial Hospital

Sunthorn Muangmingsuk*

Pornthep Lertsapcharoen* Apichai Khongphatthanayothin*

Pairoj Chotivittayatarakorn* Vichai Benjacholamas**

Muangmingsuk S, Lertsapcharoen P, Khongphatthanayothin A, Chotivittayatarakorn P, Benjacholamas V. Outcome of percutaneous balloon pulmonary valvuloplasty in children at King Chulalongkorn Memorial Hospital. Chula Med J 2002 Jun; 46(6): 489 - 94.

Objective : *To review short-term outcome of percutaneous balloon pulmonary valvuloplasty (PBPV) in moderate or severe pulmonary valve stenosis (PS) in children.*

Research design : *Retrospective descriptive study*

Materials and Methods : *During Jan 95 to May 01, PBPV was successfully performed in 49 of 51 children of moderate or severe PS. There were 23 females and 26 males. Mean age of the patients was 5.3 ± 5.1 years (range 1 day to 16 years). Eleven patients were under one year old. Mean body weight was 17.8 ± 12.4 kg (range 2.4 - 45 kilograms).*

Results : *Following PBPV, the peak systolic gradient across the pulmonary valve decreased from 86 ± 36 to 32 ± 12 mmHg ($p < 0.001$) and peak systolic right ventricular pressure decreased from 101 ± 36 to 53 ± 20 mmHg ($p < 0.001$). Only one patient required surgical valvotomy afterward. Complications were systemic embolism causing right hemiparesis, bleeding from the puncture site and two cases of supraventricular tachycardia.*

* Department of Pediatrics, Faculty of Medicine, Chulalongkorn University

** Department of Surgery, Faculty of Medicine, Chulalongkorn University

Conclusion : *PBPV is the treatment of choice in management of pulmonary valve stenosis. It produces excellent short-term results.*

Key words : *Percutaneous balloon pulmonary valvuloplasty, Outcome, Children.*

Reprint request: Muangmingsuk S, Department of Pediatrics, Faculty of Medicine,
Chulalongkorn University, Bangkok 10330, Thailand.

Received for publication. March 12, 2002.

สถาบันวิทยบริการ
จุฬาลงกรณ์มหาวิทยาลัย

สุนทร ม่วงมิ่งสุข, พรเทพ เลิศทรัพย์เจริญ, อภิชัย คงพัฒน์โยธิน, ไพโรจน์ โชติวิทย์ธรากร, วิชัย เบญจชลมาศ. ผลการรักษาโรคลิ้นหัวใจ pulmonary ตีบในเด็กโดยการใช้ลูกโป่งในโรงพยาบาลจุฬาลงกรณ์. จุฬาลงกรณ์เวชสาร 2545 มิ.ย; 46(6): 489 - 94

วัตถุประสงค์ : เพื่อศึกษาผลการรักษาโรคลิ้นหัวใจ pulmonary ตีบในเด็กโดยการใช้ลูกโป่งในโรงพยาบาลจุฬาลงกรณ์

รูปแบบการวิจัย : ศึกษาย้อนหลัง

วัสดุและวิธีการ : ระหว่างเดือน มกราคม 2538 ถึง พฤษภาคม 2544 ได้มีการใช้ลูกโป่งขยายลิ้นหัวใจ pulmonary ในเด็ก ได้สำเร็จจำนวน 49 รายจาก 51 ราย เป็นชาย 2 ราย หญิง 23 ราย อายุเฉลี่ย 5.3 ± 5.1 ปี (1 วัน - 16 ปี) เป็นเด็กที่อายุน้อยกว่า 1 ปี 11 คน น้ำหนักตัวเฉลี่ย 17.8 ± 12.4 กิโลกรัม (2.4 - 45 กิโลกรัม)

ผลการศึกษา : หลังจากการใช้ลูกโป่งขยายลิ้นหัวใจ พบว่าค่าความแตกต่างของความดัน systolic ระหว่างหลอดเลือด pulmonary กับหัวใจห้องล่างขวาลดลงอย่างมีนัยสำคัญ จาก 86 ± 36 เป็น 32 ± 12 มิลลิเมตรปรอท และค่าความดัน systolic ในหัวใจห้องล่างขวาลดลงจาก 101 ± 36 เป็น 53 ± 20 มิลลิเมตรปรอท มีผู้ป่วยที่เกิดภาวะแทรกซ้อนแขนขาข้างขวาอ่อนแรง 1 ราย มีเลือดออกจากตำแหน่งที่สอดสายสวนหัวใจ 1 ราย และอีก 2 รายมีหัวใจเต้นเร็วผิดปกติอยู่ชั่วคราว ผู้ป่วยอยู่โรงพยาบาลหลังจากการทำเฉลี่ย 2.7 ± 3.2 วัน (1 วัน - 15 วัน)

สรุป : การใช้ลูกโป่งขยายลิ้นหัวใจ pulmonary เป็นวิธีการที่ดีมาก สามารถใช้ทดแทนการผ่าตัดหัวใจได้

The prevalence of isolated pulmonary valve stenosis with intact ventricular septum (PS) is 7-12 % of congenital cardiac defects.⁽¹⁾ A patient who has estimated transvalvular gradient ≥ 50 mmHg or right ventricular hypertrophy should have cardiac catheterization with anticipated balloon valvuloplasty.⁽²⁾ The first percutaneous balloon pulmonary valvuloplasty (PBPV) in a pediatric patient was reported in 1982.⁽³⁾ This was the beginning of an explosion of reports of success using this new technique in the treatment of children and adults with congenital heart defects. Professor Viroj Sueblinvong started performing this procedure at King Chulalongkorn Memorial Hospital in 1985. The Cardiac Center of H.M. Queen Sirikit Building opened in 1995 and there is a new biplane cardiac catheterization laboratory for pediatric patients leading to the beginning of performing more interventional cardiac procedures in King Chulalongkorn Memorial Hospital. This study is to report our short-term experience of PBPV in children.

Materials and Methods

During January 1995 to May 2001, PBPV was attempted in 51 cases of moderate or severe PS

(transvalvular gradient ≥ 50 mmHg). The procedures were unsuccessful in 2 patients due to the difficulty of inserting a guidewire across the stenotic pulmonary valve. The remaining 49 patients were 23 females and 26 males. They were between the ages of 1 day to 16 years with average age of 5.3 ± 5.1 years (median age of 2.8 years). Body weight was between 2.4 – 45 kilograms with average of 17.8 ± 12.4 kg. The diagnosis of PS was made by history, physical examination and confirmed by echocardiography, which can calculate the peak systolic gradient across the pulmonary valve.

PBPV technique

Measurement of the pulmonary valve annulus was done in the cardiac catheterization laboratory mostly using a lateral view of right ventriculogram. After an exchange guidewire is placed through the catheter preferentially into the left pulmonary artery, an oversize balloon catheter with a balloon diameter ratio of 1.0 to 1.5 of pulmonary valve annulus is advanced over the exchange guidewire, with care taken that the wire remains in the distal left pulmonary artery. After the balloon catheter is positioned where

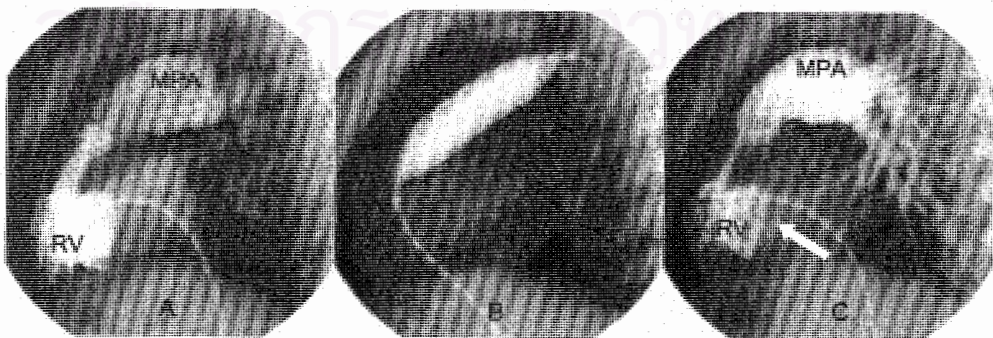

Figure 1. Lateral view of right ventricular (RV) cineangiogram before (A), during (B) and after PBPV (C). Note jet flow across the stenotic pulmonary valve that disappeared after PBPV. Note infundibular narrowing after PBPV (white arrow).

the midportion of the balloon coincides with the stenotic area, the balloon is inflated rapidly under fluoroscopy until the hourglass waist from the stenotic valve disappears or until the maximum recommended atmospheric pressure is reached as shown in Figure 1. Rapid deflation is performed. Inflation can be repeated with repositioning of the balloon catheter as needed. After PBPV, the gradient measurement was repeated and right ventriculogram is finally performed. If the pulmonary valve annulus is too large to dilate with a single balloon, simultaneous inflation of two balloons is performed.⁽⁴⁾ The continuous data are presented as mean \pm SD or median. The pulmonary valve gradient and RV peak systolic pressure were compared both before and after PBPV using the Student t-test P value < 0.05 is statistically significant.

Results

There were 20 patients who had severe PS (gradient ≥ 80 mmHg) and 29 patients of moderate PS. Following PBPV, the peak systolic gradient across the pulmonary valve decreased from 86 ± 36 (range

50 – 198) to 32 ± 12 (range 0 -115) mmHg ($p < 0.001$) and peak systolic right ventricular pressure decreased from 101 ± 36 (range 55 – 218) to 53 ± 20 (range 31 – 140) mmHg as shown in Figure 2. The average pulmonary valve diameter (PV) was 14.2 ± 5.1 (range 4 -24 mm) and average balloon size/PV was 1.3 ± 0.1 (range 1.0 -1.5). Double balloon technique was used in 5 patients. There were 5 patients who had post-balloon gradient of ≥ 50 mmHg. PBPV was repeated successfully in one patient in another occasion. One patient who had a post PBPV gradient of 115 and RV systolic pressure of 140 had a surgical pulmonary valvotomy in the newborn period. Follow up echocardiography within one year showed that the remaining 3 patients had decreased gradient from 70, 66, 52 to 30, 32 and 28 respectively.

Most of the patients were discharged within 24 – 48 hours (range 1 day to 15 days, average 2.7 ± 3.2 days) after the procedure. One of the complications was right hemiparesis in one patient due to systemic embolism to the left middle cerebral artery; this patient recovered completely by the 3 years follow-up. There was bleeding from the puncture site require blood transfusion in one patient. Two patients had supraventricular tachycardia converted with adenosine. Echocardiogram after PBPV showed no patient had more than mild pulmonary insufficiency.

Discussion

PBPV is the treatment of choice in the management of pulmonary valve stenosis. It is a less invasive compared to a surgical valvotomy under cardiopulmonary bypass. The procedure is simple and can be done even in the newborn period. The result of PBPV is comparable with surgery.⁽⁵⁾

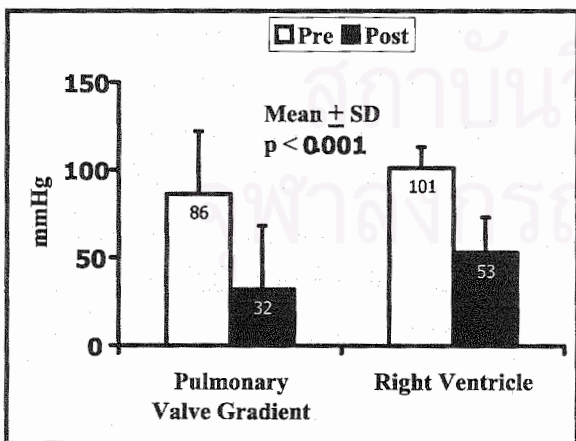


Figure 2. Compare Pre-balloon (Open column) with Post-balloon (solid column) of peak systolic gradient of pulmonary valve and systolic pressure of right ventricle. (RV).

After PBPV, most of the patients would have only a mild PS like our patients. The hospital stay is short which would save money, patient can go home within 1-2 days after the procedure. Some patients may still have a significant PS gradient due to infundibular stenosis after PBPV. Our study showed that gradient can decrease later when infundibular stenosis in regression as shown in previous study.⁽⁶⁾ The 2 unsuccessful cases due to guidewire insertion failure were at the beginning of the learning curve. After that we performed, successfully, 11 consecutive cases that were less than one year old. The complications are few, using the low profile balloon or using the double balloon technique can prevent bleeding from the puncture site. Most of the right heart balloon dilations do not require heparinization. If there is evidence for intracardiac right to left shunting especially in PS with desaturation; heparinization is advisable to prevent systemic embolism. Some institutions may routinely use heparin for PBPV.⁽¹⁾

Conclusion

Percutaneous balloon pulmonary valvuloplasty is the treatment of choice for pulmonary valve stenosis in all age groups. Both immediate and intermediate-term follow-up results have been well documented.

References

1. Chetham JP. Pulmonary stenosis. In: Garson A, Bricker JT, Fisher DJ, Neish SR, eds. The Science and Practice of Pediatric Cardiology. 2nd ed. Maryland: Williams & Wilkins, 1998: 1207 - 56
2. Hayes CJ, Jaywe CJ, Gersony WM, Driscoll DJ, Keane JF, Kidd L, O'Fallon M, Pieroni DR, Wolfe RR, Weidman WH. Second natural history study of congenital heart defects: results of treatment of patients with pulmonary valvar stenosis. *Circulation* 1993 Feb; 87 (2 Suppl I): 128 - 37
3. Kan JS, White RI Jr, Mitchell SE, Gardner TJ. Percutaneous balloon valvuloplasty: a new method for treating congenital pulmonary-valve stenosis. *N Engl J Med* 1982 Aug 26; 307(9): 540 - 2
4. Ali Khan MA, Yousef SA, Mullins CE. Percutaneous transluminal balloon pulmonary valvuloplasty for the relief of pulmonary valve stenosis with special reference to double-balloon technique. *Am Heart J* 1986 Jul; 112(1): 158 - 60
5. O'Connor BK, Beekman RH, Lindauer A, Rocchini A. Intermediate-term outcome after pulmonary balloon valvuloplasty: comparison with a matched surgical control group. *J Am Coll Cardiol* 1992 Jul; 20(1): 169 - 73
6. Thapar MK, Rao PS. Significance of infundibular obstruction following balloon valvuloplasty for valvar pulmonic stenosis. *Am Hear J* 1989 Jul; 118(1): 99 -103