



CHAPTER 3

RESEARCH QUESTIONS AND OBJECTIVES

3.1 RESEARCH QUESTIONS

Were the diagnostic properties of simplified stress knee radiography accurate (sensitivity 90%) for diagnosis of torn anterior cruciate ligament in Thai?

3.2 RESEARCH OBJECTIVES

To determine the diagnostic value of the simplified stress radiography in diagnosis of torn anterior cruciate ligaments by studying the sensitivity, specificity, likelihood ratio, accuracy, and the positive and negative predictive value.

3.3 CONCEPTUAL FRAMEWORK

Knee laxities are different in different persons. A knee with torn ACL has anterior laxity more than an intact one. When compare to the contralateral normal knee with a 20 lb. anterior displacement force are applied at both knees, most of the cases, the difference of anterior laxity are more than 3 mm. Stress radiography is one of techniques to quantify a tibial displacement in relation to femur and indicates a status of ACL.

Simplified technique of stress radiography was developed. When clinicians apply this device to torn ACL patients, abnormal anterior laxity of knees were detected and documented. We expected that simplified stress knee radiography was sensitive enough to detect a complete torn ACL.

Factors that might interfere with this stress radiography to indicate anterior displacement of tibia in relate to femur are hamstring muscle contraction or poor identification of measured points. All these factors need to be closed monitor.

3.4 HYPOTHESIS

ACL provides 95% of anterior restraint to the knee. Knees with torn ACL will lose anterior stability and the abnormal anterior displacement can be demonstrated if there is the anterior force applied to that injured knee. According to physiologic laxity in normal knee, we can slightly displace tibia anteriorly. However, when comparing left side to right one, the difference of anterior displacement distance is less than 3 mm in 95% of bilateral normal knees (8, 31). The lateral radiography of both knees with enough anterior force can document the anterior displacement distance and the difference between left and right side can be measured. The side to side difference of more than 3 mm can be detected and assume that ACL of the knee with a longer anterior displacement is torn.

3.5 ASSUMPTIONS

None

3.6 KEYS WORDS

Stress radiography, anterior cruciate ligament, diagnosis

3.7 OPERATIONAL DEFINITION

Knee injuries

Knee injuries are soft tissue injuries of knee joints.

Knee arthrometry (Figure 3)

Knee arthrometry is a quantitative measurement of a knee joint laxity. KT-1000 (MED metric, San Diego, California) was used as a knee ligament arthrometer. In this study, only anterior laxity of a knee joint was measured.

The arthrometer attaches securely to the anterior leg with two Velcro straps. The arthrometer detects motion between two sensor pads, one in contact with the patella and the other in contact with the tibial tubercle. With a force-sensing handle, the examiner applies anterior and posterior displacement loads. The arthrometer emits an audible

“beep” when a 15 lb. and a 20 lb. force is applied through the force handle. A dial at the top of the arthrometer indicates tibial-femoral displacement to the nearest 0.5 mm. Two support platforms are necessary for the examination, a thigh support platform for positioning both knees of the subject in 20 to 30 degrees of flexion and a foot support platform for maintaining both feet 15 degrees from midline with hips in external rotation.

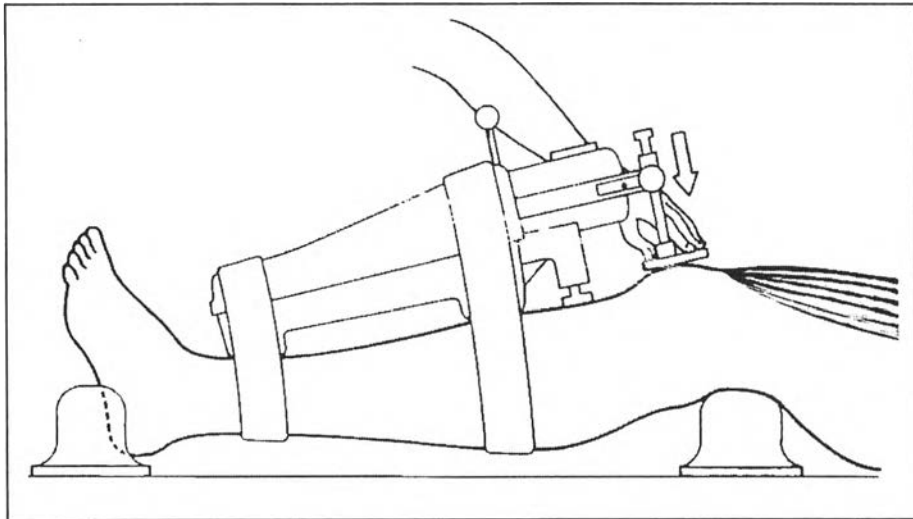


Figure 3 KT-1000 knee arthrometer

Simplified stress radiography of a knee

Radiography that applied anterior force to proximal tibia by a modified simple device as described before. (page 3-4 ,Figure 2)

Positive result of the stress radiograph

Anterior displacement of a tibia in relation to a femur was measured in a stress radiograph as describe later. A difference in the anterior displacement between both knees was calculated. The difference more than 3 mm was considered as positive finding or torn ACL.

Torn ACL (surgical finding)

All subjects underwent arthroscopic knee surgery. All surgical findings were detected by arthroscope. ACL conditions were assessed by inspection and palpation with a probe. Discontinuity of ACL or detachments of ACL from proximal or distal insertion were considered as torn ACL.